

# **Anatomy at a Glance**

*Omar Faiz*  
*David Moffat*

**Blackwell Science**

# Anatomy at a Glance

OMAR FAIZ

BSc (Hons), FRCS (Eng)  
Specialist Registrar in General Surgery

DAVID MOFFAT

VRD, MD, FRCS  
Emeritus Professor of Anatomy  
University of Cardiff



**Blackwell**  
Science

© 2002 by Blackwell Science Ltd  
a Blackwell Publishing company  
Editorial Offices:  
Osney Mead, Oxford OX2 0EL, UK  
Tel: +44 (0)1865 206206  
Blackwell Science, Inc., 350 Main Street, Malden, MA 02148-5018, USA  
Tel: +1 781 388 8250  
Blackwell Science Asia Pty, 54 University Street, Carlton, Victoria 3053, Australia  
Tel: +61 (0)3 9347 0300  
Blackwell Wissenschafts Verlag, Kurfürstendamm 57, 10707 Berlin, Germany  
Tel: +49 (0)30 32 79 060

The right of the Authors to be identified as the Authors of this Work has been asserted in accordance with the Copyright, Designs and Patents Act 1988.

All rights reserved. No part of this publication may be reproduced, stored in a retrieval system, or transmitted, in any form or by any means, electronic, mechanical, photocopying, recording or otherwise, except as permitted by the UK Copyright, Designs and Patents Act 1988, without the prior permission of the publisher.

First published 2002 by Blackwell Science Ltd  
Reprinted 2002

Library of Congress Cataloging-in-Publication Data  
Faiz, Omar.

Anatomy at a glance / Omar Faiz, David Moffat  
p. cm.

Includes index.

ISBN 0-632-05934-6 (pbk.)

1. Human anatomy—Outlines, syllabi, etc. I. Moffat, David, MD. II. Title.

[DNLM: 1: Anatomy. QS 4 F175a 2002]

QM31 .F33 2002

611—dc21

2001052646

ISBN 0-632-05934-6

A Catalogue record for this title is available from the British Library.

Set in 9/11½ pt Times by Graphicraft Limited, Hong Kong  
Printed and bound in Italy by G. Canale & C. SpA, Turin

For further information on  
Blackwell Science, visit our website:  
[www.blackwell-science.com](http://www.blackwell-science.com)

# Contents

Preface, 5

## **The thorax**

- 1 The thoracic wall I, 6
- 2 The thoracic wall II, 8
- 3 The mediastinum I—the contents of the mediastinum, 10
- 4 The mediastinum II—the vessels of the thorax, 12
- 5 The pleura and airways, 14
- 6 The lungs, 16
- 7 The heart I, 18
- 8 The heart II, 22
- 9 The nerves of the thorax, 24
- 10 Surface anatomy of the thorax, 26

## **The abdomen and pelvis**

- 11 The abdominal wall, 28
- 12 The arteries of the abdomen, 31
- 13 The veins and lymphatics of the abdomen, 34
- 14 The peritoneum, 36
- 15 The upper gastrointestinal tract I, 38
- 16 The upper gastrointestinal tract II, 40
- 17 The lower gastrointestinal tract, 42
- 18 The liver, gall-bladder and biliary tree, 44
- 19 The pancreas and spleen, 46
- 20 The posterior abdominal wall, 48
- 21 The nerves of the abdomen, 50
- 22 Surface anatomy of the abdomen, 52
- 23 The pelvis I—the bony and ligamentous pelvis, 54
- 24 The pelvis II—the contents of the pelvis, 56
- 25 The perineum, 58
- 26 The pelvic viscera, 60

## **The upper limb**

- 27 The osteology of the upper limb, 62
- 28 Arteries of the upper limb, 66
- 29 The venous and lymphatic drainage of the upper limb and the breast, 68
- 30 Nerves of the upper limb I, 70
- 31 Nerves of the upper limb II, 72
- 32 The pectoral and scapular regions, 74
- 33 The axilla, 76
- 34 The shoulder (gleno-humeral) joint, 78
- 35 The arm, 80
- 36 The elbow joint and cubital fossa, 82
- 37 The forearm, 84
- 38 The carpal tunnel and joints of the wrist and hand, 86

- 39 The hand, 88
- 40 Surface anatomy of the upper limb, 90

## **The lower limb**

- 41 The osteology of the lower limb, 92
- 42 The arteries of the lower limb, 94
- 43 The veins and lymphatics of the lower limb, 96
- 44 The nerves of the lower limb I, 98
- 45 The nerves of the lower limb II, 100
- 46 The hip joint and gluteal region, 102
- 47 The thigh, 106
- 48 The knee joint and popliteal fossa, 109
- 49 The leg, 112
- 50 The ankle and foot I, 114
- 51 The ankle and foot II, 116
- 52 Surface anatomy of the lower limb, 118

## **The autonomic nervous system**

- 53 The autonomic nervous system, 120

## **The head and neck**

- 54 The skull I, 122
- 55 The skull II, 124
- 56 Spinal nerves and cranial nerves I–IV, 126
- 57 The trigeminal nerve (V), 128
- 58 Cranial nerves VI–XII, 130
- 59 The arteries I, 132
- 60 The arteries II and the veins, 134
- 61 Anterior and posterior triangles, 136
- 62 The pharynx and larynx, 138
- 63 The root of the neck, 140
- 64 The oesophagus and trachea and the thyroid gland, 142
- 65 The upper part of the neck and the submandibular region, 144
- 66 The mouth, palate and nose, 146
- 67 The face and scalp, 148
- 68 The cranial cavity, 152
- 69 The orbit and eyeball, 154
- 70 The ear, and lymphatics and surface anatomy of the head and neck, 156

## **The spine and spinal cord**

- 71 The spine, 158
- 72 The spinal cord, 160

Muscle index, 162

Index, 168



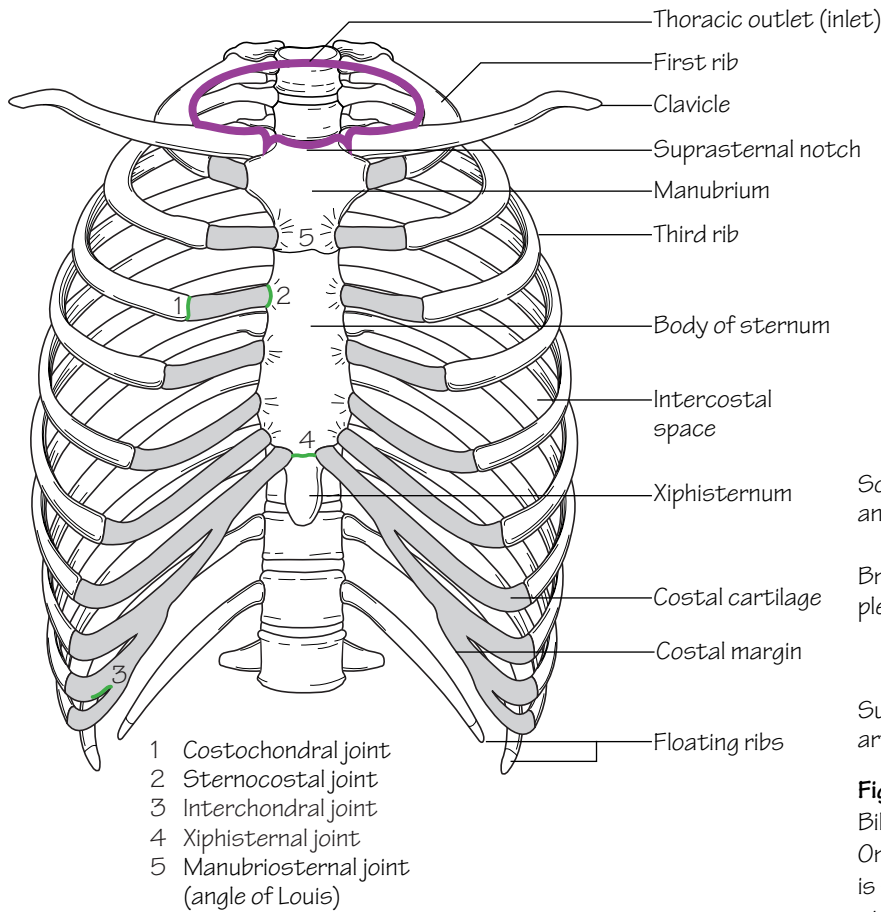
# Preface

The study of anatomy has changed enormously in the last few decades. No longer do medical students have to spend long hours in the dissecting room searching fruitlessly for the otic ganglion or tracing the small arteries that form the anastomosis round the elbow joint. They now need to know only the basic essentials of anatomy with particular emphasis on their clinical relevance and this is a change that is long overdue. However, students still have examinations to pass and in this book the authors, a surgeon and an anatomist, have tried to provide a means of rapid revision without any frills. To this end, the book follows the standard format of the *at a Glance* series and is arranged in short, easily digested chapters, written largely in note form, with the appropriate illustrations on the facing page. Where necessary, clinical applications are included in italics and there are a number of clinical illustrations. We thus hope that this book will be helpful in revising and consolidating the knowledge that has been gained from the dissecting room and from more detailed and explanatory textbooks.

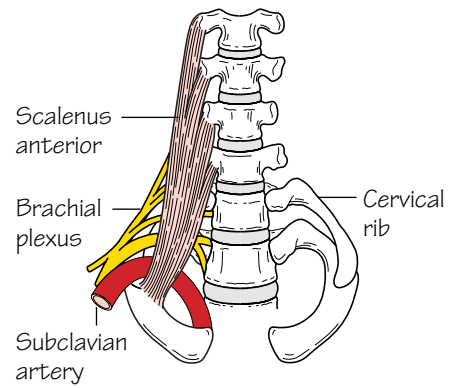
The anatomical drawings are the work of Jane Fallows, with help from Roger Hulley, who has transformed our rough sketches into the finished pages of illustrations that form such an important part of the book and we should like to thank her for her patience and skill in carrying out this onerous task. Some of the drawings have been borrowed or adapted from Professor Harold Ellis's superb book *Clinical Anatomy* (9th edn) and we are most grateful to him for his permission to do this. We should also like to thank Dr Mike Benjamin of Cardiff University for the surface anatomy photographs. Finally, it is a pleasure to thank all the staff at Blackwell Science who have had a hand in the preparation of this book, particularly Fiona Goodgame and Jonathan Rowley.

Omar Faiz  
David Moffat

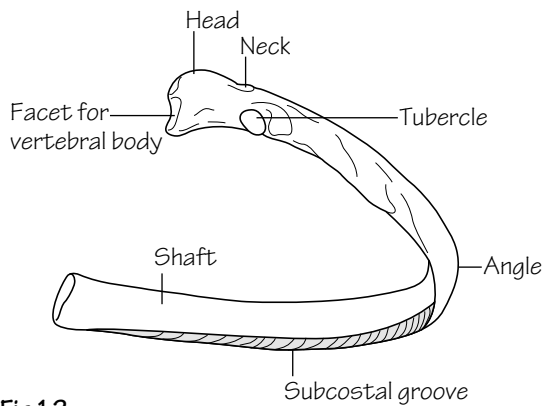
# 1 The thoracic wall I



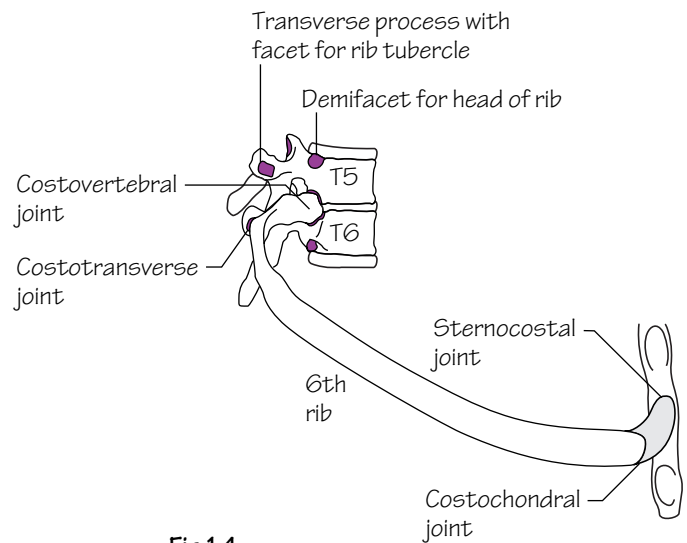
**Fig.1.1**  
The thoracic cage. The outlet (inlet) of the thorax is outlined



**Fig.1.3**  
Bilateral cervical ribs. On the right side the brachial plexus is shown arching over the rib and stretching its lowest trunk



**Fig.1.2**  
A typical rib



**Fig.1.4**  
Joints of the thoracic cage

## The thoracic cage

The thoracic cage is formed by the sternum and costal cartilages in front, the vertebral column behind and the ribs and intercostal spaces laterally.

It is separated from the abdominal cavity by the diaphragm and communicates superiorly with the root of the neck through the *thoracic inlet* (Fig. 1.1).

### The ribs (Fig. 1.1)

- Of the 12 pairs of ribs the first seven articulate with the vertebrae posteriorly and with the sternum anteriorly by way of the costal cartilages (*true ribs*).
- The cartilages of the 8th, 9th and 10th ribs articulate with the cartilages of the ribs above (*false ribs*).
- The 11th and 12th ribs are termed 'floating' because they do not articulate anteriorly (*false ribs*).

### Typical ribs (3rd–9th)

These comprise the following features (Fig. 1.2):

- A *head* which bears two demifacets for articulation with the bodies of: the numerically corresponding vertebra, and the vertebra above (Fig. 1.4).
- A *tubercle* which comprises a rough non-articulating lateral facet as well as a smooth medial facet. The latter articulates with the transverse process of the corresponding vertebra (Fig. 1.4).
- A *subcostal groove*: the hollow on the inferior inner aspect of the shaft which accommodates the intercostal neurovascular structures.

### Atypical ribs (1st, 2nd, 10th, 11th, 12th)

- The **1st rib** (see Fig. 63.2) is short, flat and sharply curved. The head bears a single facet for articulation. A prominent tubercle (*scalene tubercle*) on the inner border of the upper surface represents the insertion site for scalenus anterior. The subclavian vein passes over the 1st rib anterior to this tubercle whereas the subclavian artery and lowest trunk of the brachial plexus pass posteriorly.

*A cervical rib is a rare 'extra' rib which articulates with C7 posteriorly and the 1st rib anteriorly. A neurological deficit as well as vascular insufficiency arise as a result of pressure from the rib on the lowest trunk of the brachial plexus (T1) and subclavian artery, respectively (Fig. 1.3).*

- The **2nd rib** is less curved and longer than the 1st rib.
- The **10th rib** has only one articular facet on the head.
- The **11th and 12th ribs** are short and do not articulate anteriorly. They articulate posteriorly with the vertebrae by way of a single facet on the head. They are devoid of both a tubercle and a subcostal groove.

### The sternum (Fig. 1.1)

The sternum comprises a manubrium, body and xiphoid process.

- The *manubrium* has facets for articulation with the clavicles, 1st costal cartilage and upper part of the 2nd costal cartilage. It articulates inferiorly with the body of the sternum at the *manubriosternal joint*.
- The *body* is composed of four parts or *sternabrae* which fuse between 15 and 25 years of age. It has facets for articulation with the lower part of the 2nd and the 3rd to 7th costal cartilages.
- The *xiphoid* articulates above with the body at the *xiphisternal joint*. The xiphoid usually remains cartilaginous well into adult life.

### Costal cartilages

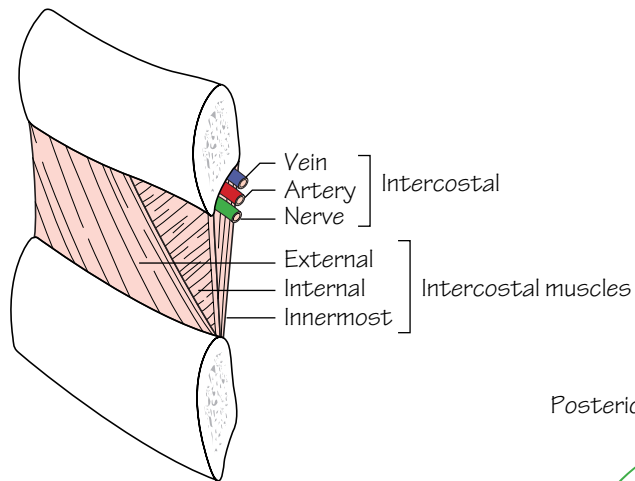
These are bars of hyaline cartilage which connect the upper seven ribs directly to the sternum and the 8th, 9th and 10th ribs to the cartilage immediately above.

### Joints of the thoracic cage (Figs 1.1 and 1.4)

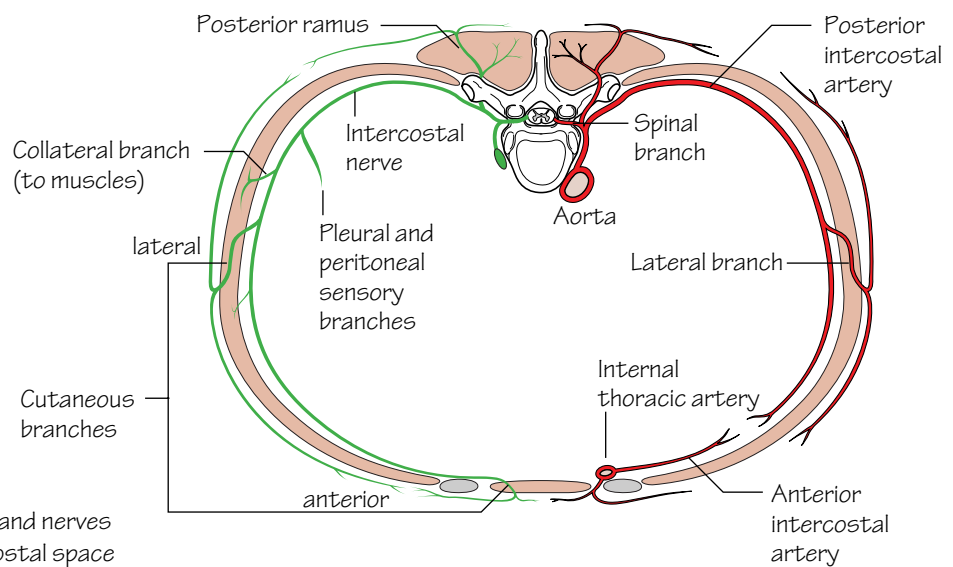
- The *manubriosternal joint* is a symphysis. It usually ossifies after the age of 30.
- The *xiphisternal joint* is also a symphysis.
- The *1st sternocostal joint* is a primary cartilaginous joint. The rest (2nd to 7th) are synovial joints. All have a single synovial joint except for the 2nd which is double.
- The *costochondral joints* (between ribs and costal cartilages) are primary cartilaginous joints.
- The *interchondral joints* (between the costal cartilages of the 8th, 9th and 10th ribs) are synovial joints.
- The *costovertebral joints* comprise two synovial joints formed by the articulations of the demifacets on the head of each rib with the bodies of its corresponding vertebra together with that of the vertebra above. The 1st and 10th–12th ribs have a single synovial joint with their corresponding vertebral bodies.
- The *costotransverse joints* are synovial joints formed by the articulations between the facets on the rib tubercle and the transverse process of its corresponding vertebra.



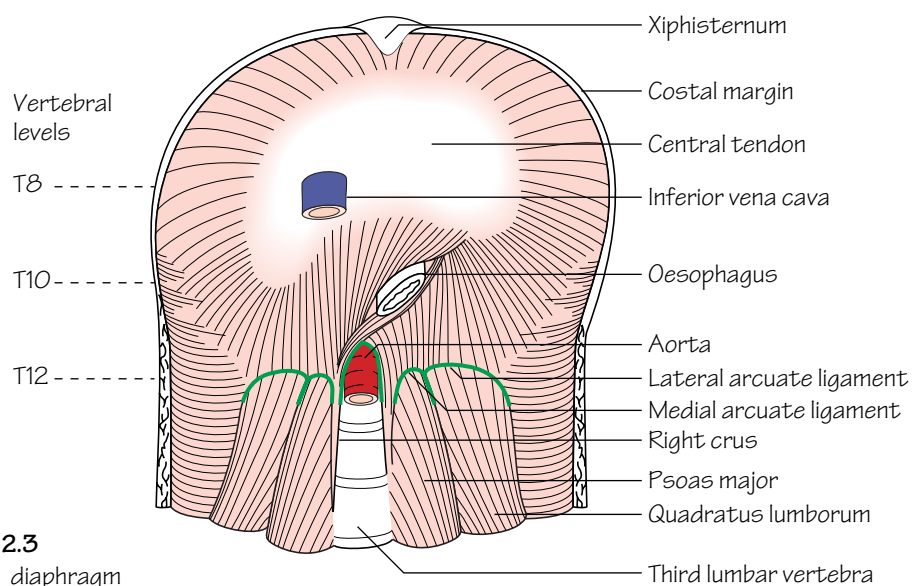
## 2 The thoracic wall II



**Fig.2.1**  
An intercostal space



**Fig.2.2**  
The vessels and nerves  
of an intercostal space



**Fig.2.3**  
The diaphragm

## The intercostal space (Fig. 2.1)

Typically, each space contains three muscles comparable to those of the abdominal wall. These include the:

- *External intercostal*: this muscle fills the intercostal space from the vertebra posteriorly to the costochondral junction anteriorly where it becomes the thin anterior intercostal membrane. The fibres run downwards and forwards from rib above to rib below.
- *Internal intercostal*: this muscle fills the intercostal space from the sternum anteriorly to the angles of the ribs posteriorly where it becomes the posterior intercostal membrane which reaches as far back as the vertebral bodies. The fibres run downwards and backwards.
- *Innermost intercostals*: this group comprises the *subcostal* muscles posteriorly, the *intercostales intimi* laterally and the *transversus thoracis* anteriorly. The fibres of these muscles span more than one intercostal space.

The neurovascular space is the plane in which the neurovascular bundle (intercostal vein, artery and nerve) courses. It lies between the internal intercostal and innermost intercostal muscle layers.

The intercostal structures course under cover of the subcostal groove. *Pleural aspiration should be performed close to the upper border of a rib to minimize the risk of injury.*

## Vascular supply and venous drainage of the chest wall

The intercostal spaces receive their *arterial supply* from the anterior and posterior intercostal arteries.

- The *anterior intercostal arteries* are branches of the internal thoracic artery and its terminal branch the musculophrenic artery. The lowest two spaces have no anterior intercostal supply (Fig. 2.2).
- The first 2–3 *posterior intercostal arteries* arise from the superior intercostal branch of the costocervical trunk, a branch of the 2nd part of the subclavian artery (see Fig. 60.1). The lower nine posterior intercostal arteries are branches of the thoracic aorta. The posterior intercostal arteries are much longer than the anterior intercostal arteries (Fig. 2.2).

The anterior intercostal *veins* drain anteriorly into the internal thoracic and musculophrenic veins. The posterior intercostal veins drain into the azygos and hemiazygos systems (see Fig. 4.2).

## Lymphatic drainage of the chest wall

Lymph drainage from the:

- *Anterior chest wall*: is to the anterior axillary nodes.
- *Posterior chest wall*: is to the posterior axillary nodes.
- *Anterior intercostal spaces*: is to the internal thoracic nodes.
- *Posterior intercostal spaces*: is to the para-aortic nodes.

## Nerve supply of the chest wall (Fig. 2.2)

The intercostal nerves are the anterior primary rami of the thoracic segmental nerves. Only the upper six intercostal nerves run in their intercostal spaces, the remainder gaining access to the anterior abdominal wall.

### Branches of the intercostal nerves include:

- *Cutaneous* anterior and lateral branches.

- A *collateral* branch which supplies the muscles of the intercostal space (also supplied by the main intercostal nerve).
- *Sensory* branches from the pleura (upper nerves) and peritoneum (lower nerves).

Exceptions include:

- The 1st intercostal nerve is joined to the brachial plexus and has no anterior cutaneous branch.
- The 2nd intercostal nerve is joined to the medial cutaneous nerve of the arm by the intercostobrachial nerve branch. The 2nd intercostal nerve consequently supplies the skin of the armpit and medial side of the arm.

## The diaphragm (Fig. 2.3)

The diaphragm separates the thoracic and abdominal cavities. It is composed of a peripheral muscular portion which inserts into a central aponeurosis—the *central tendon*.

The muscular part has three component origins:

- A *vertebral part*: this comprises the *crura* and *arcuate ligaments*.  
The right crus arises from the front of the L1–3 vertebral bodies and intervening discs. Some fibres from the right crus pass around the lower oesophagus.

The left crus originates from L1 and L2 only.

The medial arcuate ligament is made up of thickened fascia which overlies psoas major and is attached medially to the body of L1 and laterally to the transverse process of L1. The lateral arcuate ligament is made up of fascia which overlies quadratus lumborum from the transverse process of L1 medially to the 12th rib laterally.

The median arcuate ligament is a fibrous arch which connects left and right crura.

- A *costal part*: attached to the inner aspects of the lower six ribs.
- A *sternal part*: consists of two small slips arising from the deep surface of the xiphoid process.

## Openings in the diaphragm

Structures traverse the diaphragm at different levels to pass from thoracic to abdominal cavities and vice versa. These levels are as follows:

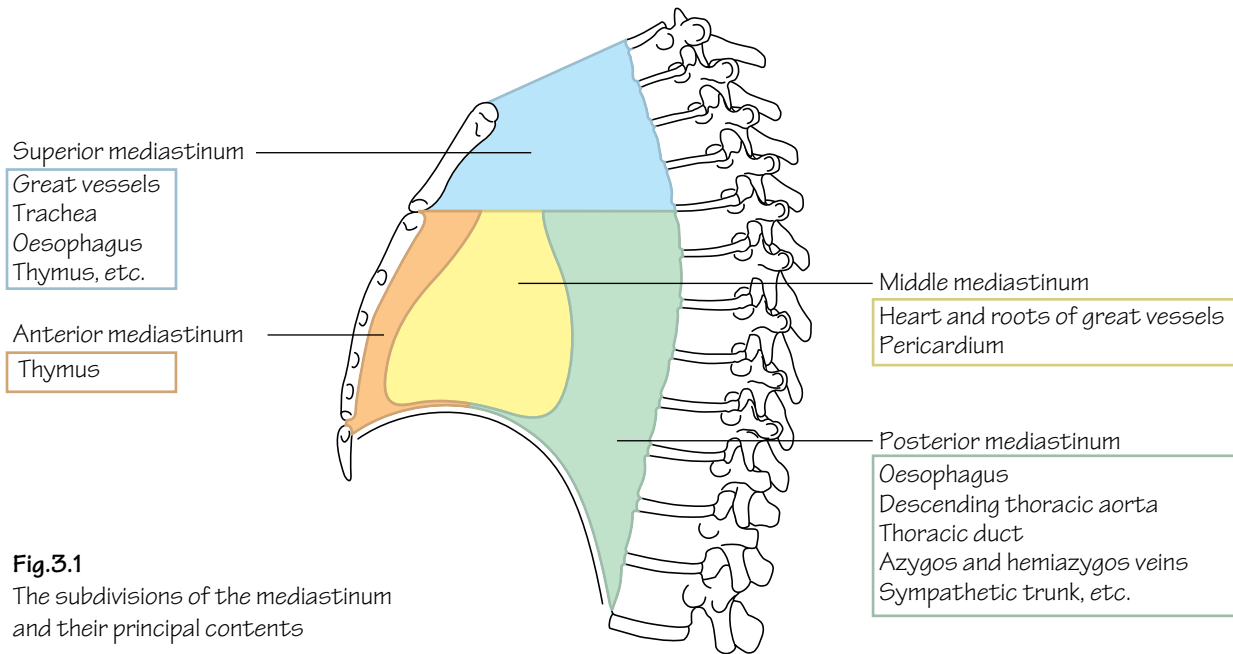
- T8, the *opening for the inferior vena cava*: transmits the inferior vena cava and right phrenic nerve.
- T10, the *oesophageal opening*: transmits the oesophagus, vagi and branches of the left gastric artery and vein.
- T12, the *aortic opening*: transmits the aorta, thoracic duct and azygos vein.

The left phrenic nerve passes into the diaphragm as a solitary structure.

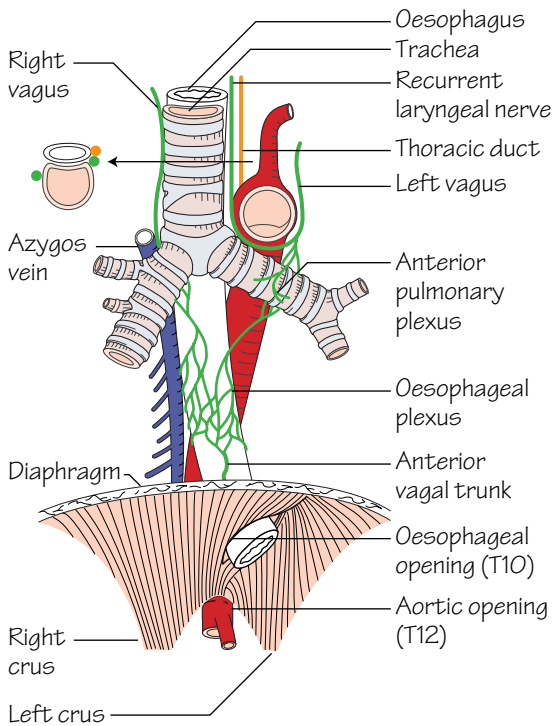
## Nerve supply of the diaphragm

- *Motor supply*: the entire motor supply arises from the phrenic nerves (C3,4,5). Diaphragmatic contraction is the mainstay of inspiration.
- *Sensory supply*: the periphery of the diaphragm receives sensory fibres from the lower intercostal nerves. The sensory supply from the central part is carried by the phrenic nerves.

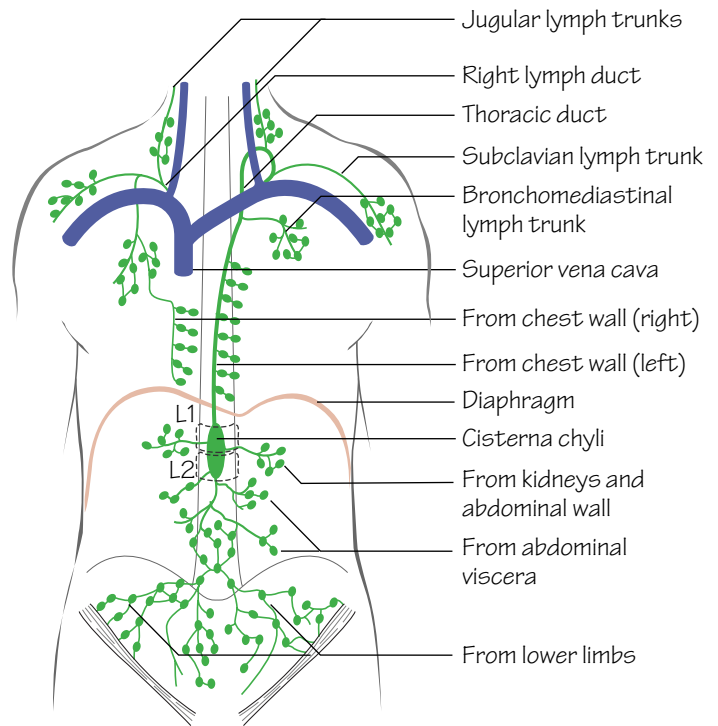
### 3 The mediastinum I—the contents of the mediastinum



**Fig.3.1**  
The subdivisions of the mediastinum and their principal contents



**Fig.3.2**  
The course and principal relations of the oesophagus. Note that it passes through the *right* crus of the diaphragm



**Fig.3.3**  
The thoracic duct and its areas of drainage. The right lymph duct is also shown

### Subdivisions of the mediastinum (Fig. 3.1)

The mediastinum is the space located between the two pleural sacs. For descriptive purposes it is divided into superior and inferior mediastinal regions by a line drawn backwards horizontally from the angle of Louis (manubriosternal joint) to the vertebral column (T4/5 intervertebral disc).

The *superior mediastinum* communicates with the root of the neck through the 'thoracic inlet'. The latter opening is bounded anteriorly by the manubrium, posteriorly by T1 vertebra and laterally by the 1st rib.

The *inferior mediastinum* is further subdivided into the:

- **Anterior mediastinum:** the region in front of the pericardium.
- **Middle mediastinum:** consists of the pericardium and heart.
- **Posterior mediastinum:** the region between the pericardium and vertebrae.

### The contents of the mediastinum (Figs 3.1 and 3.2)

#### The oesophagus

- **Course:** the oesophagus commences as a cervical structure at the level of the cricoid cartilage at C6 in the neck. In the thorax the oesophagus passes initially through the superior and then the posterior mediastina. Having deviated slightly to the left in the neck the oesophagus returns to the midline in the thorax at the level of T5. From here, it passes downwards and forwards to reach the oesophageal opening in the diaphragm (T10).
- **Structure:** the oesophagus is composed of four layers:
  - An inner mucosa of stratified squamous epithelium.
  - A submucous layer.
  - A double muscular layer—longitudinal outer layer and circular inner layer. The muscle is striated in the upper two-thirds and smooth in the lower third.
  - An outer layer of areolar tissue.
- **Relations:** the relations of the oesophagus are shown in Fig. 3.2. On the right side the oesophagus is crossed only by the azygos vein and the right vagus nerve and hence this forms the least hazardous surgical approach.
- **Arterial supply and venous drainage:** owing to the length of this structure (25 cm), the oesophagus receives arterial blood from varied sources throughout its course:
  - **Upper third**—inferior thyroid artery.
  - **Middle third**—oesophageal branches of thoracic aorta.
  - **Lower third**—left gastric branch of coeliac artery.

Similarly the venous drainage varies throughout its length:

- **Upper third**—inferior thyroid veins.
- **Middle third**—azygos system.
- **Lower third**—both the azygos (systemic system) and left gastric veins (portal system).

The dual drainage of the lower third forms a site of portal-systemic anastomosis. *In advanced liver cirrhosis, portal pressure rises resulting in back-pressure on the left gastric tributaries at the lower oesophagus. These veins become distended and fragile (oesophageal varices). They are predisposed to rupture, causing potentially life-threatening haemorrhage.*

- **Lymphatic drainage:** this is to a peri-oesophageal lymph plexus and then to the posterior mediastinal nodes. From here lymph drains into supraclavicular nodes. The lower oesophagus also drains into the nodes around the left gastric vessels.

*Carcinoma of the oesophagus carries an extremely poor prognosis. Two main histological types—squamous and adenocarcinoma—account for the majority of tumours. The incidence of adenocarcinoma of the lower third of the oesophagus is currently increasing for unknown reasons. Most tumours are unresectable at the time of diagnosis. The insertion of stents and use of lasers to pass through tumour obstruction have become the principal methods of palliation.*

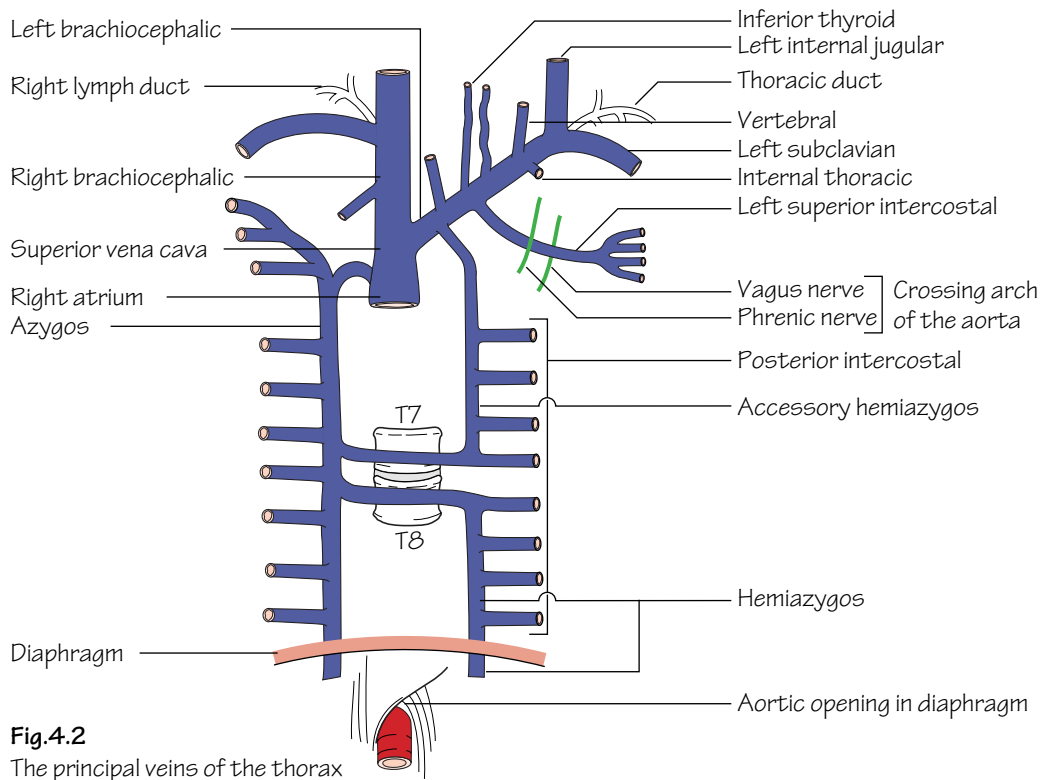
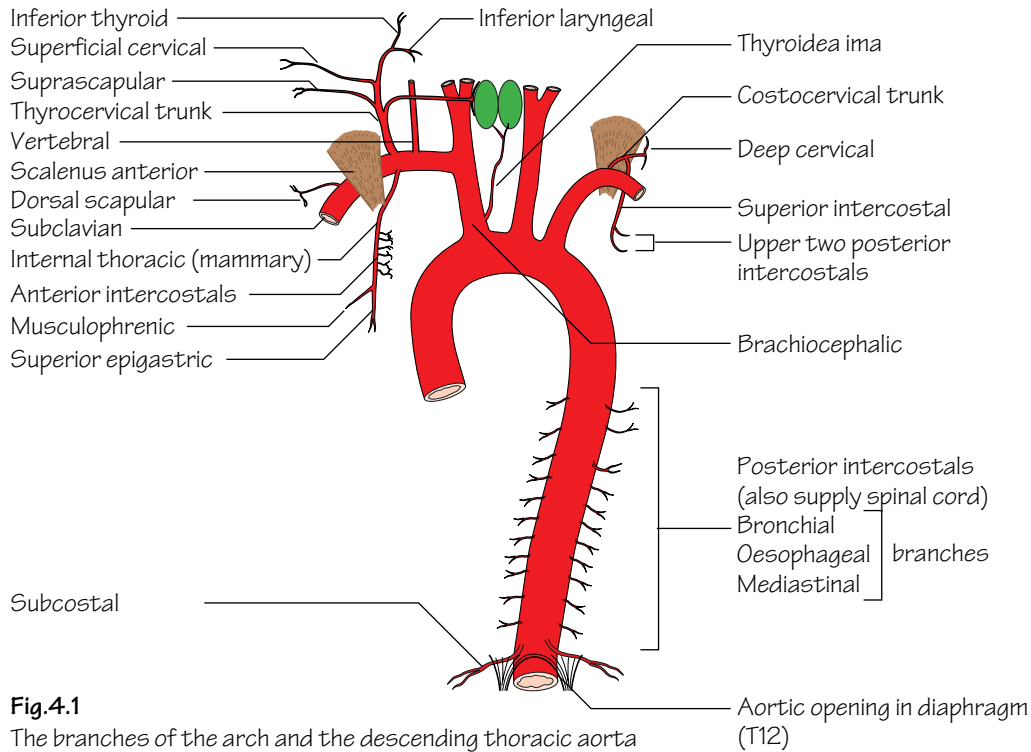
#### The thoracic duct (Fig. 3.3)

- The *cisterna chyli* is a lymphatic sac that receives lymph from the abdomen and lower half of the body. It is situated between the abdominal aorta and the right crus of the diaphragm.
- The *thoracic duct* carries lymph from the cisterna chyli through the thorax to drain into the left brachiocephalic vein. It usually receives tributaries from the left jugular, subclavian and mediastinal lymph trunks, although they may open into the large neck veins directly.
- On the right side the main lymph trunks from the right upper body usually join and drain directly through a common tributary, the *right lymph duct*, into the right brachiocephalic vein.

#### The thymus gland

- This is an important component of the lymphatic system. It usually lies behind the manubrium (in the superior mediastinum) but can extend to about the 4th costal cartilage in the anterior mediastinum. After puberty the thymus is gradually replaced by fat.

## 4 The mediastinum II—the vessels of the thorax



### The thoracic aorta (Fig. 4.1)

The *ascending aorta* arises from the aortic vestibule behind the infundibulum of the right ventricle and the pulmonary trunk. It is continuous with the *aortic arch*. The arch lies posterior to the lower half of the manubrium and arches from front to back over the left main bronchus. The *descending thoracic aorta* is continuous with the arch and begins at the lower border of the body of T4. It initially lies slightly to the left of the midline and then passes medially to gain access to the abdomen by passing beneath the median arcuate ligament of the diaphragm at the level of T12. From here it continues as the abdominal aorta.

#### The branches of the ascending aorta are the:

- *Right and left coronary arteries.*

#### The branches of the aortic arch are the:

- *Brachiocephalic artery:* arises from the arch behind the manubrium and courses upwards to bifurcate into *right subclavian* and *right common carotid branches* posterior to the right sternoclavicular joint.
- *Left common carotid artery:* see p. 133.
- *Left subclavian artery.*
- *Thyroidea ima artery.*

#### The branches of the descending thoracic aorta include the:

- *Oesophageal, bronchial, mediastinal, posterior intercostal and subcostal arteries.*

### The subclavian arteries (see Fig. 60.1)

The subclavian arteries become the axillary arteries at the outer border of the 1st rib. Each artery is divided into three parts by scalenus anterior:

- **1st part:** the part of the artery that lies medial to the medial border of scalenus anterior. It gives rise to three branches, the: *vertebral artery* (p. 135), *thyrocervical trunk* and *internal thoracic (mammary) artery*. The latter artery courses on the posterior surface of the anterior chest wall one fingerbreadth from the lateral border of the sternum. Along its course it gives off anterior intercostal, thymic and perforating branches. The 'perforators' pass through the anterior chest wall to

supply the breast. The internal thoracic artery divides behind the 6th costal cartilage into superior epigastric and musculophrenic branches. The thyrocervical trunk terminates as the inferior thyroid artery.

- **2nd part:** the part of the artery that lies behind scalenus anterior. It gives rise to the *costocervical trunk* (see Fig. 60.1).
- **3rd part:** the part of the artery that lies lateral to the lateral border of scalenus anterior. This part gives rise to the *dorsal scapular artery*.

### The great veins (Fig. 4.2)

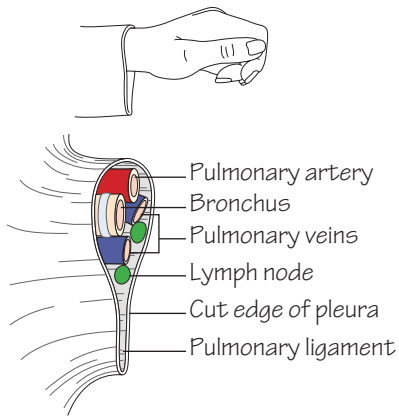
The *brachiocephalic veins* are formed by the confluence of the *subclavian* and *internal jugular* veins behind the sternoclavicular joints. The left brachiocephalic vein traverses diagonally behind the manubrium to join the right brachiocephalic vein behind the 1st costal cartilage thus forming the *superior vena cava*. The superior vena cava receives only one tributary—the *azygos vein*.

### The azygos system of veins (Fig. 4.2)

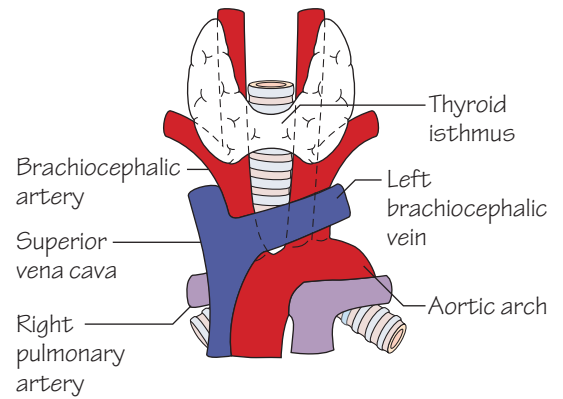
- The *azygos vein:* commences as the union of the right subcostal vein and one or more veins from the abdomen. It passes through the aortic opening in the diaphragm, ascends on the posterior chest wall to the level of T4 and then arches over the right lung root to enter the superior vena cava. It receives tributaries from the: lower eight posterior intercostal veins, right superior intercostal vein and hemiazygos veins.
- The *hemiazygos vein:* arises on the left side in the same manner as the azygos vein. It passes through the aortic opening in the diaphragm and up to the level of T9 from where it passes diagonally behind the aorta and thoracic duct to drain into the azygos vein at the level of T8. It receives venous blood from the lower four left posterior intercostal veins.
- The *accessory hemiazygos vein:* drains blood from the middle posterior intercostal veins (as well as some bronchial and mid-oesophageal veins). The accessory hemiazygos crosses to the right to drain into the azygos vein at the level of T7.
- The upper four left intercostal veins drain into the left brachiocephalic vein via the left superior intercostal vein.



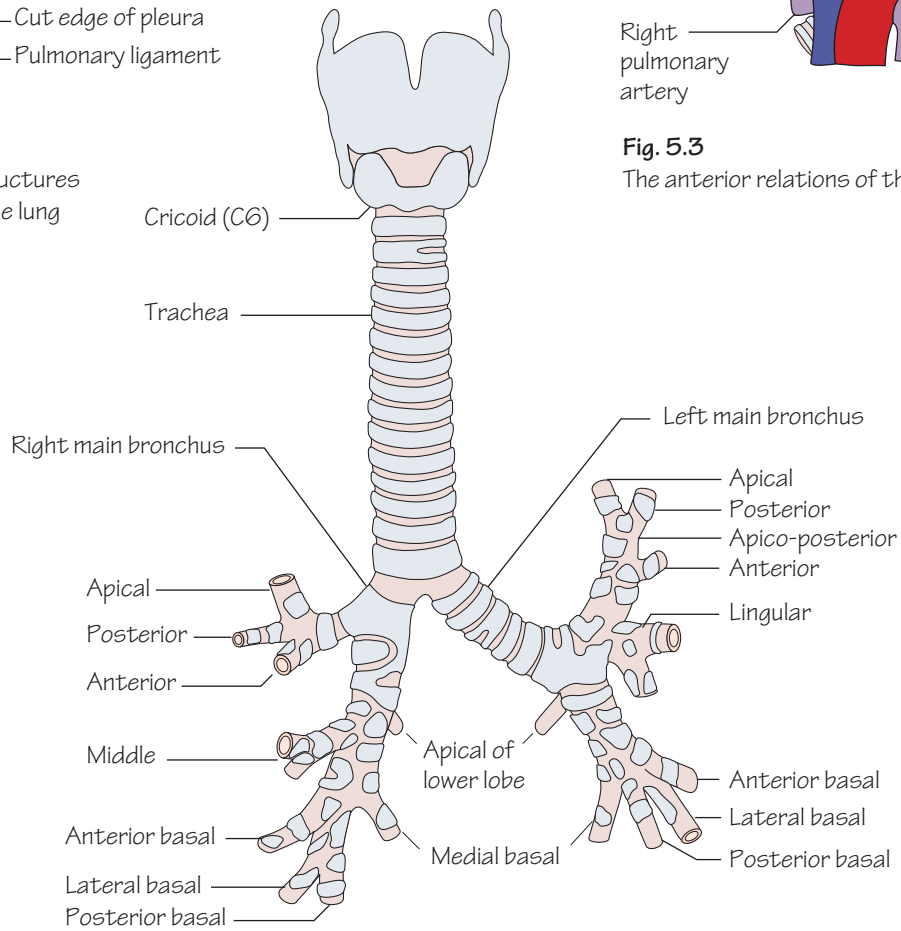
# 5 The pleura and airways



**Fig. 5.1**  
The principal structures in the hilum of the lung



**Fig. 5.3**  
The anterior relations of the trachea



**Fig. 5.2**  
The trachea and main bronchi

The respiratory tract is most often discussed in terms of upper and lower parts. The upper respiratory tract relates to the nasopharynx and larynx whereas the lower relates to the trachea, bronchi and lungs.

### The pleurae

- Each pleura consists of two layers: a *visceral layer* which is adherent to the lung and a *parietal layer* which lines the inner aspect of the chest wall, diaphragm and sides of the pericardium and mediastinum.
- At the hilum of the lung the visceral and parietal layers become continuous. This cuff hangs loosely over the hilum and is known as the *pulmonary ligament*. It permits expansion of the pulmonary veins and movement of hilar structures during respiration (Fig. 5.1).
- The two pleural cavities do not connect.
- The pleural cavity contains a small amount of pleural fluid which acts as a lubricant decreasing friction between the pleurae.
- During maximal inspiration the lungs almost fill the pleural cavities. In quiet inspiration the lungs do not expand fully into the costo-diaphragmatic and costomediastinal recesses of the pleural cavity.
- The parietal pleura is sensitive to pain and touch (carried by the intercostal and phrenic nerves). The visceral pleura is sensitive only to stretch (carried by autonomic afferents from the pulmonary plexus).

*Air can enter the pleural cavity following a fractured rib or a torn lung (pneumothorax). This eliminates the normal negative pleural pressure, causing the lung to collapse.*

*Inflammation of the pleura (pleurisy) results from infection of the adjacent lung (pneumonia). When this occurs the inflammatory process renders the pleura sticky. Under these circumstances a pleural rub can often be auscultated over the affected region during inspiration and expiration. Pus in the pleural cavity (secondary to an infective process) is termed an empyema.*

### The trachea (Fig. 5.2)

- **Course:** the trachea commences at the level of the cricoid cartilage in the neck (C6). It terminates at the level of the angle of Louis (T4/5) where it bifurcates into right and left main bronchi.

- **Structure:** the trachea is a rigid fibroelastic structure. Incomplete rings of hyaline cartilage continuously maintain the patency of the lumen. The trachea is lined internally with ciliated columnar epithelium.

- **Relations:** behind the trachea lies the oesophagus. The 2nd, 3rd and 4th tracheal rings are crossed anteriorly by the thyroid isthmus (Figs 5.3 and 64.1).

- **Blood supply:** the trachea receives its blood supply from branches of the inferior thyroid and bronchial arteries.

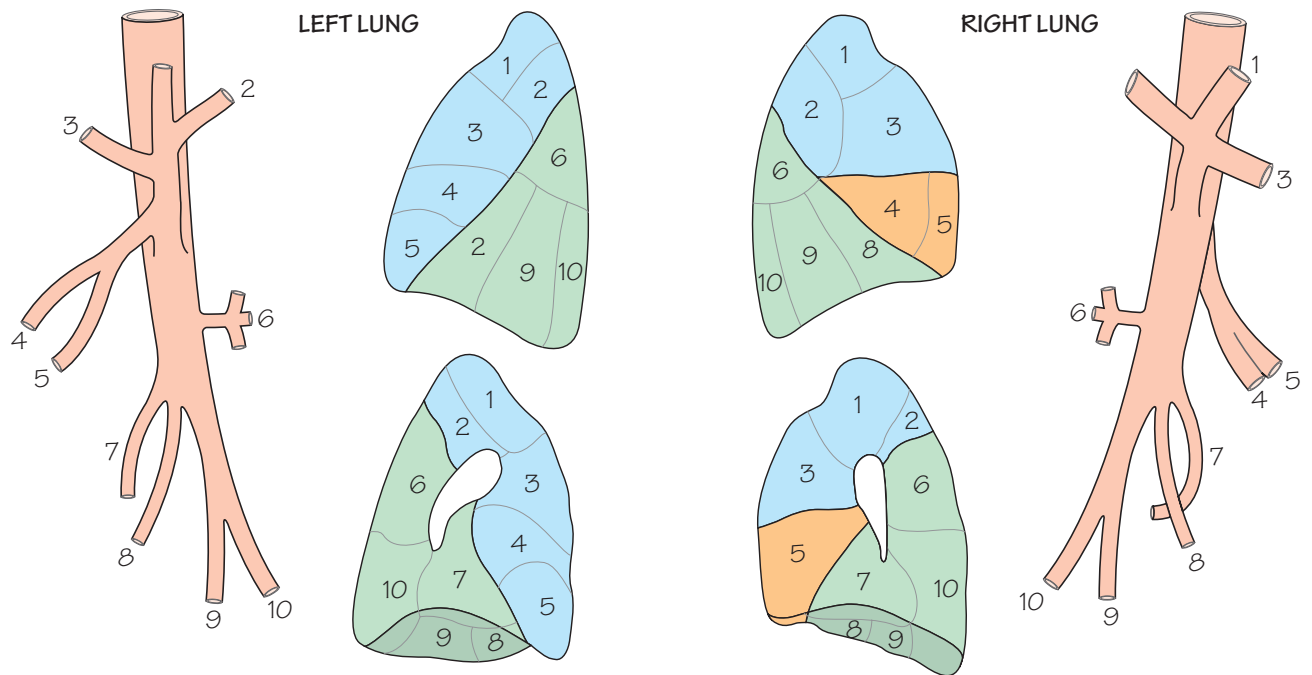
### The bronchi and bronchopulmonary segments (Fig. 5.2)

- The right main bronchus is shorter, wider and takes a more vertical course than the left. The width and vertical course of the right main bronchus account for the tendency for inhaled foreign bodies to preferentially impact in the right middle and lower lobe bronchi.
- The left main bronchus enters the hilum and divides into a superior and inferior lobar bronchus. The right main bronchus gives off the bronchus to the upper lobe prior to entering the hilum and once into the hilum divides into middle and inferior lobar bronchi.
- Each lobar bronchus divides within the lobe into segmental bronchi. Each segmental bronchus enters a bronchopulmonary segment.
- Each bronchopulmonary segment is pyramidal in shape with its apex directed towards the hilum (see Fig. 6.1). It is a structural unit of a lobe that has its own segmental bronchus, artery and lymphatics. If one bronchopulmonary segment is diseased it may be resected with preservation of the rest of the lobe. The veins draining each segment are intersegmental.

*Bronchial carcinoma is the commonest cancer among men in the United Kingdom. Four main histological types occur of which small cell carries the worst prognosis. The overall prognosis remains appalling with only 10% of sufferers surviving 5 years. It occurs most commonly in the mucous membranes lining the major bronchi near the hilum. Local invasion and spread to hilar and tracheobronchial nodes occurs early.*



# 6 The lungs

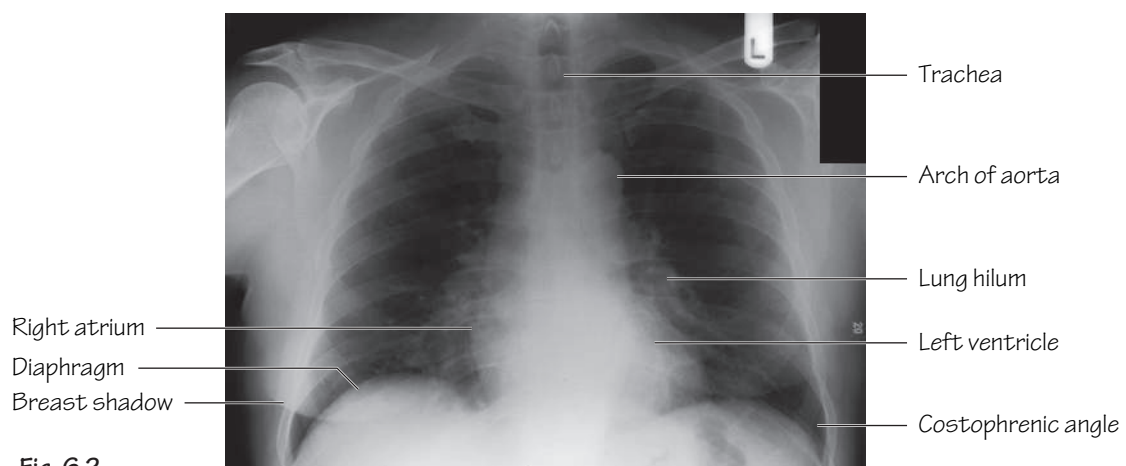


- |         |  |
|---------|--|
| 1       | Apical   |
| 2       | Posterior (1 and 2 from a common apico-posterior stem on the left side)      |
| 3       | Anterior   |
| 4 and 5 | Lateral and medial middle lobe (superior and inferior lingular on left side) |
| 6       | Superior (apical)  |
| 7       | Medial basal (cardiac on left)   |
| 8       | Anterior basal (7 and 8 often by a common stem on left)                      |
| 9       | Lateral basal  |
| 10      | Posterior basal  |

- Upper lobe
- Middle lobe
- Lower lobe

**Fig. 6.1**

The segmental bronchi (viewed from the lateral side) and the bronchopulmonary segments, with their standard numbering



**Fig. 6.2**  
P-A. Chest X-ray

## The lungs (Fig. 6.1)

- The lungs provide an alveolar surface area of approximately 40 m<sup>2</sup> for gaseous exchange.
- Each lung has: an *apex* which reaches above the sternal end of the 1st rib; a *costovertebral* surface which underlies the chest wall; a *base* overlying the diaphragm and a *mediastinal* surface which is moulded to adjacent mediastinal structures.
- **Structure:** the right lung is divided into upper, middle and lower lobes by *oblique* and *horizontal fissures*. The left lung has only an oblique fissure and hence no middle lobe. The *lingular segment* represents the left sided equivalent of the right middle lobe. It is, however, an anatomical part of the left upper lobe.

Structures enter or leave the lungs by way of the lung hilum which, as mentioned earlier, is ensheathed in a loose pleural cuff (see Fig. 5.1).

- **Blood supply:** the bronchi and parenchymal tissue of the lungs are supplied by *bronchial arteries*—branches of the descending thoracic aorta. *Bronchial veins*, which also communicate with pulmonary veins, drain into the *azygos* and *hemiazygos*. The alveoli receive deoxygenated blood from terminal branches of the pulmonary artery and oxygenated blood returns via tributaries of the pulmonary veins. Two pulmonary veins return blood from each lung to the left atrium.
- **Lymphatic drainage of the lungs:** lymph returns from the periphery towards the hilar tracheobronchial groups of nodes and from here to mediastinal lymph trunks.
- **Nerve supply of the lungs:** a *pulmonary plexus* is located at the root of each lung. The plexus is composed of sympathetic fibres (from the sympathetic trunk) and parasympathetic fibres (from the vagus). Efferent fibres from the plexus supply the bronchial musculature and afferents are received from the mucous membranes of bronchioles and from the alveoli.

## The mechanics of respiration

- A negative intrapleural pressure keeps the lungs continuously partially inflated.

- During normal *inspiration*: contraction of the upper external intercostals increases the A-P diameter of the upper thorax; contraction of the lower external intercostals increases the transverse diameter of the lower thorax; and contraction of the diaphragm increases the vertical length of the internal thorax. These changes serve to increase lung volume and thereby result in reduction of intrapulmonary pressure causing air to be sucked into the lungs. In deep inspiration the sternocleidomastoid, scalenus anterior and medius, serratus anterior and pectoralis major and minor all aid to maximize thoracic capacity. The latter are termed collectively—the *accessory muscles of respiration*.
- *Expiration* is mostly due to passive relaxation of the muscles of inspiration and elastic recoil of the lungs. In forced expiration the abdominal musculature aids ascent of the diaphragm.

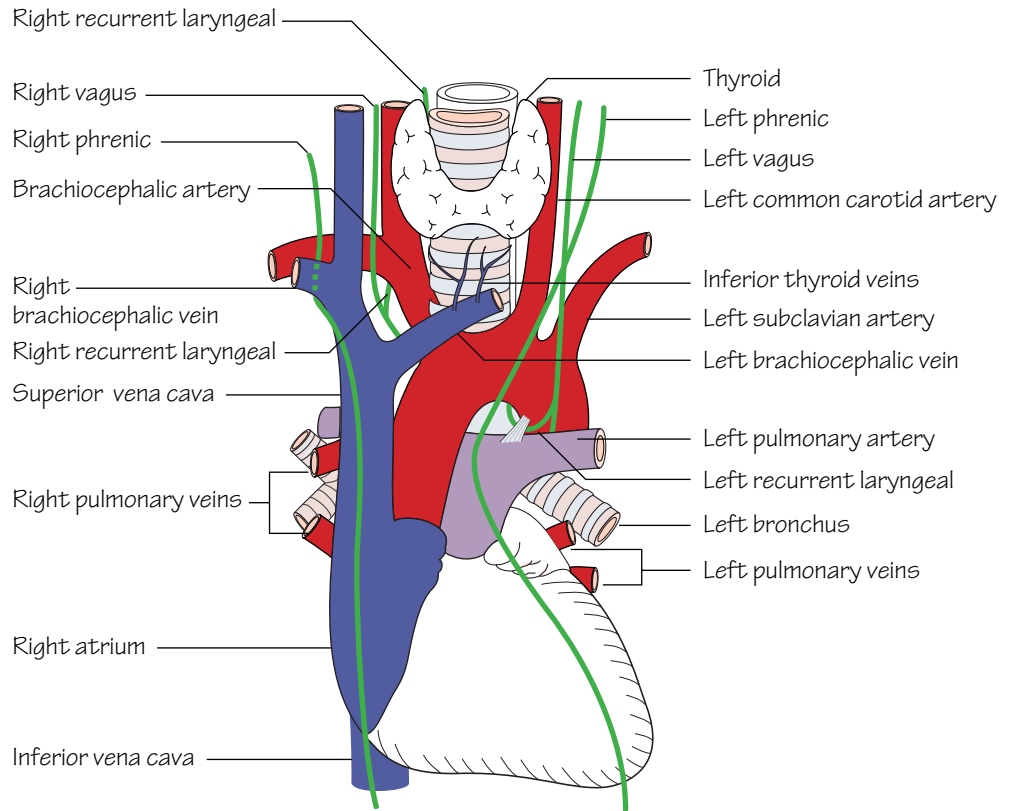
## The chest X-ray (CXR) (Fig. 6.2)

The standard CXR is the postero-anterior (PA) view. This is taken with the subject's chest touching the cassette holder and the X-ray beam directed anteriorly from behind.

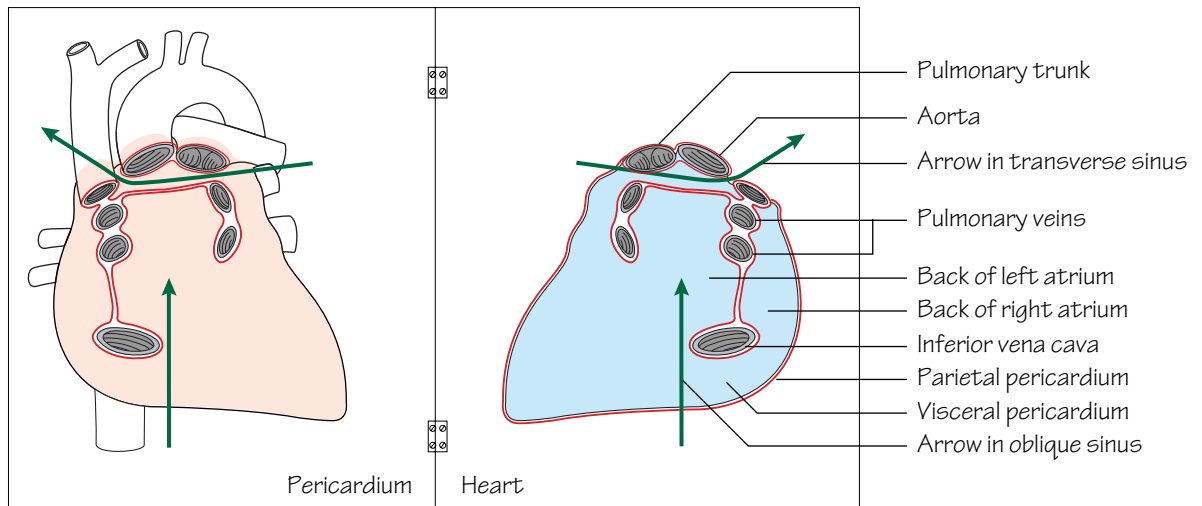
Structures visible on the chest X-ray include the:

- **Heart borders:** any significant enlargement of a particular chamber can be seen on the X-ray. In congestive cardiac failure all four chambers of the heart are enlarged (*cardiomegaly*). This is identified on the PA view as a cardiothoracic ratio greater than 0.5. This ratio is calculated by dividing the width of the heart by the width of the thoracic cavity at its widest point.
- **Lungs:** the lungs are radiolucent. Dense streaky shadows, seen at the lung roots, represent the blood-filled pulmonary vasculature.
- **Diaphragm:** the angle made between the diaphragm and chest wall is termed the *costophrenic angle*. This angle is lost when a pleural effusion collects.
- **Mediastinal structures:** these are difficult to distinguish as there is considerable overlap. Clearly visible, however, is the aortic arch which, when pathologically dilated (aneurysmal), creates the impression of 'widening' of the mediastinum.

# 7 The heart I



**Fig.7.1**  
The heart and the great vessels



**Fig.7.2**  
The sinuses of the pericardium. The heart has been removed from the pericardial cavity and turned over to show its posterior aspect. The red line shows the cut edges where the visceral pericardium is continuous with the parietal pericardium. Visceral layer: blue, parietal layer: red

The heart, pericardium, lung roots and adjoining parts of the great vessels constitute the middle mediastinum (Figs 3.1 and 7.1).

### The pericardium

The pericardium comprises fibrous and serous components. The *fibrous* pericardium is a strong layer which covers the heart. It fuses with the roots of the great vessels above and with the central tendon of the diaphragm below. The *serous* pericardium lines the fibrous pericardium (parietal layer) and is reflected at the vessel roots to cover the heart surface (visceral layer). The serous pericardium provides smooth surfaces for the heart to move against. Two important sinuses are located between the parietal and visceral layers. These are the:

- *Transverse sinus*—located between the superior vena cava and left atrium posteriorly and the pulmonary trunk and aorta anteriorly (Fig. 7.2).
- *Oblique sinus*—behind the left atrium, the sinus is bounded by the inferior vena cava and the pulmonary veins (Fig. 7.2).

- **Blood supply:** from the pericardiophrenic branches of the internal thoracic arteries.

- **Nerve supply:** the fibrous pericardium and the parietal layer of serous pericardium are supplied by the phrenic nerve.

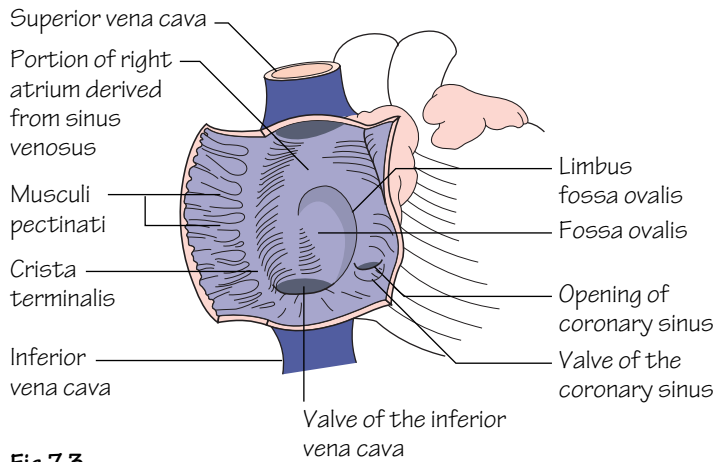
*Following thoracic trauma blood can collect in the pericardial space (haemopericardium) which may, in turn, lead to cardiac tamponade. This manifests itself clinically as shock, distended neck veins and muffled/absent heart sounds (Beck's triad). This condition is fatal unless pericardial decompression is effected immediately.*

### The heart surfaces

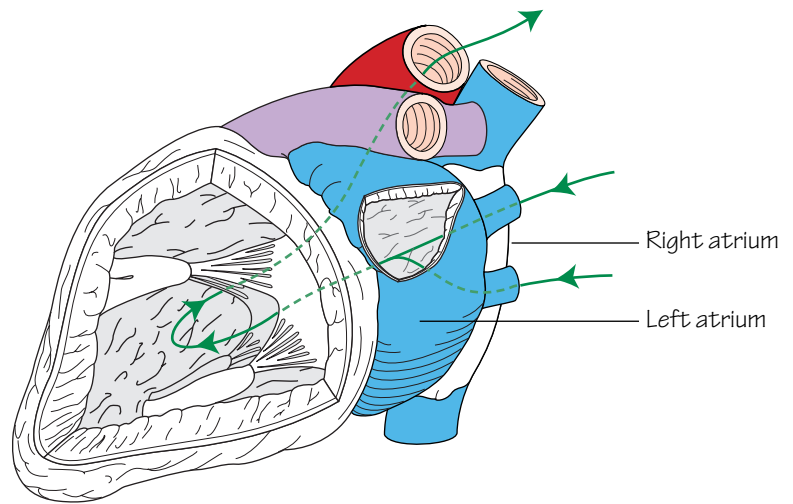
- The *anterior (sternocostal)* surface comprises the: right atrium, atrioventricular groove, right ventricle, a small strip of left ventricle and the auricle of the left atrium.

- The *inferior (diaphragmatic)* surface comprises the: right atrium, atrioventricular groove and both ventricles separated by the interventricular groove.

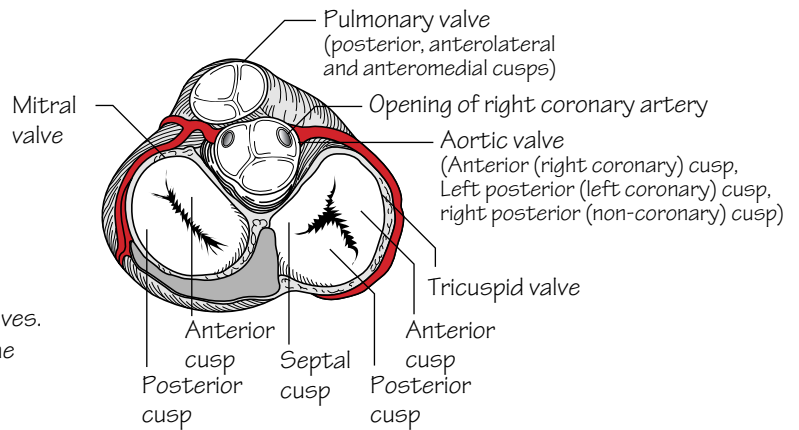
- The *posterior surface (base)* comprises the left atrium receiving the four pulmonary veins.



**Fig.7.3**  
The interior of the right atrium



**Fig.7.4**  
The interior of the left atrium and ventricle. The arrow shows the direction of blood flow. Note that blood flows over both surfaces of the anterior cusp of the mitral valve



**Fig.7.5**  
A section through the heart at the level of the valves. The aortic and pulmonary valves are closed and the mitral and tricuspid valves open, as they would be during ventricular diastole

## The heart chambers

### The right atrium (Fig. 7.3)

- Receives deoxygenated blood from the inferior vena cava below and from the superior vena cava above.
- Receives the *coronary sinus* in its lower part (p. 23).
- The upper end of the atrium projects to the left of the superior vena cava as the *right auricle*.
- The *sulcus terminalis* is a vertical groove on the outer surface of the atrium. This groove corresponds internally to the *crista terminalis*—a muscular ridge which separates the smooth walled atrium (derived from the sinus venosus) from the rest of the atrium (derived from the true fetal atrium). The latter contains horizontal ridges of muscle—*musculi pectinati*.
- Above the coronary sinus the interatrial septum forms the posterior wall. The depression in the septum—the *fossa ovalis*—represents the site of the *foramen ovale*. Its floor is the fetal *septum primum*. The upper ridge of the fossa ovalis is termed the *limbus*, which represents the *septum secundum*. Failure of fusion of the septum primum with the septum secundum gives rise to a patent foramen ovale (*atrial septal defect*) but as long as the two septa still overlap, there will be no functional disability. A patent foramen gives rise to a left–right shunt.

### The right ventricle

- Receives blood from the right atrium through the tricuspid valve (see below). The edges of the valve cusps are attached to *chordae tendineae* which are, in turn, attached below to papillary muscles. The latter are projections of muscle bundles on the ventricular wall.
- The wall of the right ventricle is thicker than that of the atria but not as thick as that of the left ventricle. The wall contains a mass of muscular bundles known as *trabeculae carneae*. One prominent bundle projects forwards from the interventricular septum to the anterior wall. This is the *moderator band* (or septomarginal trabecula) and is of importance in the conduction of impulses as it contains the right branch of the atrioventricular bundle.

- The *infundibulum* is the smooth walled outflow tract of the right ventricle.
- The pulmonary valve (see below) is situated at the top of the infundibulum. It is composed of three semilunar cusps. Blood flows through the valve and into the pulmonary arteries via the pulmonary trunk to be oxygenated in the lungs.

### The left atrium

- Receives oxygenated blood from four pulmonary veins which drain posteriorly.
- The cavity is smooth walled except for the atrial appendage.
- On the septal surface a depression marks the fossa ovalis.
- The mitral (bicuspid) valve guards the passage of blood from the left atrium to the left ventricle.

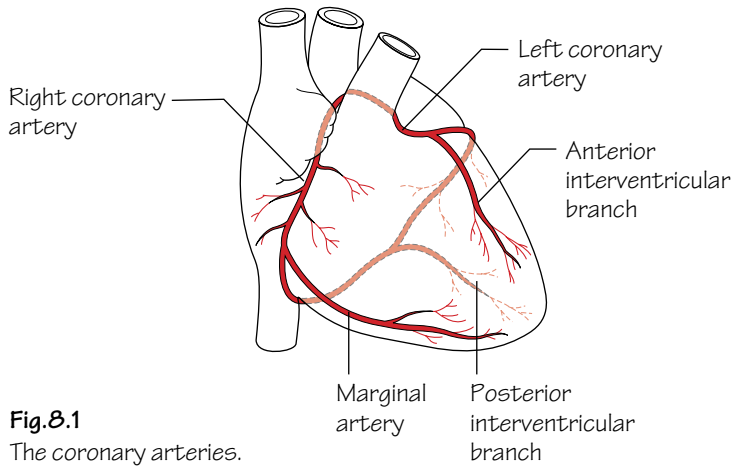
### The left ventricle (Fig. 7.4)

- The wall of the left ventricle is considerably thicker than that of the right ventricle but the structure is similar. The thick wall is necessary to pump oxygenated blood at high pressure through the systemic circulation. Trabeculae carneae project from the wall with papillary muscles attached to the mitral valve cusp edges by way of chordae tendineae.
- The *vestibule* is a smooth walled part of the left ventricle which is located below the aortic valve and constitutes the outflow tract.

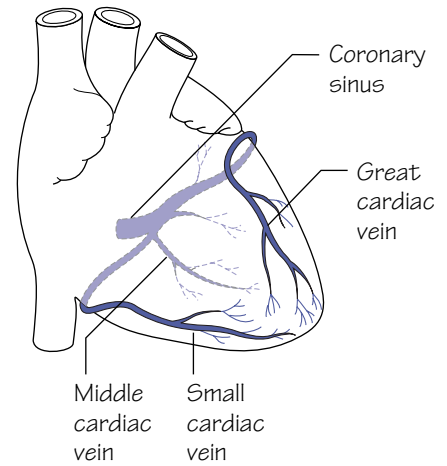
### The heart valves (Fig. 7.5)

- The purpose of valves within the heart is to maintain unidirectional flow.
- The *mitral (bicuspid)* and *tricuspid* valves are flat. During ventricular systole the free edges of the cusps come into contact and eversion is prevented by the pull of the chordae. Papillary muscle rupture can occur as a complication of myocardial infarction. This is evident clinically by a pansystolic murmur *representing regurgitant flow of blood from ventricle to atrium*.
- The *aortic* and *pulmonary* valves are composed of three semilunar cusps which are cup shaped. During ventricular diastole back-pressure of blood above the cusps forces them to fill and hence close.

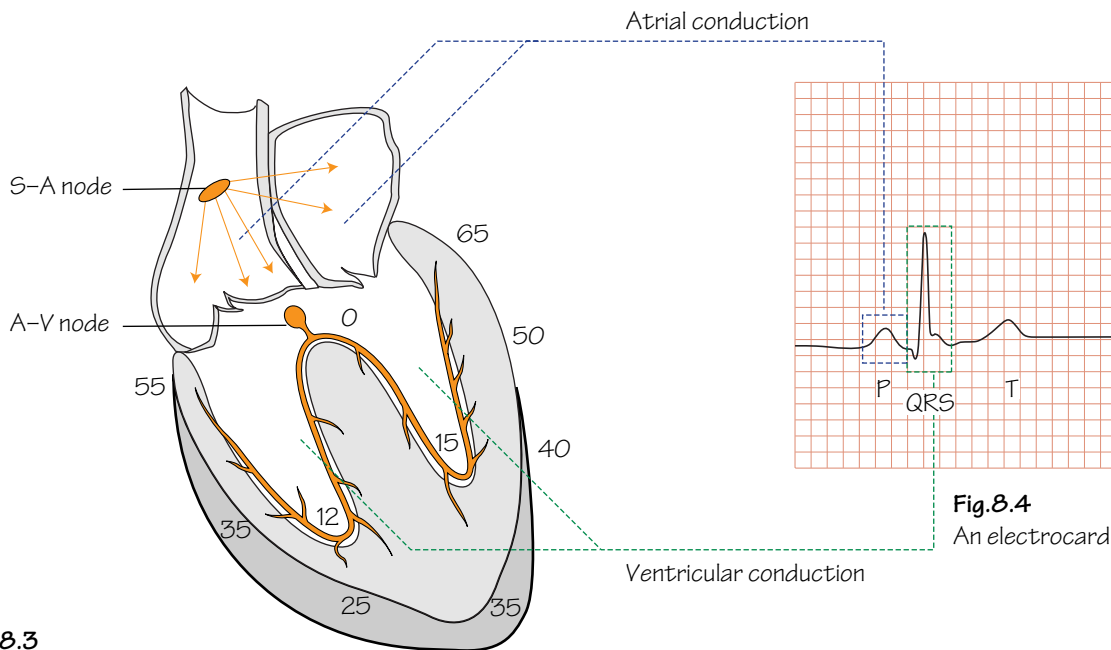
# 8 The heart II



**Fig.8.1**  
The coronary arteries.  
Variations are common



**Fig.8.2**  
The venous drainage of the heart



**Fig.8.3**  
The direction and timing of the spread of action potential in the conducting system of the heart.  
Times are in msec

**Fig.8.4**  
An electrocardiogram

The grooves between the four heart chambers represent the sites that offer the least stretch during systole and, for this reason, are where most of the vessels supplying the heart are situated.

### The arterial supply of the heart (Fig. 8.1)

The coronary arteries are responsible for supplying the heart itself with oxygenated blood.

*The coronary arteries are functional end-arteries and hence following a total occlusion, the myocardium supplied by the blocked artery is deprived of its blood supply (myocardial infarction). When the vessel lumen gradually narrows due to atheromatous change of the walls, patients complain of gradually increasing chest pain on exertion (angina). Under these conditions the increased demand placed on the myocardium cannot be met by the diminished arterial supply. Angina that is not amenable to pharmacological control can be relieved by dilating (angioplasty), or surgically bypassing (coronary artery bypass grafting), the arterial stenosis. The latter procedure is usually performed using a reversed length of great saphenous vein anastomosed to the proximal aorta and then distally to the coronary artery beyond the stenosis. Ischaemic heart disease is the leading cause of death in the western world and consequently a thorough knowledge of the coronary anatomy is essential.*

The origins of the coronary arteries are as follows:

- The left coronary artery arises from the aortic sinus immediately above the left posterior cusp of the aortic valve (see Fig. 7.5).
- The right coronary artery arises from the aortic sinus immediately above the anterior cusp of the aortic valve (see Fig. 7.5).

There is considerable variation in size and distribution zones of the coronary arteries. For example, in some people the *posterior interventricular* branch of the right coronary artery is large and supplies a large part of the left ventricle whereas in the majority this is supplied by the *anterior interventricular* branch of the left coronary.

Similarly, the *sinu-atrial node* is usually supplied by a nodal branch of the right coronary artery but in 30–40% of the population it receives its supply from the left coronary.

### The venous drainage of the heart (Fig. 8.2)

The venous drainage systems in the heart include:

- The *veins which accompany the coronary arteries* and drain into the

right atrium via the *coronary sinus*. The coronary sinus drains into the right atrium to the left of and superior to the opening of the inferior vena cava. The *great cardiac vein* follows the anterior interventricular branch of the left coronary and then sweeps backwards to the left in the atrioventricular groove. The *middle cardiac vein* follows the posterior interventricular artery and, along with the *small cardiac vein* which follows the marginal artery, drains into the coronary sinus. The coronary sinus drains the vast majority of the heart's venous blood.

- The *venae cordis minimi*: these are small veins which drain directly into the cardiac chambers.
- The *anterior cardiac veins*: these are small veins which cross the atrioventricular groove to drain directly into the right atrium.

### The conducting system of the heart (Figs 8.3 and 8.4)

- The sinu-atrial (SA) node is the pacemaker of the heart. It is situated near the top of the crista terminalis, below the superior vena caval opening into the right atrium. Impulses generated by the SA node are conducted throughout the atrial musculature to effect synchronous atrial contraction. *Disease or degeneration of any part of the conduction pathway can lead to dangerous interruption of heart rhythm. Degeneration of the SA node leads to other sites of the conduction pathway taking over the pacemaking role, albeit usually at a slower rate.*
- Impulses reach the *atrioventricular* (AV) node which lies in the interatrial septum just above the opening for the coronary sinus. From here the impulse is transmitted to the ventricles via the *atrioventricular bundle* (of His) which descends in the interventricular septum.
- The *bundle of His* divides into right and left branches which send *Purkinje fibres* to lie within the subendocardium of the ventricles. The position of the Purkinje fibres accounts for the almost synchronous contraction of the ventricles.

### The nerve supply of the heart

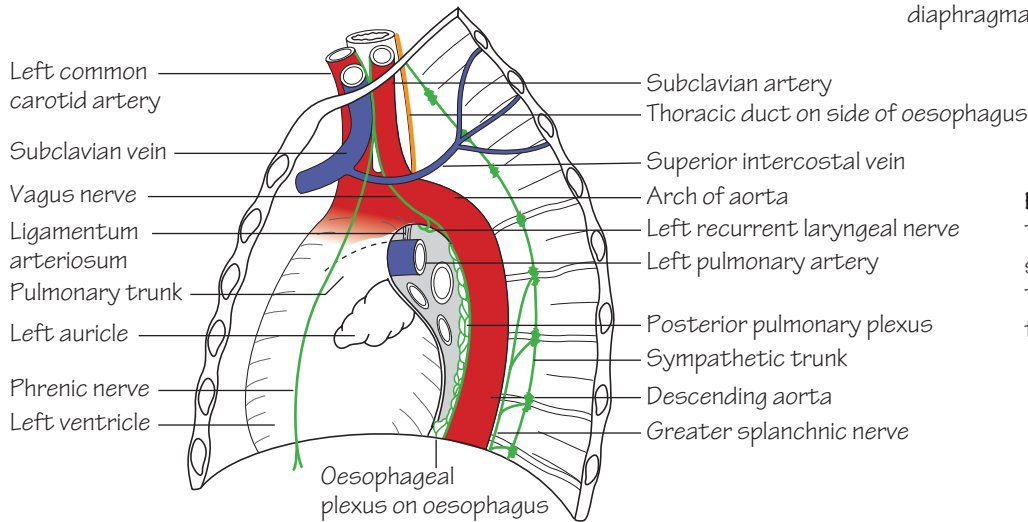
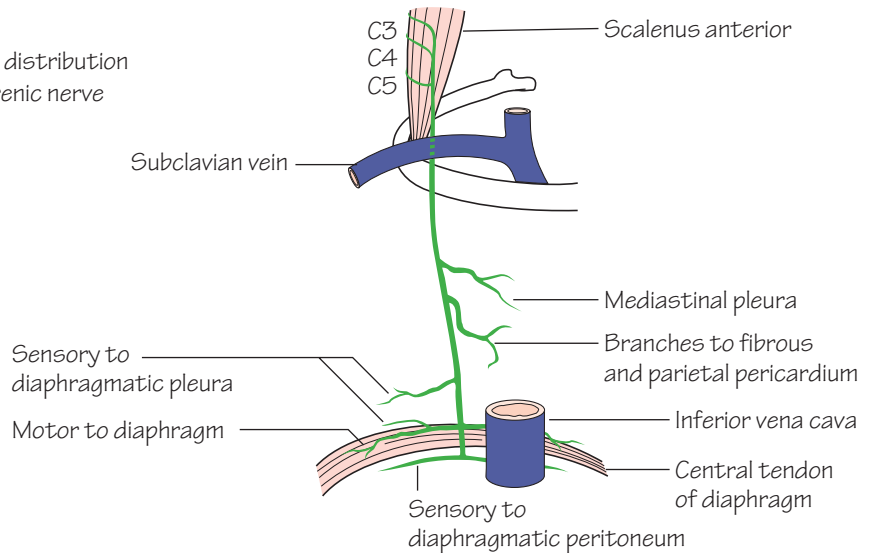
The heart receives both a sympathetic and a parasympathetic nerve supply so that heart rate can be controlled to demand.

- The *parasympathetic supply* (bradycardic effect): is derived from the vagus nerve (p. 25).
- The *sympathetic supply* (tachycardic and positively inotropic effect): is derived from the cervical and upper thoracic sympathetic ganglia by way of superficial and deep cardiac plexuses (p. 25).



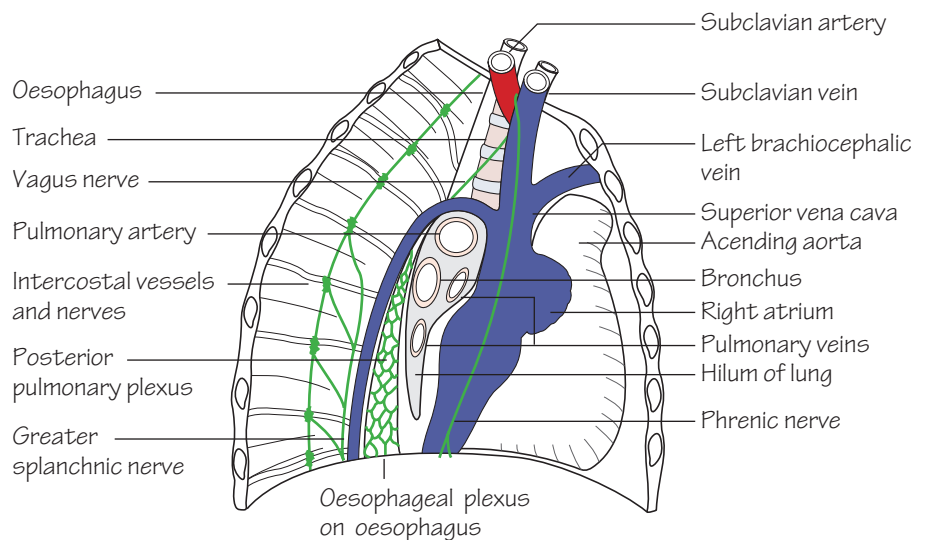
# 9 The nerves of the thorax

**Fig.9.1**  
The course and distribution of the right phrenic nerve



**Fig.9.2**  
The structures on the left side of the mediastinum. They are all covered with the mediastinal pleura

**Fig.9.3**  
The structures on the right side of the mediastinum



## The phrenic nerves

The phrenic nerves arise from the C3, C4 and C5 nerve roots in the neck.

- The *right phrenic nerve* (Fig. 9.1) descends along a near vertical path, anterior to the lung root, lying on sequentially: the right brachiocephalic vein, the superior vena cava, and the right atrium before passing to the inferior vena caval opening in the diaphragm (T8). Here the right phrenic enters the caval opening and immediately penetrates the diaphragm which it supplies.
- The *left phrenic nerve* (Fig. 9.2) descends alongside the left subclavian artery. On the arch of the aorta it passes over the left superior intercostal vein to descend in front of the left lung root onto the pericardium overlying the left ventricle. The left phrenic then pierces the muscular diaphragm as a solitary structure. Note: the phrenic nerves do not pass beyond the undersurface of the diaphragm.
- The phrenic nerves are composed mostly of motor fibres which supply the diaphragm. However, they also transmit fibres which are sensory to the fibrous pericardium, mediastinal pleura and peritoneum as well as the central part of the diaphragm.

*Irritation of the diaphragmatic peritoneum is usually referred to the C4 dermatome. Hence, upper abdominal pathology such as a perforated duodenal ulcer often results in pain felt at the shoulder tip.*

## The vagi

The vagi are the 10th cranial nerves (p. 145).

- The *right vagus nerve* (Figs 9.3 and 3.2) descends adherent to the thoracic trachea prior to passing behind the lung root to form the posterior pulmonary plexus. It finally reaches the lower oesophagus where it forms an oesophageal plexus with the left vagus. From this plexus, anterior and posterior vagal trunks descend (carrying fibres from both left and right vagi) on the oesophagus to pass into the abdomen through the oesophageal opening in the diaphragm at the level of T10.
- The *left vagus nerve* (Fig. 9.2) crosses the arch of the aorta and its branches. It is itself crossed here by the left superior intercostal vein. Below, it descends behind the lung root to reach the oesophagus where it contributes to the oesophageal plexus mentioned above (see Fig. 3.2).

## Vagal branches

- The *left recurrent laryngeal nerve* arises from the left vagus below the arch of the aorta. It hooks around the ligamentum arteriosum and ascends in the groove between the trachea and the oesophagus to reach the larynx (p. 139).
- The *right recurrent laryngeal nerve* arises from the right vagus in the neck and hooks around the right subclavian artery prior to ascending in the groove between the trachea and the oesophagus before finally reaching the larynx.

- The recurrent laryngeal nerves supply the mucosa of the upper trachea and oesophagus as well as providing a motor supply to all of the muscles of the larynx (except cricothyroid) and sensory fibres to the lower larynx.
- The vagi also contribute branches to the cardiac and pulmonary plexuses.

## The thoracic sympathetic trunk (Figs 9.2 and 9.3, and Chapter 53)

- The *thoracic sympathetic chain* is a continuation of the cervical chain. It descends in the thorax behind the pleura immediately lateral to the vertebral bodies and passes under the medial arcuate ligament of the diaphragm to continue as the *lumbar sympathetic trunk*.
- The thoracic chain bears a ganglion for each spinal nerve; the first frequently joins the inferior cervical ganglion to form the *stellate ganglion*. Each ganglion receives a white ramus communicans containing preganglionic fibres from its corresponding spinal nerve and sends back a grey ramus, bearing postganglionic fibres.

*Upper limb sympathectomy is used for the treatment of hyperhidrosis and Raynaud syndrome. Surgical sympathectomy involves excision of part of the thoracic sympathetic chain (usually for two interspaces) below the level of the stellate ganglion. The latter structure must be identified on the neck of the 1st rib.*

## Branches:

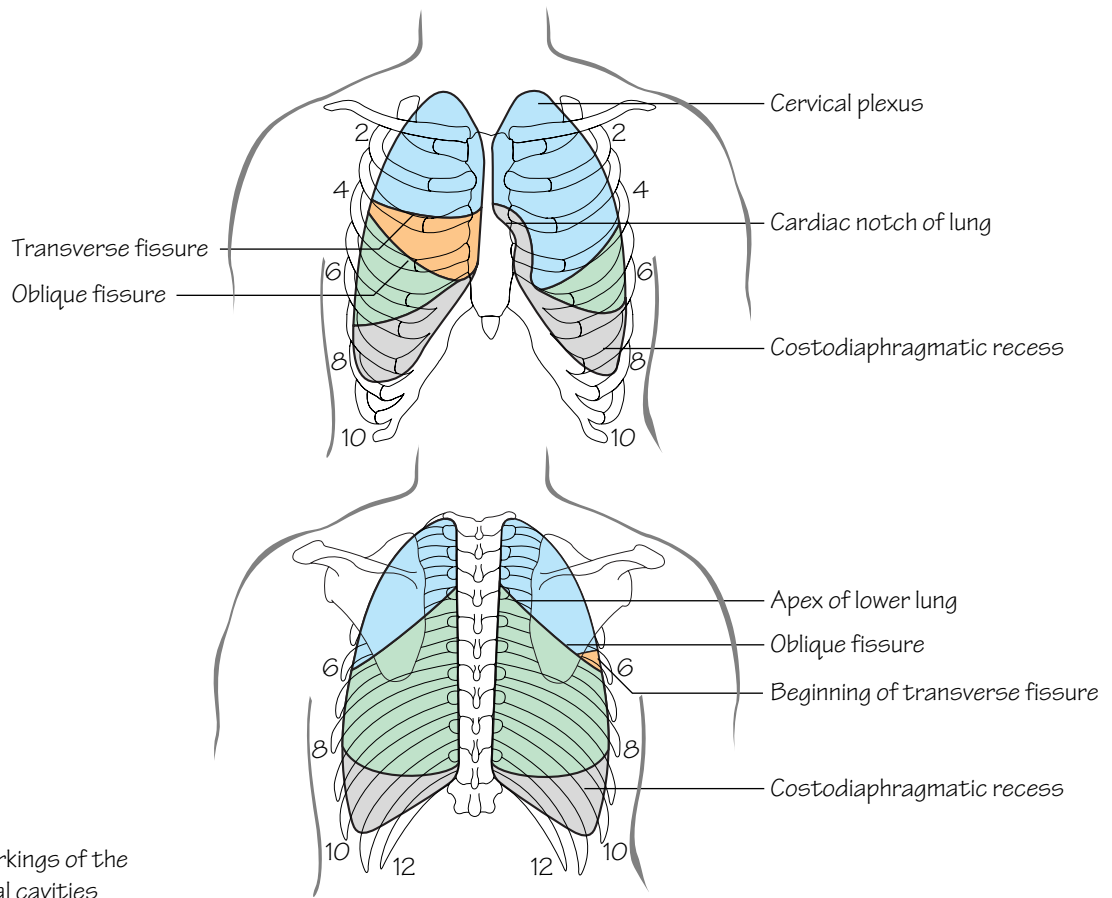
- Sympathetic fibres are distributed to the skin with each of the thoracic spinal nerves.
- Postganglionic fibres from T1–5 are distributed to the thoracic viscera—the heart and great vessels, the lungs and the oesophagus.
- Mainly preganglionic fibres from T5–12 form the *splanchnic nerves*, which pierce the crura of the diaphragm and pass to the coeliac and renal ganglia from which they are relayed as postganglionic fibres to the abdominal viscera (cf. fibres to the suprarenal medulla which are preganglionic). These splanchnic nerves are the: *greater splanchnic* (T5–10), *lesser splanchnic* (T10–11) and *lowest splanchnic* (T12). They lie medial to the sympathetic trunk on the bodies of the thoracic vertebrae and are quite easily visible through the parietal pleura.

## The cardiac plexus

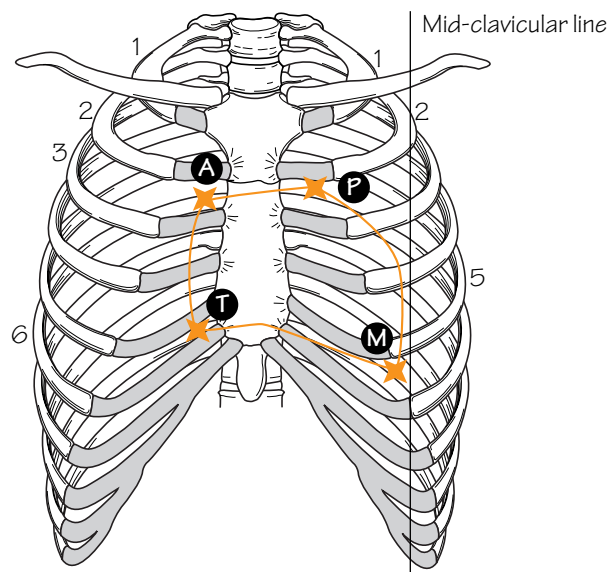
This plexus is for descriptive purposes divided into superficial and deep parts. It consists of sympathetic and parasympathetic efferents as well as afferents.

- Cardiac branches from the plexus supply the heart where they: accompany coronary arteries for vasomotor control and supply the sino-atrial and atrioventricular nodes for cardio-inhibitory and cardio-acceleratory purposes.
- Pulmonary branches supply the bronchial wall smooth muscle (controlling diameter) and pulmonary blood vessels for vasomotor control.

# 10 Surface anatomy of the thorax



**Fig.10.1**  
The surface markings of the lungs and pleural cavities



**Fig.10.2**  
The surface markings of the heart. The areas of auscultation for the aortic, pulmonary, mitral and tricuspid valves are indicated by letters

## The anterior thorax

Landmarks of the anterior thorax include:

- The *angle of Louis (sternal angle)*: formed by the joint between the manubrium and body of the sternum. It is an important landmark as the 2nd costal cartilages articulate on either side and by following this line onto the 2nd rib, further ribs and intercostal spaces can be identified. The sternal angle corresponds to a horizontal point level with the intervertebral disc between T4 and T5.
- The *suprasternal notch*: situated in the midline between the medial ends of the clavicles and above the upper edge of the manubrium.
- The *costal margin*: formed by the lower borders of the cartilages of the 7th, 8th, 9th and 10th ribs and the ends of the 11th and 12th ribs.
- The *xiphisternal joint*: formed by the joint between the body of the sternum and xiphisternum.

## The posterior thorax

Landmarks of the posterior thorax include:

- The first palpable spinous process is that of C7 (*vertebra prominens*). C1–6 vertebrae are covered by the thick ligamentum nuchae. The spinous processes of the thoracic vertebrae can be palpated and counted in the midline posteriorly.
- The scapula is located on the upper posterior chest wall. In slim subjects the superior angle, inferior angle, spine and medial (vertebral) border of the scapula are easily palpable.

## Lines of orientation

These are imaginary vertical lines used to describe locations on the chest wall. These include:

- The *mid-clavicular line*: a vertical line from the midpoint of the clavicle downwards.
- The *anterior and posterior axillary lines*: from the anterior and posterior axillary folds, respectively, vertically downwards.
- The *mid-axillary line*: from the midpoint between anterior and posterior axillary lines vertically downwards.

## Vertebral levels

Palpable bony prominences can be used to identify the location of important underlying structures. The following bony landmarks and their corresponding vertebral levels are given:

- *Suprasternal notch*: T2/3.
- *Sternal angle (angle of Louis)*: T4/5.
- *Superior angle of the scapula*: T2.
- *Inferior angle of the scapula*: T8.
- *Xiphisternal joint*: T9.
- *Subcostal plane (lowest part of the costal margin)*: L3.

## The surface markings of thoracic structures

### The trachea

The trachea commences at the lower border of the cricoid cartilage (C6 vertebral level). It runs downwards in the midline and ends slightly to the right by bifurcating into the left and right main bronchi. The bifurcation occurs at the level of the sternal angle (T4/5).

### The pleura (Fig. 10.1)

The apex of the pleura projects about 2.5 cm above the medial third of the clavicle. The lines of pleural reflection pass behind the sternoclavicular joints to meet in the midline at the level of the sternal angle. The right pleura then passes downwards to the 6th costal cartilage. The left

pleura passes laterally for a small distance at the 4th costal cartilage and descends vertically lateral to the sternal border to the 6th costal cartilage. From these points both pleurae pass posteriorly and in so doing cross the 8th rib in the mid-clavicular line, the 10th rib in the mid-axillary line and finally reach the level of the 12th rib posteriorly.

### The lungs (Fig. 10.1)

The apex and mediastinal border of the right lung follow the pleural outline. In mid-inspiration the right lung lower border crosses the 6th rib in the mid-clavicular line, the 8th rib in the mid-axillary line and reaches the level of the 10th rib posteriorly. The left lung borders are similar to those of the right except that the mediastinal border arches laterally (the cardiac notch) but then resumes the course mentioned above.

- The *oblique fissure*: is represented by an oblique line drawn from a point 2.5 cm lateral to the 5th thoracic spinous process to the 6th costal cartilage anteriorly. The oblique fissures separate the lungs into upper and lower lobes.
- The *transverse fissure*: is represented by a line drawn horizontally from the 4th costal cartilage to a point where it intersects the oblique fissure. The fissure separates the upper and middle lobes of the right lung.

### The heart

- The borders of the heart are illustrated by joining the four points shown (Fig. 10.2).
- The apex of the left ventricle corresponds to where the apex beat is palpable. The surface marking for the apex beat is in the 5th intercostal space in the mid-clavicular line.
- See Fig. 10.2 for optimal sites of valvular auscultation.

### The great vessels

- The *aortic arch*: arches antero-posteriorly behind the manubrium. The highest point of the arch reaches the midpoint of the manubrium.
- The *brachiocephalic artery* and *left common carotid artery*: ascend posterior to the manubrium.
- The *brachiocephalic veins*: are formed by the confluence of the internal jugular and subclavian veins. This occurs posterior to the sternoclavicular joints.
- The *superior vena cava*: is formed by the confluence of the left and right brachiocephalic veins between the 2nd and 3rd right costal cartilages at the right border of the sternum.

### The breast

The base of the breast (p. 69) is constant, overlying the 2nd to the 6th ribs and costal cartilages anteriorly and from the lateral border of the sternum to the mid-axillary line. The position of the nipple is variable in the female but in the man it is usually in the 4th intercostal space in the mid-clavicular line.

### The internal thoracic vessels

These arteries and veins descend 1 cm lateral to the edge of the sternum.

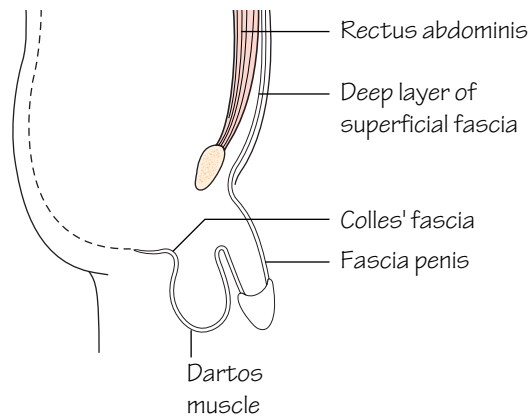
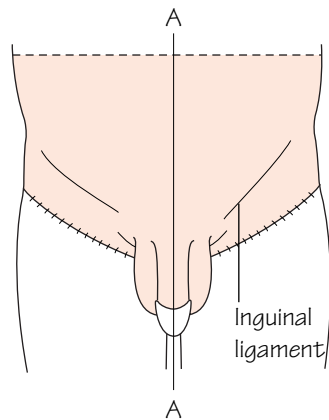
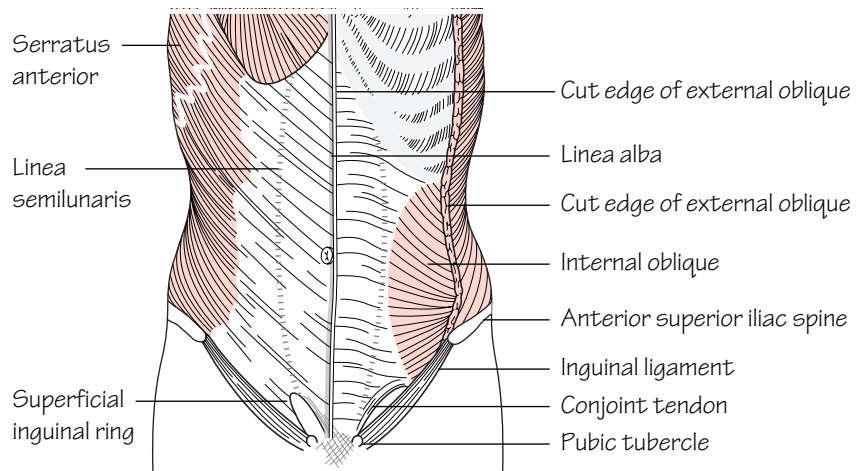
### The diaphragm

In mid-inspiration the highest part of the right dome reaches as far as the upper border of the 5th rib in the mid-clavicular line. The left dome reaches only the lower border of the 5th rib.

# 11 The abdominal wall

**Fig.11.1**

Two muscles of the anterior abdominal wall.  
The external oblique (on the right) and the internal oblique (on the left)

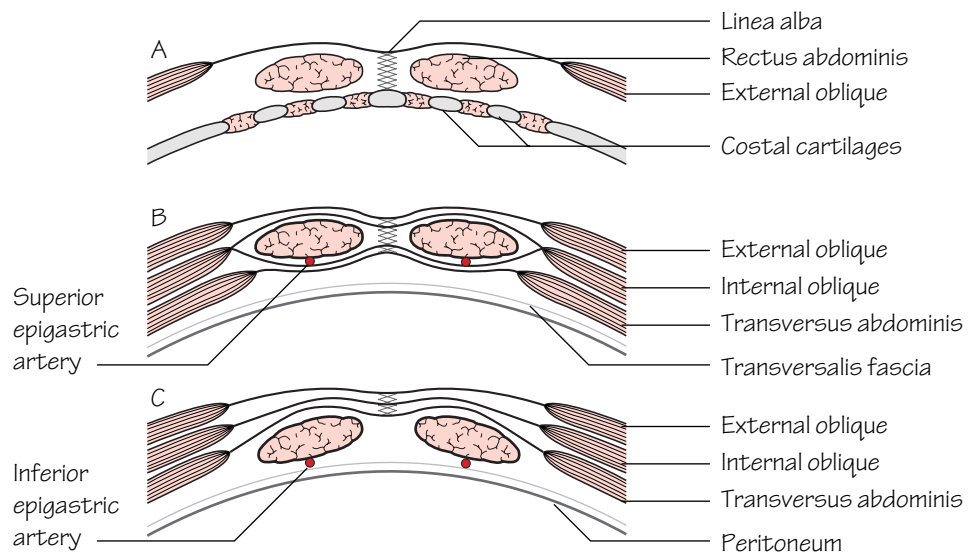


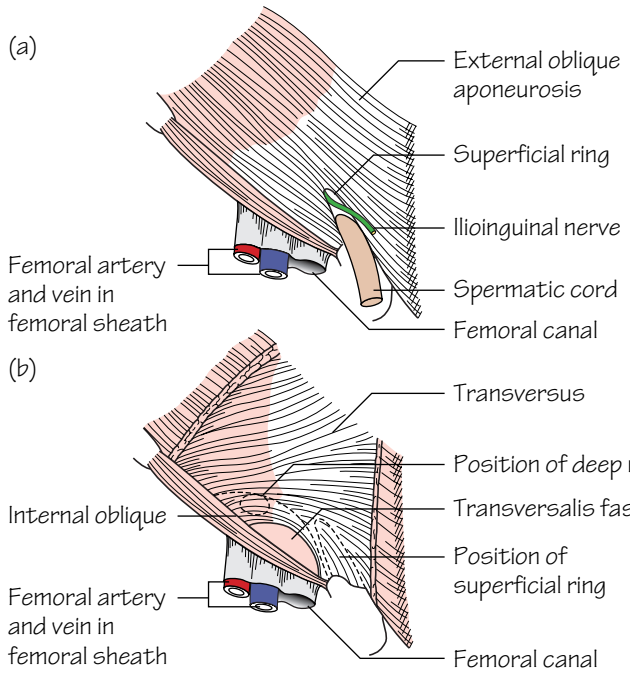
**Fig.11.2**

The fibrous layer of superficial fascia can be likened to a pair of bathing trunks sewn to the thigh below the inguinal ligament and clinging to the penis and scrotum (except for the glans)

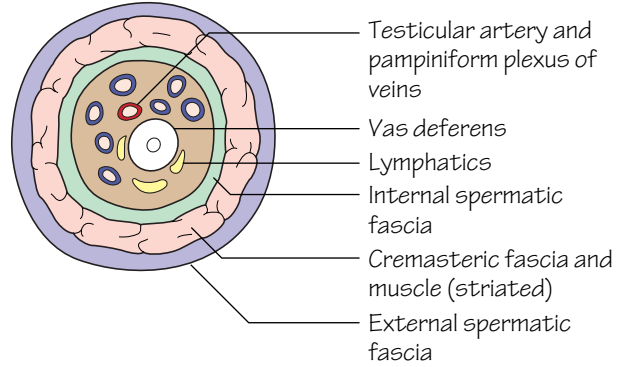
**Fig.11.3**

Transverse sections through the rectus sheath.  
A: above the costal margin  
B: above the umbilicus  
C: above the pubic symphysis

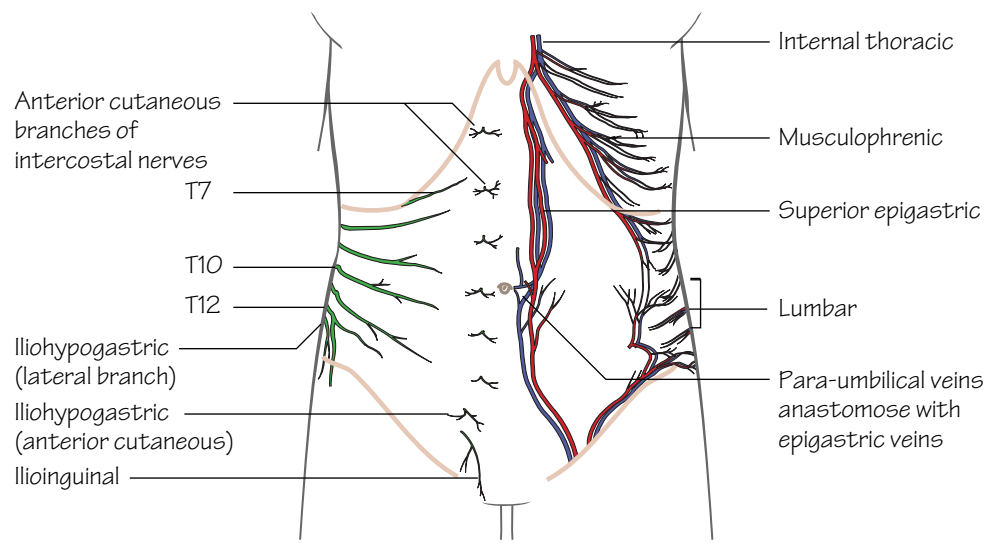




**Fig.11.4**  
The inguinal canal.  
(a) The superficial inguinal ring. The external spermatic fascia has been removed  
(b) After removal of the external oblique



**Fig.11.5**  
A schematic cross section through the spermatic cord



**Fig.11.6**  
The nerves and vessels of the abdominal wall



The anterior abdominal wall comprises: skin, superficial fascia, abdominal muscles (and their respective aponeuroses), transversalis fascia, extraperitoneal fat, and parietal peritoneum.

### Skin (Fig. 11.6)

The skin of the abdominal wall is innervated by the anterior rami of the lower six thoracic intercostal and iliohypogastric (L1) nerves.

### Fascia (Fig. 11.2)

There is no deep fascia in the trunk. The superficial fascia is composed of two layers:

- A superficial fatty layer—*Camper's fascia*—which is continuous with the superficial fat over the rest of the body.
- A deep fibrous (membranous) layer—*Scarpa's fascia*—which fades above and laterally but below blends with the fascia lata of the thigh just below the inguinal ligament and extends into: the penis as a tubular sheath; the wall of the scrotum and posteriorly; the perineum where it fuses with the perineal body and posterior margin of the perineal membrane. It fuses laterally with the pubic arch. The fibrous fascial layer is referred to as *Colles' fascia* in the perineum.

### Muscles of the anterior abdominal wall (Fig. 11.1)

These comprise: *external oblique*, *internal oblique*, *transversus abdominis*, *rectus abdominis* and *pyramidalis* (see Muscle index, p. 162).

As in the intercostal space, the neurovascular structures pass in the neurovascular plane between internal oblique and transversus muscle layers.

### The rectus sheath (Fig. 11.3)

The rectus sheath encloses the rectus muscles. It contains also the superior and inferior epigastric vessels and anterior rami of the lower six thoracic nerves.

The sheath is made up from the aponeuroses of the muscles of the anterior abdominal wall. The *linea alba* represents the fusion of the aponeuroses in the midline. Throughout the major part of the length of the rectus the aponeuroses of external oblique and the anterior layer of internal oblique lie in front of the muscle and the posterior layer of internal oblique and transversus behind. The composition of the sheath is, however, different above the costal margin and above the pubic symphysis:

- *Above the costal margin*: only the external oblique aponeurosis is present and forms the anterior sheath.
- *Above the pubic symphysis*: about halfway between the umbilicus and pubic symphysis the layers passing behind the rectus muscle gradually fade out and from this point all aponeuroses pass anterior to the rectus muscle, leaving only the transversalis fascia.

The lateral border of the rectus—the *linea semilunaris*—can usually be identified in thin subjects. It crosses the costal margin in the transpyloric plane.

Three tendinous intersections firmly attach the anterior sheath wall to the muscle itself. They are situated at the level of the xiphoid, the umbilicus and one between these two. These give the abdominal 'six-pack' appearance in muscular individuals.

### Arteries of the abdominal wall (Fig. 11.6)

These include the *superior* and *inferior epigastric arteries* (branches of the internal thoracic and external iliac arteries, respectively) and the

*deep circumflex iliac artery* (a branch of the external iliac artery) anteriorly. The two lower *intercostal* and four *lumbar* arteries supply the wall posterolaterally.

### Veins of the abdominal wall (Fig. 11.6)

The abdominal wall is a site of porto-systemic anastomosis. The *lateral thoracic*, *lumbar* and *superficial epigastric* tributaries of the systemic circulation anastomose around the umbilicus with the *para-umbilical* veins which accompany the ligamentum teres and drain into the portal circulation.

### Lymph drainage of the abdominal wall

See p. 35.

### The inguinal canal (Fig. 11.4)

The canal is approximately 4 cm long and allows the passage of the spermatic cord (round ligament in the female) through the lower abdominal wall. The canal passes obliquely from the *deep inguinal ring* in a medial direction to the *superficial inguinal ring*.

- **The deep ring**: is an opening in the transversalis fascia. It lies halfway between the anterior superior iliac spine and the pubic tubercle. The inferior epigastric vessels pass medial to the deep ring.
- **The superficial ring**: is not a ring but a triangular-shaped defect in the external oblique aponeurosis lying above and medial to the pubic tubercle.

### The walls of the inguinal canal (Fig. 11.4)

- **Anterior**: external oblique covers the length of the canal anteriorly. It is reinforced in its lateral third by internal oblique.
- **Superior**: internal oblique arches posteriorly to form the roof of the canal.
- **Posterior**: transversalis fascia forms the lateral part of the posterior wall. The conjoint tendon (the combined common insertion of the internal oblique and transversus into the pectineal line) forms the medial part of the posterior wall.
- **Inferior**: the inguinal ligament.

### Contents of the inguinal canal

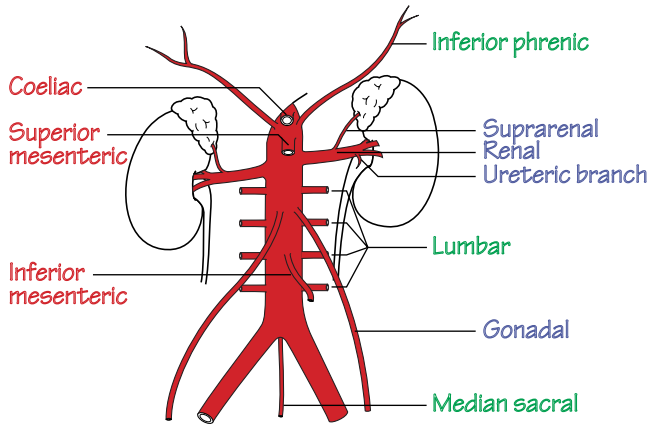
- The spermatic cord (or round ligament in the female).
- The ilioinguinal nerve (L1).

### The spermatic cord (Fig. 11.5)

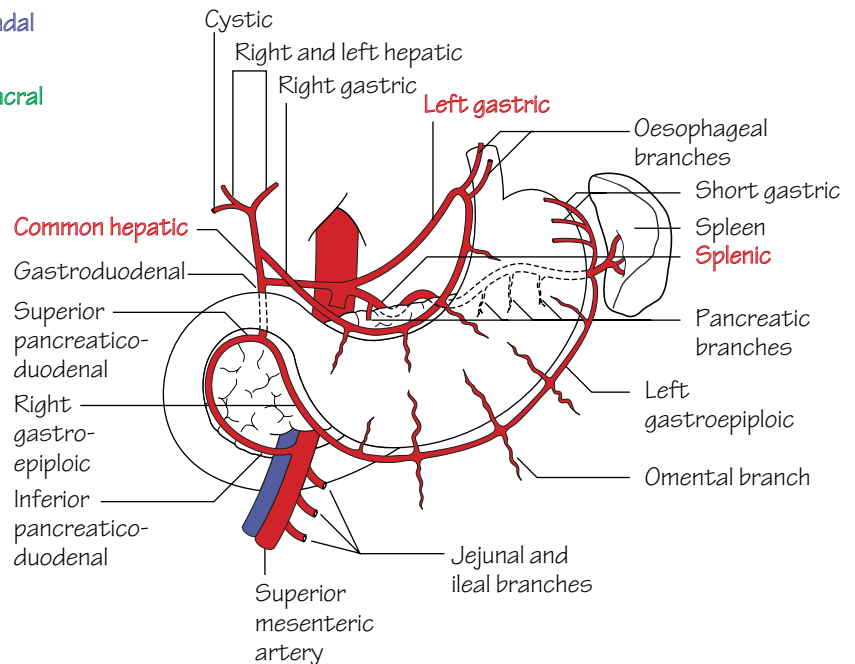
The spermatic cord is covered by three layers which arise from the layers of the lower abdominal wall as the cord passes through the inguinal canal. These are the:

- **External spermatic fascia**: from the external oblique aponeurosis.
  - **Cremasteric fascia and muscle**: from the internal oblique aponeurosis.
  - **Internal spermatic fascia**: from the transversalis fascia.
- The contents of the spermatic cord include the:
- **Ductus (vas) deferens** (or **round ligament**).
  - **Testicular artery**: a branch of the abdominal aorta.
  - **Pampiniform plexus of veins**: these coalesce to form the testicular vein in the region of the deep ring.
  - **Lymphatics**: from the testis and epididymis draining to the pre-aortic nodes.
  - **Autonomic nerves**.

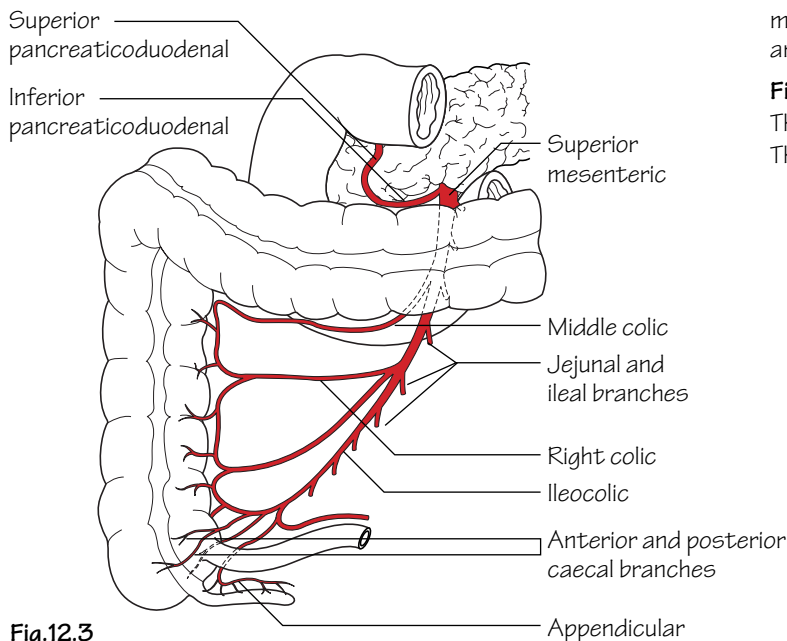
# 12 The arteries of the abdomen



**Fig.12.1**  
The abdominal aorta and its branches.  
Red labels: ventral branches  
Blue labels: lateral branches  
Green labels: branches to body wall

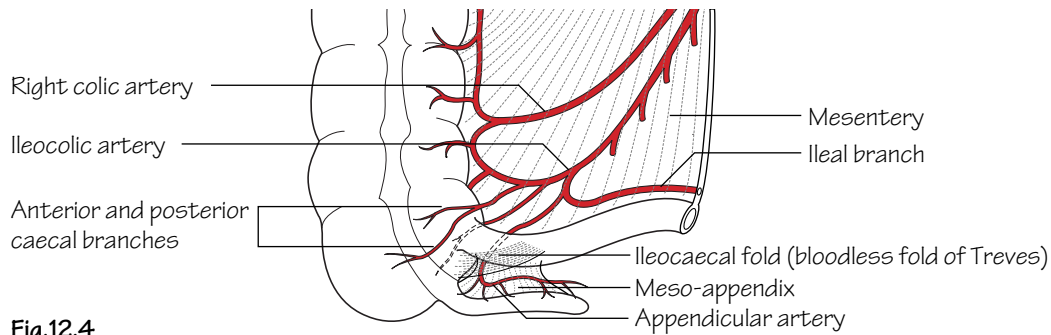


**Fig.12.2**  
The coeliac artery and its branches.  
The three primary branches are labelled in red

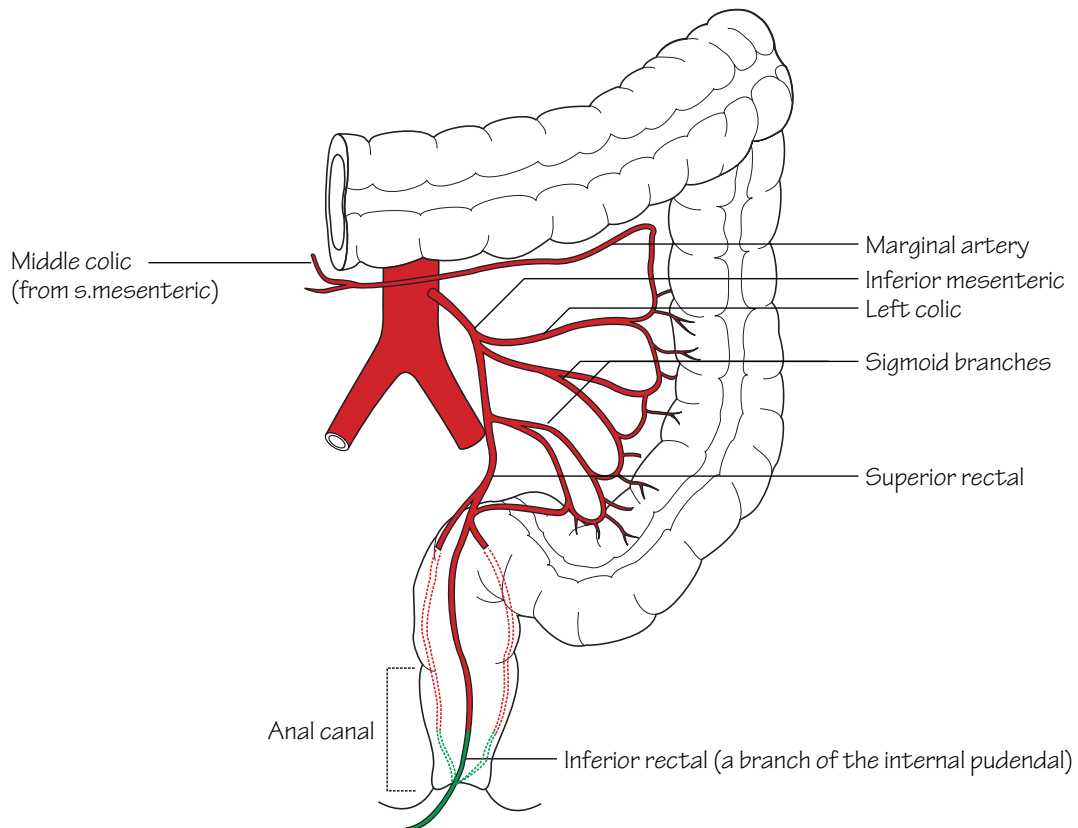


**Fig.12.3**  
The superior mesenteric artery and its branches





**Fig.12.4**  
The blood supply of the appendix



**Fig.12.5**  
The inferior mesenteric artery and its branches.  
Note the anastomosis with the inferior rectal artery (green) halfway down the anal canal

### The abdominal aorta (Fig. 12.1)

The abdominal aorta is a continuation of the thoracic aorta as it passes under the median arcuate ligament of the diaphragm. It descends in the retroperitoneum and ultimately bifurcates into left and right common iliac arteries to the left of the midline at the level of L4. The vertebral bodies and intervertebral discs lie behind the aorta whilst anteriorly, from above downwards, lie its anterior branches, the coeliac plexus, the lesser sac, the body of the pancreas, the third part of the duodenum, and the parietal peritoneum. The main relation to the right of the abdominal aorta is the inferior vena cava whilst to the left lie the duodenojejunal junction and inferior mesenteric vein.

The main abdominal branches of the abdominal aorta include the:

- **Coeliac trunk:** supplies the embryonic foregut: from the lower third of the oesophagus to the second part of the duodenum.
- **Superior mesenteric artery:** supplies the midgut: from the second part of the duodenum to the distal transverse colon.
- **Renal arteries.**
- **Gonadal arteries.**
- **Inferior mesenteric artery:** supplies the hindgut: from the distal transverse colon to the upper half of the anal canal.

### The coeliac trunk (Fig. 12.2)

This trunk arises from the aorta at the level of T12/L1 and after a short course divides into three terminal branches. These include the:

- **Left gastric artery:** passes upwards to supply the lower oesophagus by branches which ascend through the oesophageal hiatus in the diaphragm. The left gastric then descends in the lesser omentum along the lesser curve of the stomach which it supplies.
- **Splenic artery:** passes along the superior border of the pancreas in the posterior wall of the lesser sac to reach the upper pole of the left kidney. From here it passes to the hilum of the spleen in the lienorenal ligament. The splenic artery also gives rise to *short gastric branches*, which supply the stomach fundus, and a *left gastroepiploic branch* which passes in the gastrosplenic ligament to reach and supply the greater curve of the stomach.
- **Hepatic artery:** descends to the right towards the first part of the duodenum in the posterior wall of the lesser sac. It then passes between the layers of the free border of the lesser omentum which conveys it to the porta hepatis in close relation to the portal vein and bile duct (these structures together constitute the anterior margin of the epiploic foramen). Before reaching the porta hepatis it divides into *right* and *left hepatic arteries* and from the right branch the *cystic artery* is usually given off. Prior to its ascent towards the porta hepatis the hepatic artery gives rise to *gastrooduodenal* and *right gastric branches*. The latter passes along the lesser curve of the stomach to supply it. The former passes behind the first part of the duodenum and then branches further into *superior pancreaticoduodenal* and *right gastroepiploic branches*. The right gastroepiploic branch runs along the lower part of the greater curvature to supply the stomach.

### The superior mesenteric artery (Fig. 12.3)

The superior mesenteric artery arises from the abdominal aorta at the level of L1. From above downwards, it passes over the left renal vein behind the neck of the pancreas, over the uncinate process and anterior to the third part of the duodenum. It then passes obliquely downwards and towards the right iliac fossa between the layers of the mesentery of the small intestine where it divides into its terminal branches. The branches of the superior mesenteric artery include the:

- **Inferior pancreaticoduodenal artery:** supplies the lower half of the duodenum and pancreatic head.
- **Ileocolic artery:** passes in the root of the mesentery over the right ureter and gonadal vessels to reach the caecum where it divides into terminal *caecal* and *appendicular branches* (Fig. 12.4).
- **Jejunal and ileal branches:** a total of 12–15 branches arise from the left side of the artery. These branches divide and reunite within the small bowel mesentery to form a series of arcades which then give rise to small straight terminal branches which supply the gut wall.
- **Right colic artery:** passes horizontally in the posterior abdominal wall to supply the ascending colon.
- **Middle colic artery:** courses in the transverse mesocolon to supply the proximal two-thirds of the transverse colon.

### The renal arteries

These arise from the abdominal aorta at the level of L2.

### The gonadal arteries (ovarian or testicular)

These arteries arise from below the renal arteries and descend obliquely on the posterior abdominal wall to reach the ovary in the female, or pass through the inguinal canal in the male to reach the testis.

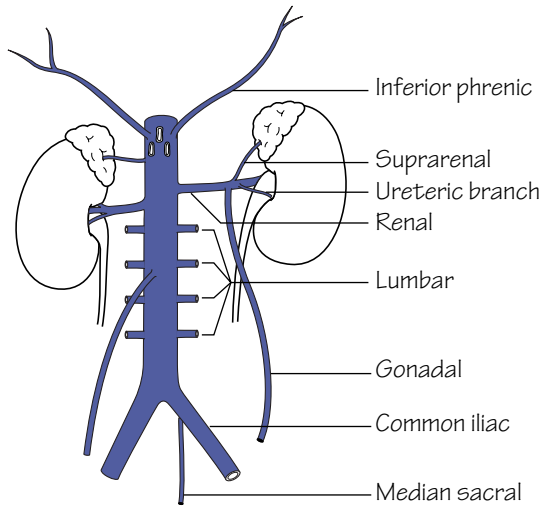
### The inferior mesenteric artery (Fig. 12.5)

The inferior mesenteric artery arises from the abdominal aorta at the level of L3. It passes downwards and to the left and crosses the left common iliac artery where it changes its name to the *superior rectal artery*. Its branches include:

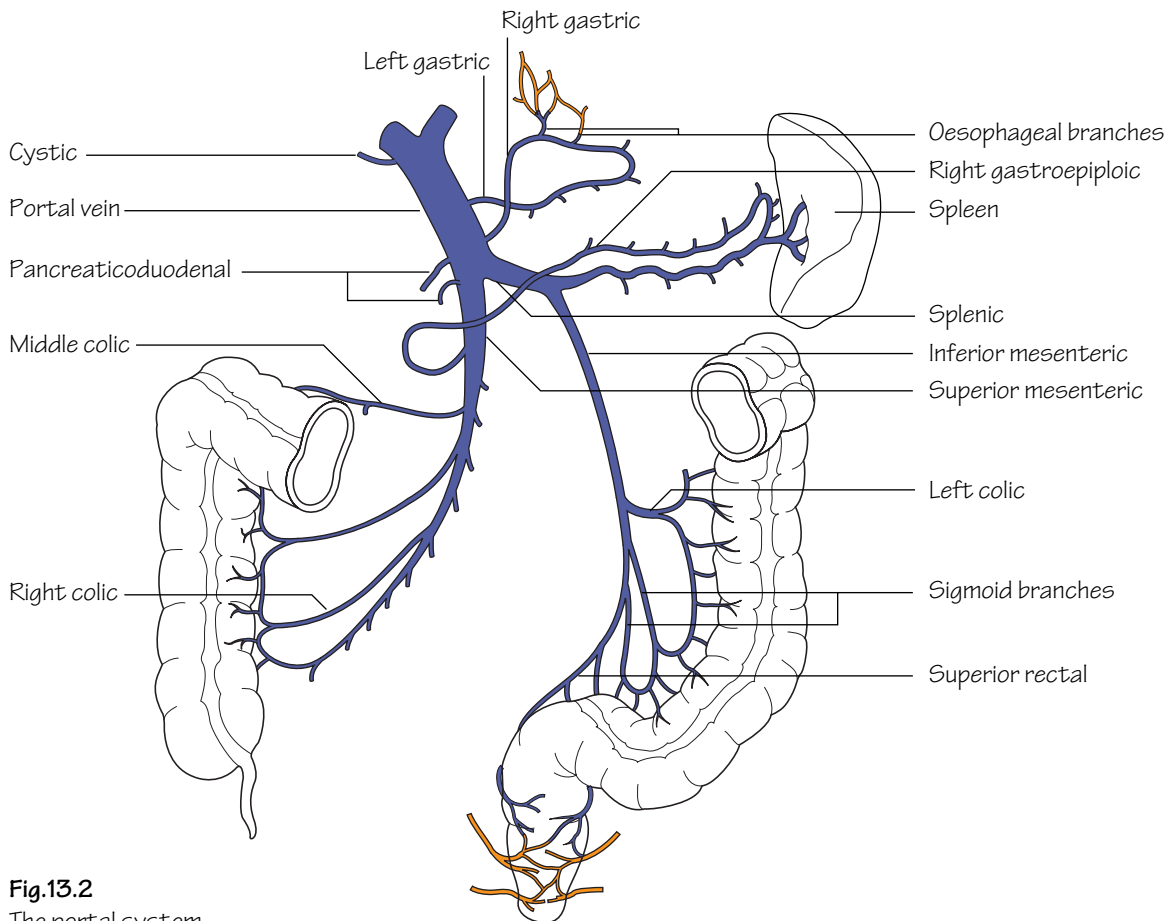
- **The left colic artery:** supplies the distal transverse colon, the splenic flexure and upper descending colon.
- **Two or three sigmoid branches:** pass into the sigmoid mesocolon and supply the lower descending and sigmoid colon.
- **The superior rectal artery:** passes into the pelvis behind the rectum to form an anastomosis with the middle and inferior rectal arteries. It supplies the rectum and upper half of the anal canal.

The *marginal artery (of Drummond)* is an anastomosis of the colic arteries at the margin of the large intestine. This establishes a strong collateral circulation throughout the colon.

# 13 The veins and lymphatics of the abdomen



**Fig.13.1**  
The inferior vena cava and its tributaries



**Fig.13.2**  
The portal system.  
Note the anastomoses with the systemic system (orange) in the oesophagus and the anal canal

### The portal vein (Fig. 13.2)

The portal venous system receives blood from the length of gut from the lower third of the oesophagus to the upper half of the anal canal as well as the spleen, pancreas and gall-bladder. It serves to transfer blood to the liver where the products of digestion can be metabolized and stored. Blood from the liver ultimately gains access to the inferior vena cava by way of the hepatic veins. The portal vein is formed behind the neck of the pancreas by the union of the superior mesenteric and splenic veins. It passes behind the first part of the duodenum in front of the inferior vena cava and enters the free border of the lesser omentum. The vein then ascends towards the porta hepatis in the anterior margin of the epiploic foramen (of Winslow) in the lesser omentum. At the porta hepatis it divides into right and left branches. The veins that correspond to the branches of the coeliac and superior mesenteric arteries drain into the portal vein or one of its tributaries. The inferior mesenteric vein drains into the splenic vein adjacent to the fourth part of the duodenum.

### Porto-systemic anastomoses

A number of connections occur between the portal and systemic circulations. When the direct pathway through the liver becomes congested (such as in cirrhosis) the pressure within the portal vein rises and under these circumstances the porto-systemic anastomoses form an alternative route for the blood to take. The sites of porto-systemic anastomosis include:

- **The lower oesophagus** (p. 11): formed by tributaries of the left gastric (portal) and oesophageal veins (systemic via the azygos and hemiazygos veins).
- **The anal canal:** formed by the superior rectal (portal) and middle and inferior rectal veins (systemic).
- **The bare area of the liver:** formed by the small veins of the portal system and the phrenic veins (systemic).
- **The periumbilical region:** formed by small paraumbilical veins which drain into the left portal vein and the superficial veins of the anterior abdominal wall (systemic).

### The inferior vena cava (Fig. 13.1)

The inferior vena cava is formed by the union of the common iliac veins in front of the body of L5. It ascends in the retroperitoneum on the right side of the abdominal aorta. Along its course, from below upwards, it forms the posterior wall of the epiploic foramen of Winslow and is embedded in the bare area of the liver in front of the right suprarenal gland. The inferior vena cava passes through the caval opening in the diaphragm at the level of T8 and drains into the right atrium.

### The lymphatic drainage of the abdomen and pelvis

#### The abdominal wall

Lymph from the skin of the anterolateral abdominal wall above the level of the umbilicus drains to the anterior axillary lymph nodes. Efferent lymph from the skin below the umbilicus drains to the superficial inguinal nodes.

#### The lymph nodes and trunks

The two main lymph node groups of the abdomen are closely related to the aorta. These comprise the pre-aortic and para-aortic groups.

- The *pre-aortic nodes* are arranged around the three ventral branches of the aorta and consequently receive lymph from the territories that are supplied by these branches. This includes most of the gastrointestinal tract, liver, gall-bladder, spleen and pancreas. The efferent vessels from the pre-aortic nodes coalesce to form a variable number of *intestinal trunks* which deliver the lymph to the cisterna chyli.
- The *para-aortic nodes* are arranged around the lateral branches of the aorta and drain lymph from their corresponding territories, i.e. the kidneys, adrenals, gonads, and abdominal wall as well as the common iliac nodes. The efferent vessels from the para-aortic nodes coalesce to form a variable number of *lumbar trunks* which deliver the lymph to the cisterna chyli.

#### Cisterna chyli

The cisterna chyli is a lymphatic sac that lies anterior to the bodies of the 1st and 2nd lumbar vertebrae. It is formed by the confluence of the intestinal trunks, the lumbar trunks and lymphatics from the lower thoracic wall. It serves as a receptacle for lymph from the abdomen and lower limbs which is then relayed to the thorax by the thoracic duct (p. 11).

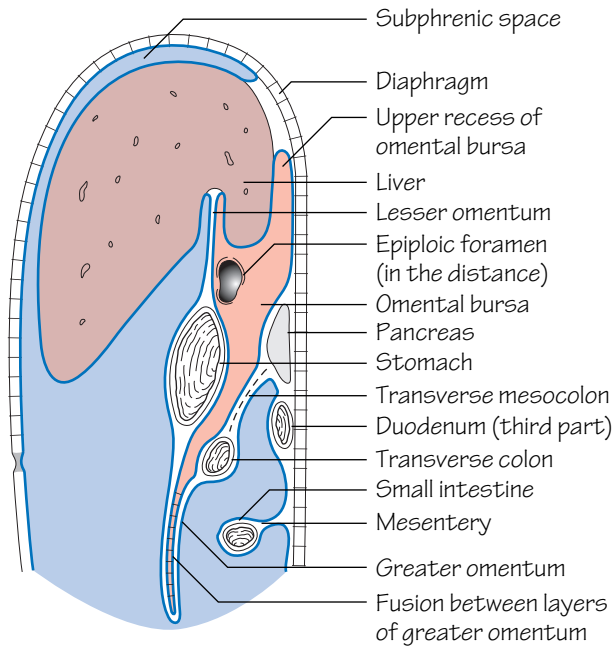
#### The lymphatic drainage of the stomach

Lymph from the stomach drains to the coeliac nodes. For the purposes of description, the stomach can be divided into four quarters where lymph drains to the nearest appropriate group of nodes.

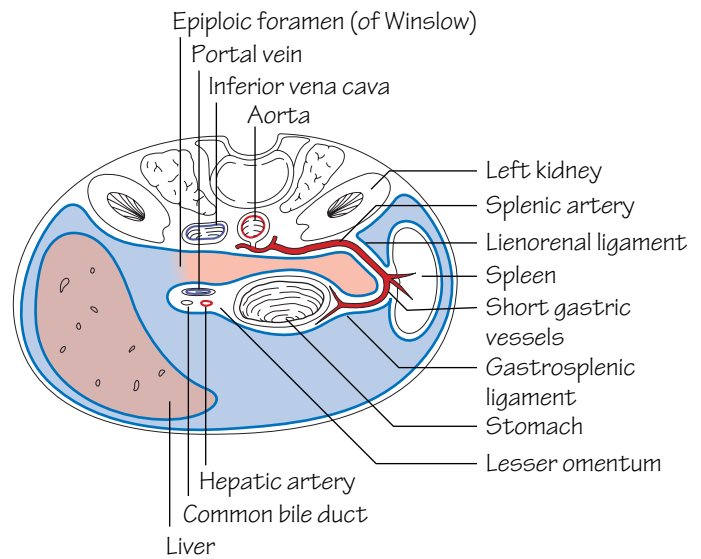
#### The lymphatic drainage of the testes

Lymph from the skin of the scrotum and the tunica albuginea drains to the superficial inguinal nodes. Lymph from the testes, however, drains along the course of the testicular artery to the para-aortic group of nodes. *Hence, a malignancy of the scrotal skin might result in palpable enlargement of the superficial inguinal nodes whereas testicular tumours metastasize to the para-aortic nodes.*

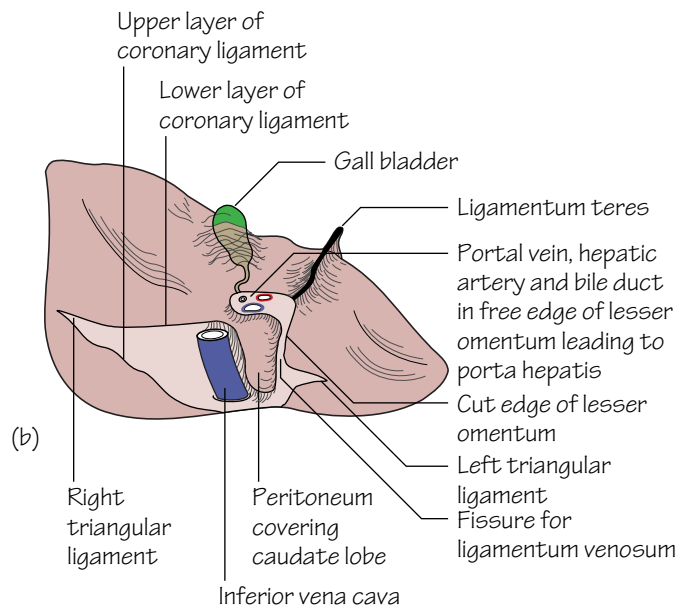
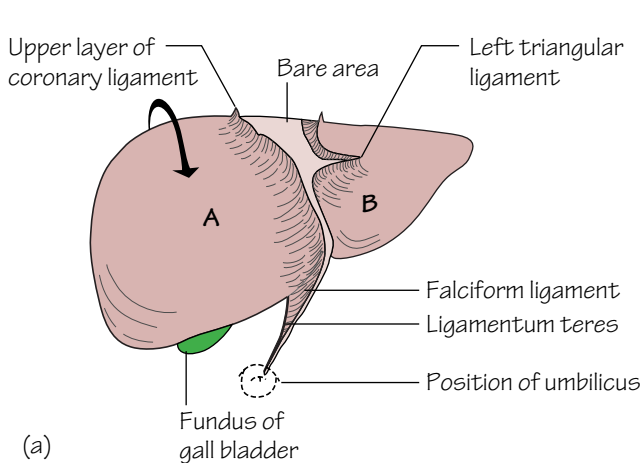
# 14 The peritoneum



**Fig.14.1**  
A vertical section through the abdomen to show the peritoneal relations.  
Lesser sac █  
Greater sac █



**Fig.14.2**  
A horizontal section through the abdomen.  
Note how the epiploic foramen lies between two major veins



**Fig.14.3**  
The peritoneal relations of the liver  
(a) Seen from in front  
(b) The same liver rotated in the direction of the arrow to show the upper and posterior surfaces.  
The narrow spaces between the liver and the diaphragm labelled A and B are the right and left subphrenic spaces

## The mesenteries and layers of the peritoneum

The transverse colon, stomach, spleen and liver each have attached to them *two* ‘mesenteries’—double layers of peritoneum containing arteries and their accompanying veins, nerves and lymphatics—while the small intestine and sigmoid colon have only one. All the other viscera are retroperitoneal. The mesenteries and their associated arteries are as follows:

- **The colon** (Fig. 14.1): (1) The *transverse mesocolon* (the middle colic artery). (2) The posterior two layers of the *greater omentum*.
- **The stomach** (Fig. 14.1): (1) The *lesser omentum* (the left and right gastric arteries and in its free border, the hepatic artery, portal vein and bile duct). (2) The anterior two layers of the *greater omentum* (the right and left gastroepiploic arteries and their omental branches).
- **The spleen** (Fig. 14.2): (1) The *lienorenal ligament* (the splenic artery). (2) The *gastrosplenic ligament* (the short gastric and left gastroepiploic arteries).
- **The liver** (Fig. 14.3): (1) The *falciform ligament* and the two layers of the *coronary ligament* with their sharp edges, the *left and right triangular ligaments*. This mesentery is exceptional in that the layers of the coronary ligament are widely separated so that the liver has a *bare area* directly in contact with the diaphragm (the obliterated umbilical artery in the free edge of the falciform ligament and numerous small veins in the bare area, p. 35). (2) The *lesser omentum* (already described).
- **The small intestine** (Fig. 14.1): (1) The *mesentery of the small intestine* (the superior mesenteric artery and its branches).
- **The sigmoid colon**: (1) The *sigmoid mesocolon* (the sigmoid arteries and their branches).

## The peritoneal cavity (Figs 14.1 and 14.2)

- The complications of the peritoneal cavity may best be described by starting at the *transverse mesocolon*. Its two layers are attached to the anterior surface of the pancreas, the second part of the duodenum and the front of the left kidney. They envelop the transverse colon and continue downwards to form the posterior two layers of the *greater omentum*, which hangs down over the coils of the small intestine. They then turn back on themselves to form the anterior two layers of the omentum and these reach the greater curvature of the stomach. The four layers of the omentum are fused and impregnated with fat. The greater omentum plays an important role in limiting the spread of infection in the peritoneal cavity.
- From its attachment to the pancreas, the lower layer of the transverse mesocolon turns downwards to become the parietal peritoneum of the posterior abdominal wall from which it is reflected to form the *mesentery of the small intestine* and the *sigmoid mesocolon*.
- The upper layer of the transverse mesocolon passes upwards to form the parietal peritoneum of the posterior abdominal wall, covering the upper part of the pancreas, the left kidney and its suprarenal, the aorta and the origin of the coeliac artery (the ‘*stomach bed*’). It thus forms the posterior wall of the omental bursa. It then covers the diaphragm and continues onto the anterior abdominal wall.
- From the diaphragm and anterior abdominal wall it is reflected onto the liver to form its ‘mesentery’ in the form of the two layers of the *falciform ligament*. At the liver, the left layer of the falciform ligament folds back on itself to form the sharp edge of the *left triangular liga-*

*ment* while the right layer turns back on itself to form the upper and lower layers of the *coronary ligament* with its sharp-edged *right triangular ligament*. The layers of the coronary ligament are widely separated so that a large area of liver between them—the *bare area*—is directly in contact with the diaphragm. The inferior vena cava is embedded in the bare area (Fig. 14.3).

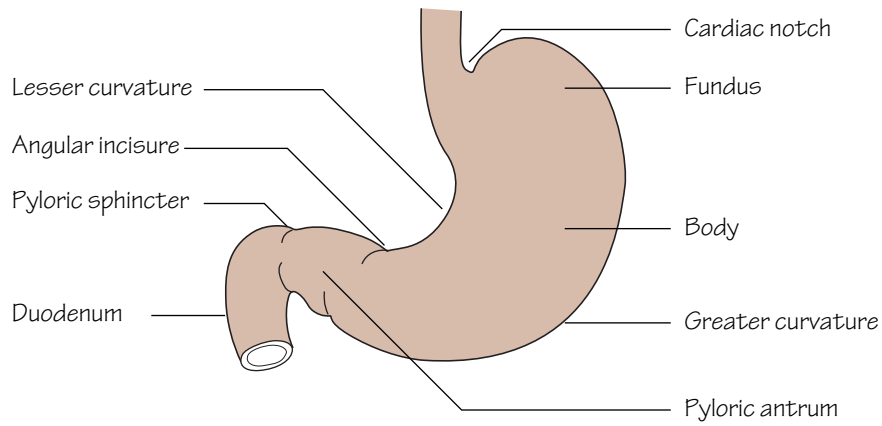
- From the undersurface of the liver another ‘mesentery’ passes from the fissure for the ligamentum venosum to the lesser curvature of the stomach to form the *lesser omentum*.
- The *lesser omentum* splits to enclose the stomach and is continuous with the two layers of the *greater omentum* already described. The lesser omentum has a right free border which contains the portal vein, the hepatic artery and the common bile duct.
- In the region of the spleen there are two more ‘mesenteries’ which are continuous with the lesser and greater omenta. These are the *lienorenal ligament*, a double layer of peritoneum reflected from the front of the left kidney to the hilum of the spleen, and the *gastrosplenic ligament* which passes from the hilum of the spleen to the greater curvature of the stomach (Fig. 14.2).
- The *mesentery of the small intestine* is attached to the posterior abdominal wall from the duodenojejunal flexure to the ileocolic junction.
- The *sigmoid mesocolon* passes from a V-shaped attachment on the posterior abdominal wall to the sigmoid colon.
- The general peritoneal cavity comprises the main cavity—the *greater sac*—and a diverticulum from it—the *omental bursa (lesser sac)*. The omental bursa lies between the stomach and the stomach bed to allow free movement of the stomach. It lies behind the stomach, the lesser omentum and the caudate lobe of the liver and in front of the structures of the stomach bed. The left border is formed by the hilum of the spleen and the lienorenal and gastrosplenic ligaments.
- The communication between the greater and lesser sacs is the *epiploic foramen (foramen of Winslow)*. It lies behind the free border of the lesser omentum and its contained structures, below the caudate process of the liver, in front of the inferior vena cava and above the first part of the duodenum.
- The *subphrenic spaces* are part of the greater sac that lies between the diaphragm and the upper surface of the liver. There are right and left spaces, separated by the falciform ligament.
- In the pelvis the parietal peritoneum covers the upper two-thirds of the rectum whence it is reflected, in the female, onto the posterior fornix of the vagina and the back of the uterus to form the *recto-uterine pouch (pouch of Douglas)*. In the male it passes onto the back of the bladder to form the *rectovesical pouch*.

## The anterior abdominal wall

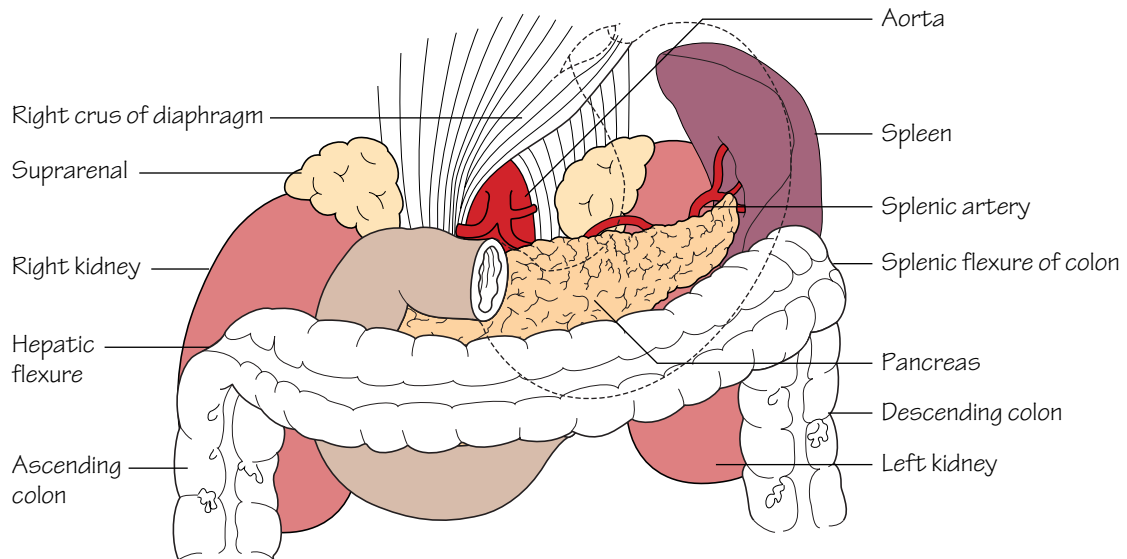
- The peritoneum of the deep surface of the anterior abdominal wall shows a central ridge from the apex of the bladder to the umbilicus produced by the *median umbilical ligament*. This is the remains of the embryonic urachus. Two *medial umbilical ligaments* converge to the umbilicus from the pelvis. They represent the obliterated umbilical arteries of the fetus. The *ligamentum teres* is a fibrous band in the free margin of the falciform ligament. It represents the obliterated left umbilical vein.



# 15 The upper gastrointestinal tract I



**Fig.15.1**  
The subdivisions of the stomach



**Fig.15.2**  
The stomach bed. For more detail see fig.19.1.  
The stomach is outlined but the shape is by no means constant

The embryonic gut is divided into foregut, midgut and hindgut, supplied, respectively, by the coeliac, superior mesenteric and inferior mesenteric arteries. The foregut extends from the oesophagus to the entrance of the common bile duct into the second part of the duodenum. The midgut extends down to two-thirds of the way along the transverse colon. It largely develops outside the abdomen until this congenital 'umbilical hernia' is reduced during the 8th–10th week of gestation. The hindgut extends down to include the upper half of the anal canal.

### The abdominal oesophagus

- The abdominal oesophagus measures approximately 1 cm in length.
- It is accompanied by the anterior and posterior vagal trunks from the left and right vagi and the oesophageal branches of the left gastric artery.
- The lower third of the oesophagus is a site of porto-systemic venous anastomosis. This is formed between tributaries of the left gastric and azygos veins (p. 11).

### The stomach (Figs 15.1 and 15.2)

- The notch on the lesser curve, at the junction of the body and pyloric antrum, is the *incisura angularis*.
- The *pyloric sphincter* controls the release of stomach contents into the duodenum. The sphincter is composed of a thickened layer of circular smooth muscle which acts as an anatomical, as well as physiological, sphincter. The junction of the pylorus and duodenum can be seen externally as a constriction with an overlying vein—the *prepyloric vein (of Mayo)*.
- The *cardiac orifice* represents the point of entry for oesophageal contents into the stomach. The cardiac sphincter acts to prevent reflux of stomach contents into the oesophagus. Unlike the pylorus there is no discrete anatomical sphincter at the cardia; however, multiple factors contribute towards its mechanism. These include: the arrangement of muscle fibres at the cardiac orifice acting as a physiological sphincter; the angle at which the oesophagus enters the stomach producing a valve effect; the right crus of the diaphragm surrounding the oesophagus and compression of the short segment of intra-abdominal oesophagus by increases in intra-abdominal pressure during straining, preventing reflux.
- The *lesser omentum* is attached to the lesser curvature and the *greater omentum* to the greater curvature. The omenta contain the blood and lymphatic supply to the stomach.
- The mucosa of the stomach is thrown into folds—*rugae*.
- **Blood supply** (see Fig. 12.2): the arterial supply to the stomach is exclusively from branches of the coeliac axis. Venous drainage is to the portal system (see Fig. 13.2).
- **Nerve supply:** the anterior and posterior vagal trunks arise from the oesophageal plexuses and enter the abdomen through the oesophageal hiatus. The *hepatic* branches of the anterior vagus pass to the liver. The *coeliac* branch of the posterior vagus passes to the coeliac ganglion from where it proceeds to supply the intestine down to the distal trans-

verse colon. The anterior and posterior vagal trunks descend along the lesser curve as the anterior and posterior nerves of *Latarjet* from which terminal branches arise to supply the stomach. The vagi provide a motor and secretory supply to the stomach. The latter includes a supply to the acid-secreting part—the *body*.

### The duodenum (Figs 19.1 and 19.2)

The duodenum is the first part of the small intestine. It is approximately 25 cm long and curves around the head of the pancreas. Its primary function is in the absorption of digested products. Despite its relatively short length the surface area is greatly enhanced by the mucosa being thrown into folds bearing villi which are visible only at a microscopic level. With the exception of the first 2.5 cm, which is completely covered by peritoneum, the duodenum is a retroperitoneal structure. It is considered in four parts:

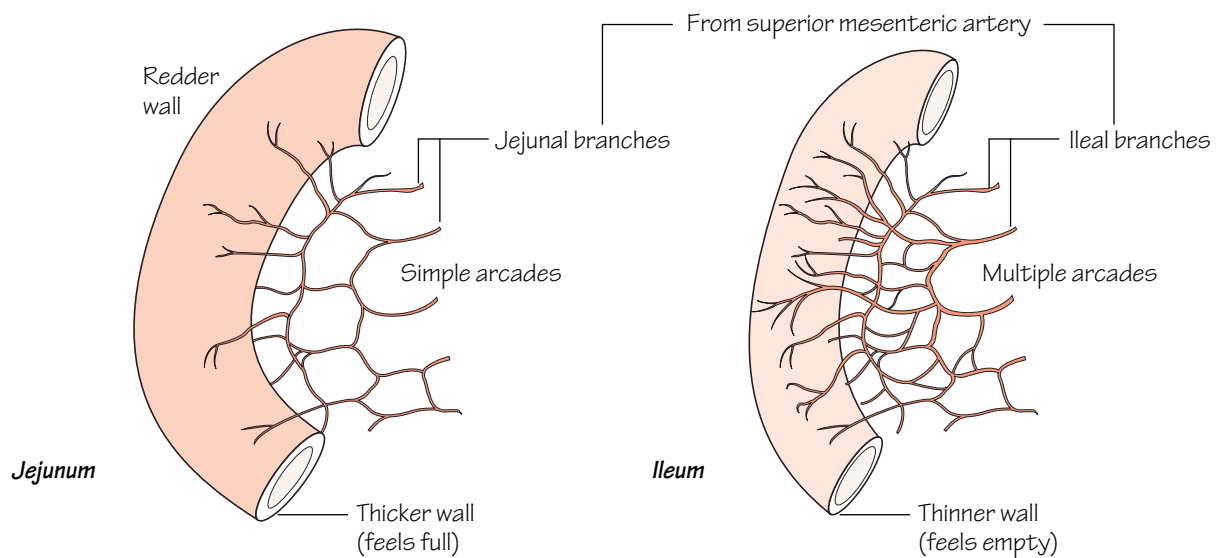
- **First part** (5 cm).
- **Second part** (7.5 cm)—this part descends around the head of the pancreas. Internally, in the mid-section, a small eminence may be found on the posteromedial aspect of the mucosa—the *duodenal papilla*. This structure represents the site of the common opening of the bile duct and *main pancreatic duct (of Wirsung)*. The *sphincter of Oddi* guards this common opening. A smaller *subsidiary pancreatic duct (of Santorini)* opens into the duodenum a small distance above the papilla.
- **Third part** (10 cm)—this part is crossed anteriorly by the root of the mesentery and superior mesenteric vessels.
- **Fourth part** (2.5 cm)—this part terminates as the duodenojejunal junction. The termination of the duodenum is demarcated by a peritoneal fold stretching from the junction to the right crus of the diaphragm covering the *suspensory ligament of Treitz*. The terminal part of the inferior mesenteric vein lies adjacent to the duodenojejunal junction and serves as a useful landmark.
- **Blood supply** (see Fig. 12.2): the superior and inferior pancreaticoduodenal arteries supply the duodenum and run between this structure and the pancreatic head. The superior artery arises from the coeliac axis and the inferior from the superior mesenteric artery.

### Peptic ulcer disease

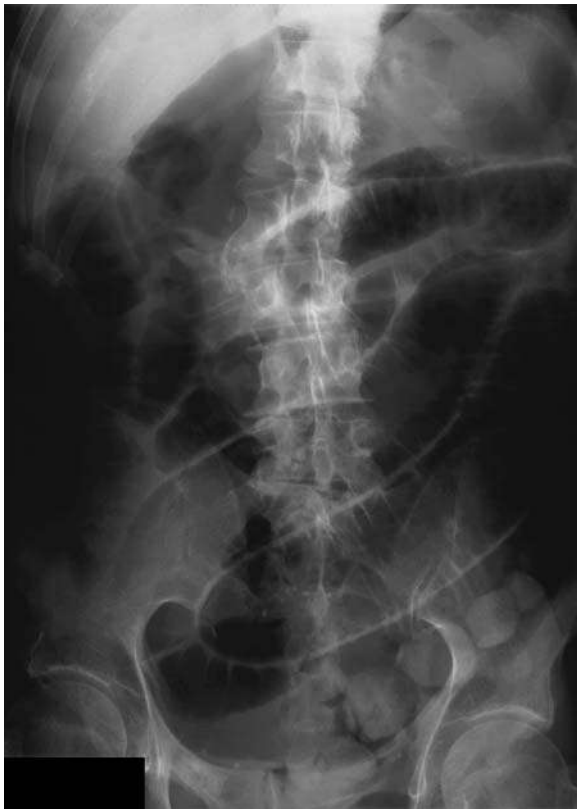*Most peptic ulcers occur in the stomach and proximal duodenum. They arise as a result of an imbalance between acid secretion and mucosal defences. Helicobacter pylori infection is a significant aetiological factor and the eradication of this organism, as well as the attenuation of acid secretion, form the cornerstones of medical treatment. In a minority of cases the symptoms are not controlled by medical treatment alone and surgery is required. 'Very highly selective vagotomy' is a technique where only the afferent vagal fibres to the acid-secreting body are denervated thus not compromising the motor supply to the stomach and hence bypassing the need for a drainage procedure (e.g. gastrojejunostomy).*



## 16 The upper gastrointestinal tract II



**Fig.16.1**  
The jejunum and the ileum can be distinguished by their colour, feel and the complexity of the arterial arcades



**Fig.16.2**  
Small bowel obstruction, showing dilated bowel loops

### **The small intestine** (Fig. 16.1)

The small intestine is approximately 6 m long and comprises the duodenum, jejunum and ileum. A large internal surface area throughout the small intestine facilitates absorption of digested products. The small intestine is suspended from the posterior abdominal wall by its mesentery which contains the superior mesenteric vessels, lymphatics and autonomic nerves. The origin of the mesentery measures approximately 15 cm and passes from the duodenojejunal flexure to the right sacro-iliac joint. The distal border is obviously the same length as the intestine. No sharp distinction occurs between the jejunum and ileum; however, certain characteristics help distinguish between them:

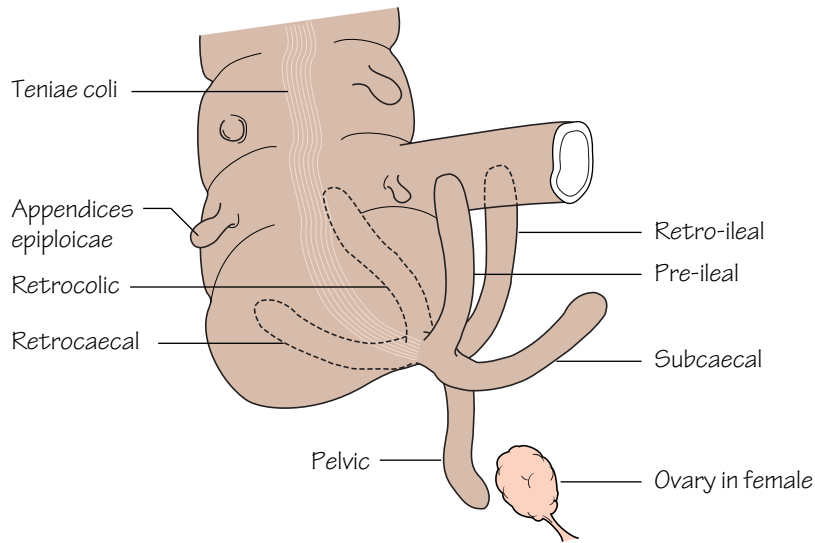
- Excluding the duodenum, the proximal two-fifths of the small intestine comprises jejunum whereas the remaining distal three-fifths comprises ileum. Loops of jejunum tend to occupy the umbilical region whereas the ileum occupies the lower abdomen and pelvis.
- The mucosa of the small intestine is thrown into circular folds—the *valvulae conniventes*. These are more prominent in the jejunum than in the ileum.
- The diameter of the jejunum tends to be greater than that of the ileum.
- The mesentery to the jejunum tends to be thicker than that for the ileum.

- The superior mesenteric vessels (see Fig. 12.3) pass over the third part of the duodenum to enter the root of the mesentery and pass towards the right iliac region on the posterior abdominal wall. Jejunal and ileal branches arise which divide and re-anastomose within the mesentery to produce arcades. End-artery vessels arise from the arcades to supply the gut wall. The arterial supply to the jejunum consists of few arcades and little terminal branching whereas the vessels to the ileum form numerous arcades and much terminal branching of end-arteries passing to the gut wall.

### **Small bowel obstruction** (Fig. 16.2)

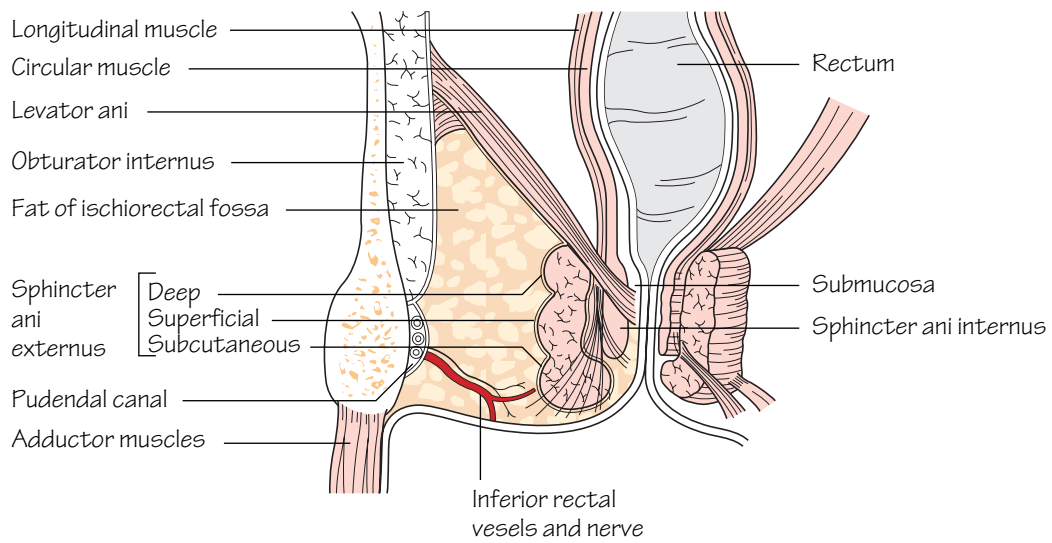
*Small bowel obstruction (SBO) can occur due to luminal, mural or extraluminal factors that result in luminal blockage. Post surgical adhesions and herniae are the most frequent causes. Many cases resolve with conservative measures only; however, if any deterioration in the clinical picture occurs to suggest intestinal infarction or perforation an exploratory laparotomy is mandatory. The classical X-ray features of SBO are those of dilated small bowel loops. These can be distinguished from large bowel as the valvulae conniventes (present only in the small bowel) can be identified traversing the entire lumen whereas the small bowel haustra only partially traverse the lumen.*

# 17 The lower gastrointestinal tract



**Fig.17.1**

The various positions in which the appendix may be found.  
In the pelvic position the appendix may be close to the ovary in the female



**Fig.17.2**

A coronal section through the pelvis to show the anal sphincters and the ischioanal fossa

### The caecum and colon (Figs 17.1, 12.3, 12.5)

In adults, the large bowel measures approximately 1.5 m. The caecum, ascending, transverse, descending and sigmoid colon have similar characteristic features. These are that they possess:

- *Appendices epiploicae* (Fig. 17.1): these are fat-laden peritoneal tags present over the surface of the caecum and colon.
- *Teniae coli* (Fig. 17.1): these are three flattened bands representing the condensed longitudinal muscular coat of the large intestine. They course from the base of the appendix (and form a useful way of locating this structure at operation) to the recto-sigmoid junction.
- *Sacculations*: because the teniae are shorter than the bowel itself the colon takes on a sacculated appearance. These sacculations are visible not only at operation but also radiographically. On a plain abdominal X-ray, the colon, which appears radiotranslucent because of the gas within, has shelf-like processes (*haustra*) which partially project into the lumen.

The transverse and sigmoid colon are each attached to the posterior abdominal wall by their respective mesocolons and are covered entirely by peritoneum. Conversely, the ascending and descending colon normally possess no mesocolon. They are adherent to the posterior abdominal wall and covered only anteriorly by peritoneum.

### The appendix (Fig. 17.1)

The appendix varies enormously in length but in adults it is approximately 5–15 cm long. The base of the appendix arises from the postero-medial aspect of the caecum; however, the lie of the appendix itself is highly variable. In most cases the appendix lies in the retrocaecal position but other positions frequently occur. The appendix has the following characteristic features:

- It has a small mesentery which descends behind the terminal ileum. The only blood supply to the appendix, the appendicular artery (a branch of the ileocolic), courses within its mesentery (see Fig. 12.4). *In cases of appendicitis the appendicular artery ultimately thromboses. When this occurs, gangrene and perforation of the appendix inevitably supervene.*
- The appendix has a lumen which is relatively wide in infants and gradually narrows throughout life, often becoming obliterated in the elderly.
- The teniae coli of the caecum lead to the base of the appendix.
- The *bloodless fold of Treves* (ileocaecal fold) is the name given to a small peritoneal reflection passing from the anterior terminal ileum to the appendix. Despite its name it is not an avascular structure!

*Appendicectomy is performed most commonly through a grid-iron muscle-splitting incision. The appendix is first located and then delivered into the wound. The mesentery of the appendix is then divided and ligated. The appendix is then tied at its base, excised and removed. Most surgeons still opt to invaginate the appendix stump as a precautionary measure against slippage of the stump ligature.*

### The rectum (Figs 17.2, 12.5)

- The rectum measures 10–15 cm in length. It commences in front of the 3rd sacral vertebra as a continuation of the sigmoid colon and follows the curve of the sacrum anteriorly. It turns backwards abruptly in front of the coccyx to become the anal canal.
- The mucosa of the rectum is thrown into three horizontal folds that project into the lumen—the *valves of Houston*.
- The rectum lacks haustrations. The teniae coli fan out over the rectum to form anterior and posterior bands.
- The rectum is slightly dilated at its lower end—the *ampulla*, and is supported laterally by the levator ani.
- Peritoneum covers the upper two-thirds of the rectum anteriorly but only the upper third laterally. In the female it is reflected forwards onto the uterus forming the *recto-uterine pouch (pouch of Douglas)*. The rectum is separated from anterior structures by a tough fascial sheet—the *rectovesical (Denonvilliers) fascia*.

### The anal canal (Fig. 17.2)

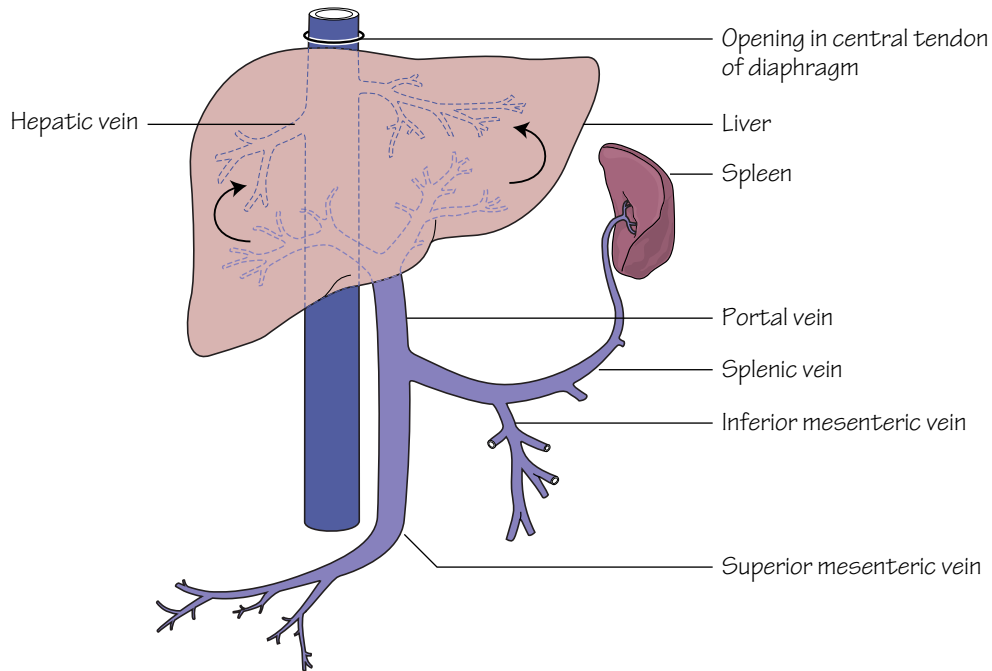
The anorectal junction is slung by the puborectalis component of levator ani which pulls it forwards. The canal is approximately 4 cm long and angled postero-inferiorly. Developmentally the midpoint of the anal canal is represented by the *dentate line*. This is the site where the proctodeum (ectoderm) meets endoderm. This developmental implication is reflected by the following characteristics of the anal canal:

- The epithelium of the upper half of the anal canal is columnar. In contrast the epithelium of the lower half of the anal canal is squamous. The mucosa of the upper canal is thrown into vertical columns (*of Morgagni*). At the bases of the columns are valve-like folds (*valves of Ball*). The level of the valves is termed the dentate line.
- The blood supply to the upper anal canal (see Fig. 12.5) is from the superior rectal artery (derived from the inferior mesenteric artery) whereas the lower anal canal is supplied by the inferior rectal artery (derived from the internal iliac artery). As mentioned previously, the venous drainage follows suit and represents a site of porto-systemic anastomosis (see p. 35).
- The upper anal canal is insensitive to pain as it is supplied by autonomic nerves only. The lower anal canal is sensitive to pain as it is supplied by somatic innervation (inferior rectal nerve).
- The lymphatics from the upper canal drain upwards along the superior rectal vessels to the internal iliac nodes whereas lymph from the lower anal canal drains to the inguinal nodes.

### The anal sphincter

See Chapter 25.

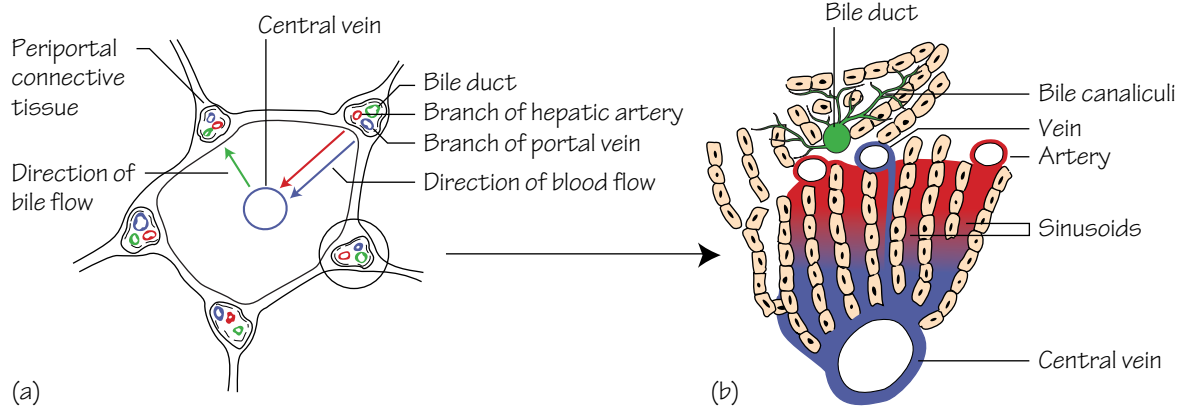
# 18 The liver, gall-bladder and biliary tree



**Fig.18.1**

The venous circulation through the liver.

The transmission of blood from the portal system to the inferior vena cava is via the liver lobules (fig. 18.2)



**Fig.18.2**

(a) A liver lobule to show the direction of blood flow from the portal system to the centrilobular veins and thence to the inferior vena cava

(b) The blood flow through the sinusoids of the liver lobule and the passage of bile from the bile canaliculi to the bile ducts

## The liver (see Fig. 14.3)

- The liver predominantly occupies the right hypochondrium but the left lobe extends to the epigastrium. Its domed upper (*diaphragmatic*) surface is related to the diaphragm and its lower border follows the contour of the right costal margin. *When the liver is enlarged the lower border becomes palpable below the costal margin.*
- The liver anatomically consists of a large right lobe, and a smaller left lobe. These are separated antero-superiorly by the falciform ligament and postero-inferiorly by *fissures for the ligamentum venosum and ligamentum teres*. In the anatomical classification the right lobe includes the caudate and quadrate lobes. Functionally, however, the caudate and most of the quadrate lobes are units of the left lobe as they receive their blood supplies from the left hepatic artery and deliver their bile into the left hepatic duct. Hence, the functional classification of the liver defines the right and left lobes as separated by a vertical plane extending posteriorly from the gall-bladder to the inferior vena cava (IVC).
- When the postero-inferior (*visceral*) surface of the liver is seen from behind an H-shaped arrangement of grooves and fossae is identified. The boundaries of the H are formed as follows:
  - *Right anterior limb*—the gall-bladder fossa.
  - *Right posterior limb*—the groove for the IVC.
  - *Left anterior limb*—the fissure containing the ligamentum teres (the fetal remnant of the left umbilical vein which returns oxygenated blood from the placenta to the fetus).
  - *Left posterior limb*—the fissure for the ligamentum venosum (the latter structure is the fetal remnant of the ductus venosus; in the fetus the ductus venosus serves to partially bypass the liver by transporting blood from the left umbilical vein to the IVC).
  - *Horizontal limb*—the *porta hepatis*. The caudate and quadrate lobes of the liver are the areas defined above and below the horizontal bar of the H, respectively.
- The *porta hepatis* is the hilum of the liver. It transmits (from posterior to anterior) the: portal vein (Fig. 18.1); branches of the hepatic artery and hepatic ducts. The porta is enclosed within a double layer of peritoneum—the lesser omentum, which is firmly attached to the ligamentum venosum in its fissure.
- The liver is covered by peritoneum with the exception of the ‘bare area’.
- The liver is made up of multiple functional units—*lobules* (Fig. 18.2). Branches of the portal vein and hepatic artery transport blood through portal canals into a central vein by way of sinusoids which traverse the lobules. The central veins ultimately coalesce into the right, left and central hepatic veins which drain blood from corresponding liver areas backwards into the IVC. The portal canals also contain tributaries of the

hepatic ducts which serve to drain bile from the lobule down the biliary tree from where it can be concentrated in the gall-bladder and eventually released into the duodenum. *The extensive length of gut that is drained by the portal vein explains the predisposition for intestinal tumours to metastasize to the liver.*

## The gall-bladder (see Fig. 14.3)

The gall-bladder lies adherent to the undersurface of the liver in the transpyloric plane (p. 53) at the junction of the right and quadrate lobes. The duodenum and the transverse colon are behind it.

The gall-bladder acts as a reservoir for bile which it concentrates. It usually contains approximately 50 mL of bile which is released through the cystic and then common bile ducts into the duodenum in response to gall-bladder contraction induced by gut hormones.

- **Structure:** the gall-bladder comprises a *fundus*, a *body* and a *neck* (which opens into the cystic duct).
- **Blood supply:** the arterial supply to the gall-bladder is derived from two sources: the cystic artery which is usually, but not always, a branch of the right hepatic artery, and small branches of the hepatic arteries which pass via the fossa in which the gall-bladder lies. The cystic artery represents the most significant source of arterial supply. There is, however, no corresponding cystic vein but venous drainage occurs via small veins passing through the gall-bladder bed.

## The biliary tree

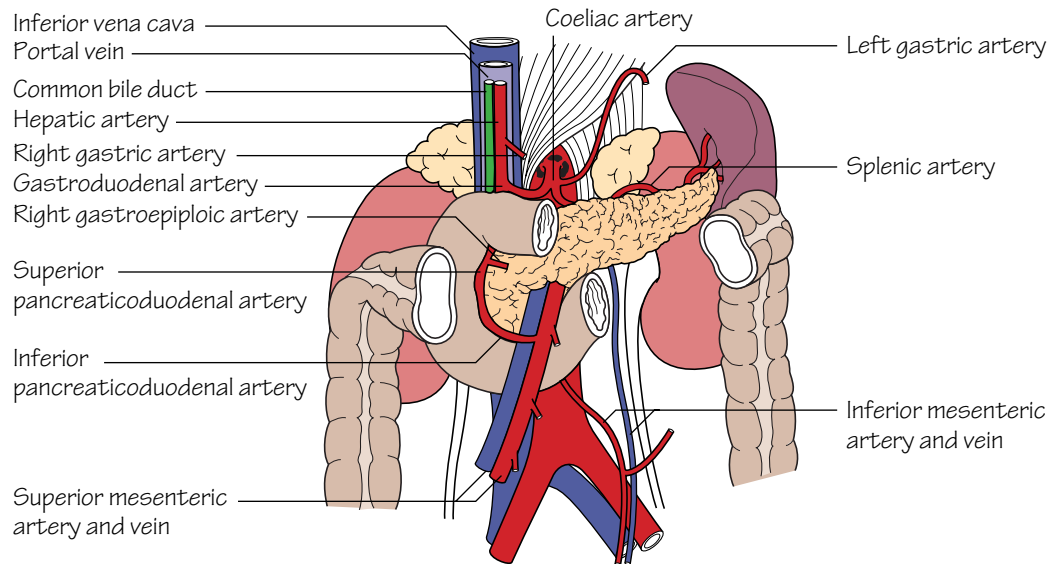
The common hepatic duct is formed by the confluence of the right and left hepatic ducts in the porta hepatis. The common hepatic duct is joined by the cystic duct to form the common bile duct. This structure courses, sequentially, in the free edge of the lesser omentum, behind the first part of the duodenum and in the groove between the second part of the duodenum and the head of the pancreas. It ultimately opens at the papilla on the medial aspect of the second part of the duodenum.

The common bile duct usually, but not always, joins with the main *pancreatic duct (of Wirsung)* (p. 47).

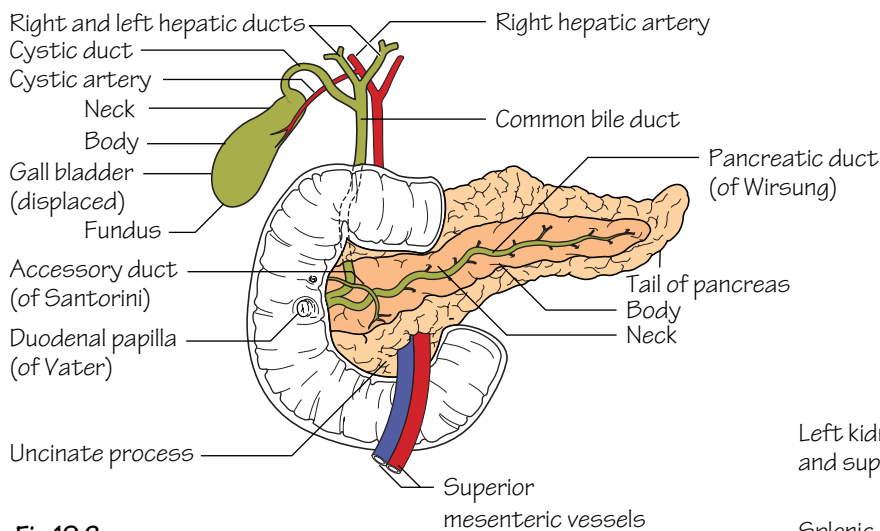
## Cholelithiasis

*Gallstones are composed of either cholesterol, bile pigment, or, more commonly, a mixture of these two constituents. Cholesterol stones form due to an altered composition of bile resulting in the precipitation of cholesterol crystals. Most gallstones are asymptomatic; however, when they migrate down the biliary tree they can be responsible for a diverse array of complications such as: acute cholecystitis, biliary colic, cholangitis and pancreatitis.*

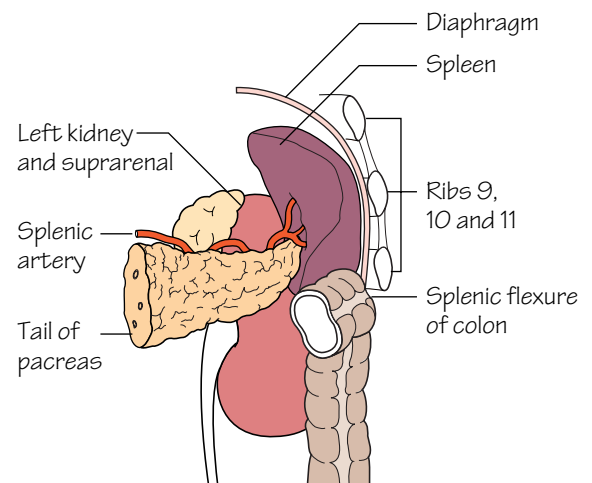
# 19 The pancreas and spleen



**Fig.19.1**  
The relations of the pancreas



**Fig.19.2**  
The ducts of the pancreas and the biliary system



**Fig.19.3**  
The relations of the spleen



## The pancreas (Figs 19.1 and 19.2)

The pancreas has a: *head, neck, body* and *tail*. It is a retroperitoneal organ which lies roughly along the transpyloric plane. The head is bound laterally by the curved duodenum and the tail extends to the hilum of the spleen in the lienorenal ligament. The superior mesenteric vessels pass behind the pancreas, then anteriorly, over the *uncinate process* and third part of the duodenum into the root of the small bowel mesentery. The inferior vena cava, aorta, coeliac plexus, left kidney (and its vessels) and the left adrenal gland are posterior pancreatic relations. In addition, the portal vein is formed behind the pancreatic neck by the confluence of the splenic and superior mesenteric veins. The lesser sac and stomach are anterior pancreatic relations.

- **Structure:** the main *pancreatic duct (of Wirsung)* courses the length of the gland, ultimately draining pancreatic secretions into the *ampulla of Vater*, together with the common bile duct, and thence into the second part of the duodenum. An *accessory duct (of Santorini)* drains the uncinata process of the pancreas, opening slightly proximal to the ampulla into the second part of the duodenum.

- **Blood supply:** the pancreatic head receives its supply from the superior and inferior pancreaticoduodenal arteries. The splenic artery courses along the upper border of the body of the pancreas which it supplies by means of a large branch—the *arteria pancreatica magna*—and numerous smaller branches.

- **Function:** the pancreas is a lobulated structure which performs both exocrine and endocrine functions. The exocrine secretory glands drain pancreatic juice into the pancreatic ducts and, from there, ultimately into the duodenum. The secretion is essential for the digestion and absorption of proteins, fats and carbohydrates. The endocrine pancreas is responsible for the production and secretion of glucagon and insulin, which take place in specialized cells of the islets of Langerhans.

## Acute pancreatitis

*The presence of gallstones and a history of excessive alcohol intake are the predominant associations for pancreatitis. The mechanism by which these aetiological factors result in pancreatic injury is unknown; however, they both appear to result in activation of pancreatic exocrine pro-enzymes with resultant autodigestion. Even today, the mortality rate for severe acute pancreatitis remains in the region of 20%.*

## The spleen (Fig. 19.3)

The spleen is approximately the size of a clenched fist and lies directly below the left hemidiaphragm which, in addition to the pleura, separates it from the overlying 9th, 10th and 11th ribs.

- **Peritoneal attachments:** the splenic capsule is fibrous with peritoneum adherent to its surface. The gastrosplenic and lienorenal ligaments attach it to the stomach and kidney, respectively. The former ligament carries the short gastric and left gastroepiploic vessels to the fundus and greater curvature of the stomach, and the latter ligament carries the splenic vessels and tail of the pancreas towards the left kidney.

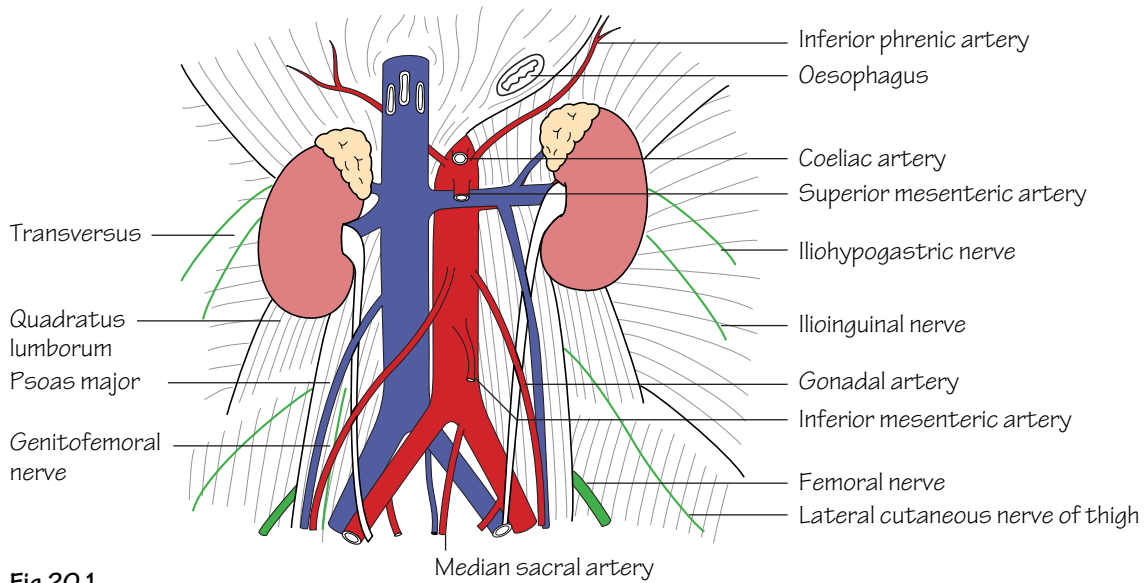
- **Blood supply:** is from the splenic artery to the hilum of the spleen. Venous drainage is to the splenic vein, thence to the portal vein.

- **Structure:** the spleen is a highly vascular reticulo-endothelial organ. It consists of a thin capsule from which trabeculae extend into the splenic pulp. In the spleen, the immunological centres, i.e. the lymphoid follicles (the *white pulp*), are scattered throughout richly vascularized sinusoids (the *red pulp*).

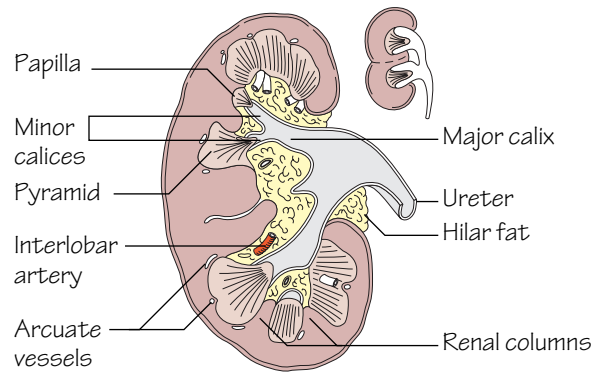
## Splenectomy

*As the spleen is a highly vascular organ, any injury to it can be life-threatening. Under these circumstances splenectomy must be carried out urgently. The technique used differs slightly when the procedure is performed for emergency as opposed to elective indications, but the principles are similar. Splenectomy involves: ligation of the splenic vessels approaching the hilum (taking care not to injure the tail of the pancreas or colon); and dissection of the splenic pedicles—the gastrosplenic (including the short gastric vessels) and lienorenal ligaments. As the spleen is an important immunological organ, postsplenectomy patients are rendered immunocompromised to capsulated bacteria. The latter organisms (e.g. meningococcus, pneumococcus) require opsonization for elimination and splenic lymphoid follicles are the principal sites where this takes place. Hence, following splenectomy, all patients are routinely vaccinated against the capsulated bacteria, and children, who are the group most at risk of sepsis, are maintained on long-term antibiotic prophylaxis.*

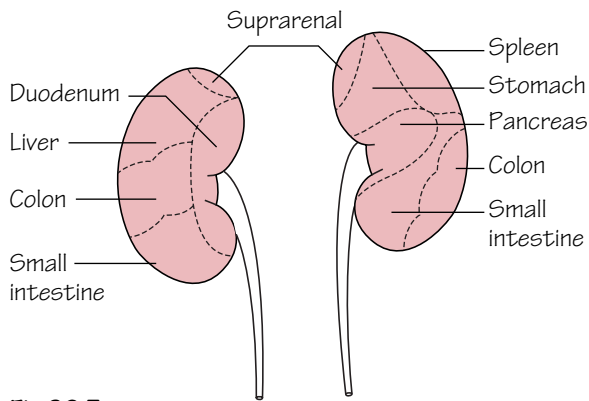
# 20 The posterior abdominal wall



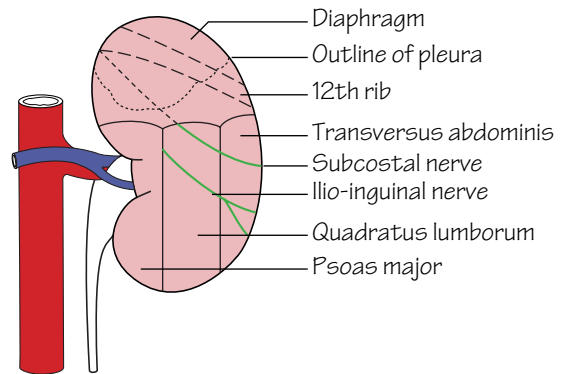
**Fig.20.1**  
The structures of the posterior abdominal wall



**Fig.20.2**  
A section through the right kidney.  
The small diagram shows how the renal columns represent the cortices of adjacent fused lobes



**Fig.20.3**  
The anterior relations of the kidneys



**Fig.20.4**  
The posterior relations of the kidneys

## The structures of the posterior abdominal wall (Fig. 20.1)

These include:

- **Muscles:** including psoas major and quadratus lumborum (see Muscle index, p. 162).
- The *abdominal aorta* and its branches: see p. 32.
- The *inferior vena cava* (IVC) and its tributaries: see p. 35.
- The *kidneys*.
- The *ureters*.
- The *adrenal (suprarenal) glands*.
- The *lumbar sympathetic trunks and plexuses* and the *lumbar plexus* (see p. 51).

## The kidneys (Fig. 20.2)

• **Structure:** the kidney has its own fibrous capsule and is surrounded by *perinephric fat* which, in turn, is enclosed by *renal fascia*. Each kidney is approximately 10–12 cm long and consists of an outer *cortex*, an inner *medulla* and a *pelvis*.

The hilum of the kidney is situated medially and transmits from front to back the: renal vein, renal artery, ureteric pelvis as well as lymphatics and sympathetic vasomotor nerves.

The renal pelvis divides into two or three major calices and these, in turn, divide into minor calices which receive urine from the medullary pyramids by way of the papillae.

• **Position:** the kidneys lie in the retroperitoneum against the posterior abdominal wall. The right kidney lies approximately 1 cm lower than the left.

• **Relations:** See Figs 20.3 and 20.4.

• **Blood supply:** the renal arteries arise from the aorta at the level of L2. Together, the renal arteries direct 25% of the cardiac output towards the kidneys. Each renal artery divides into five *segmental arteries* at the hilum which, in turn, divide sequentially into *lobar*, *interlobar*, *arcuate* and *cortical radial branches*. The cortical radial branches give rise to the afferent arterioles which supply the glomeruli and go on to become efferent arterioles. The differential pressures between afferent and efferent arterioles lead to the production of an ultrafiltrate which then passes through, and is modified by, the nephron to produce urine.

The right renal **artery** passes behind the IVC. The left renal **vein** is long as it courses in front of the aorta to drain into the IVC.

• **Lymphatic drainage:** to the para-aortic lymph nodes.

## The ureter (Fig. 20.1)

The ureter is considered in abdominal, pelvic and intravesical portions.

• **Structure:** the ureter is approximately 20–30 cm long and courses from the hilum of the kidney to the bladder. It has a muscular wall and is lined by transitional epithelium. At operation it can be recognized by its peristalsis.

• **Course:** from the renal pelvis at the hilum the course of the ureter can be summarized as follows:

- It passes along the medial part of psoas major behind, but adherent to, the peritoneum.
- It then crosses the common iliac bifurcation anterior to the sacro-iliac joint and courses over the lateral wall of the pelvis to the ischial spine.
- At the ischial spine the ureter passes forwards and medially to enter the bladder obliquely. The intravesical portion of the ureter is approximately 2 cm long and its passage through the bladder wall produces a sphincter-like effect. In the male the ureter is crossed superficially near its termination by the vas deferens. In the female the ureter passes above the lateral fornix of the vagina but below the broad ligament and uterine vessels.

• **Blood supply:** as the ureter is an abdominal and pelvic structure it receives a blood supply from multiple sources:

- The *upper ureter*—receives direct branches from the aorta, renal and gonadal arteries.
- The *lower ureter*—receives branches of the internal iliac and inferior vesical arteries.

## Ureteric stones

*Most ureteric calculi arise for unknown reasons, although inadequate urinary drainage, the presence of infected urine, and hypercalcaemia are definite predisposing factors. The presence of an impacted ureteric stone is characterized by haematuria and agonizing colicky pain (ureteric colic), which classically radiates from loin to groin. Large impacted stones can lead to hydronephrosis and/or infection of the affected kidney and consequently need to be broken up or removed by interventional or open procedures.*

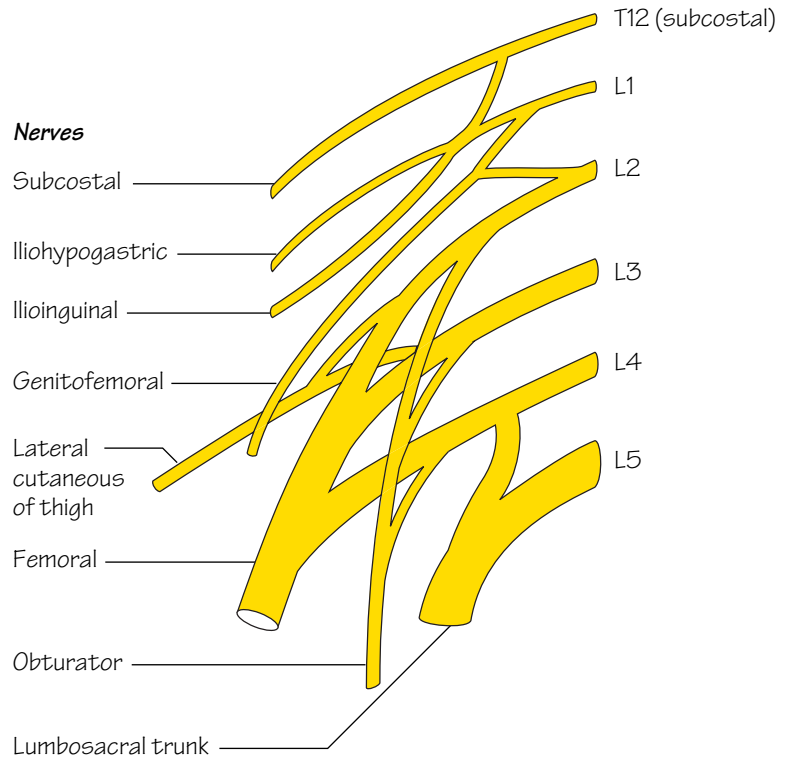
## Adrenal (suprarenal) glands (Fig. 20.1)

The adrenal glands comprise an outer *cortex* and inner *medulla*. The cortex is derived from mesoderm and is responsible for the production of steroid hormones (glucocorticoids, mineralocorticoids and sex steroids). The medulla is derived from ectoderm (neural crest) and acts as a part of the autonomic nervous system. It receives sympathetic preganglionic fibres from the greater splanchnic nerves which stimulate the medulla to secrete noradrenaline and adrenaline into the bloodstream.

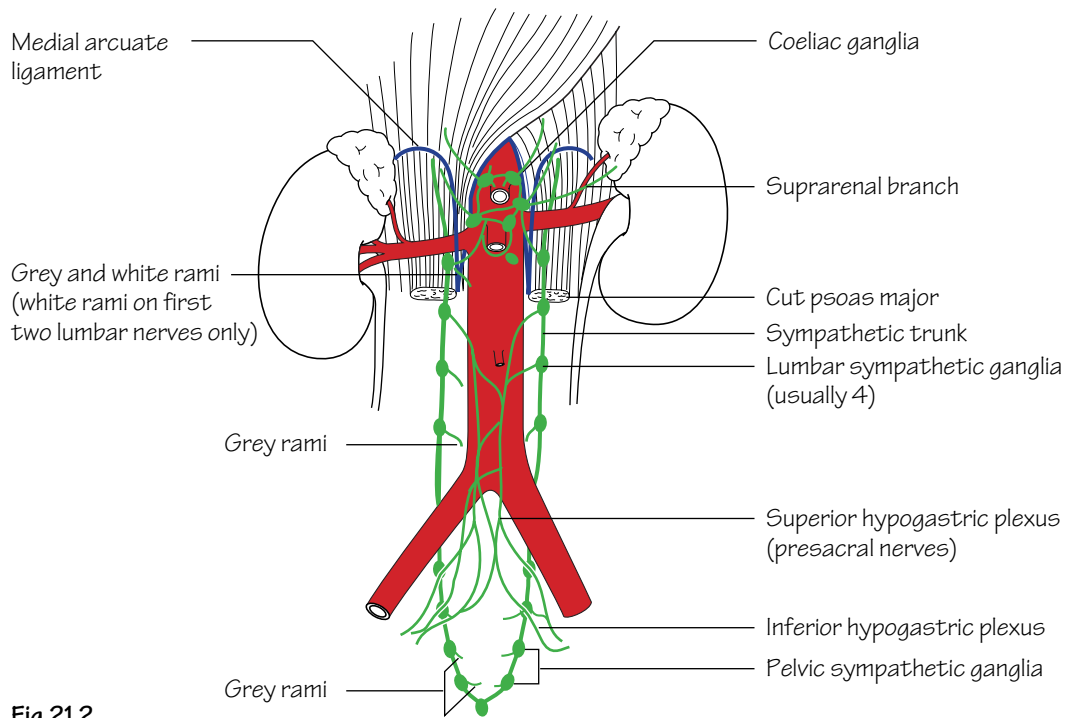
• **Position:** the adrenals are small glands which lie in the renal fascia on the upper poles of the kidneys. The right gland lies behind the right lobe of the liver and immediately posterolateral to the IVC. The left adrenal is anteriorly related to the lesser sac and stomach.

• **Blood supply:** the phrenic, renal arteries and aorta all contribute branches to the adrenal glands. Venous drainage is on the right to the IVC and on the left to the left renal vein.

## 21 The nerves of the abdomen



**Fig.21.1**  
The lumbar plexus



**Fig.21.2**  
The sympathetic system in the abdomen and pelvis

### The lumbar plexus (Fig. 21.1)

- The lumbar plexus is formed from the anterior primary rami of L1–4. The trunks of the plexus lie within the substance of psoas major and, with the exceptions of the obturator and genitofemoral nerves, emerge at its lateral border.
- The 12th intercostal nerve is also termed the *subcostal nerve* as it has no intercostal space but, instead, runs below the rib in the neurovascular plane to supply the abdominal wall.
- The *iliohypogastric nerve* is the main trunk of the 1st lumbar nerve. It supplies the skin of the upper buttock, by way of a lateral cutaneous branch, and terminates by piercing the external oblique above the superficial inguinal ring where it supplies the overlying skin of the mons pubis. The *ilioinguinal nerve* is the collateral branch of the iliohypogastric. The ilioinguinal runs in the neurovascular plane of the abdominal wall to emerge through the superficial inguinal ring to provide a cutaneous supply to the skin of the medial thigh, the root of the penis and anterior one third of the scrotum (or labium majus in the female).
- The *genitofemoral nerve* (L1,2) emerges from the anterior surface of psoas major. It courses inferiorly and divides into: a genital component that enters the spermatic cord and supplies the cremaster (in the male), and a femoral component that supplies the skin of the thigh overlying the femoral triangle.
- The *lateral cutaneous nerve of the thigh* (L2,3), having emerged from the lateral border of psoas major, encircles the iliac fossa to pass under the inguinal ligament (p. 99).
- The *femoral nerve* (L2–4, posterior division): see p. 99.
- The *obturator nerve* (L2–4, anterior division): see p. 99.
- A large part of L4 joins with L5 to contribute to the sacral plexus as the lumbosacral trunk.

### Lumbar sympathetic chain (Fig. 21.2)

- **Sympathetic supply:** the lumbar sympathetic chain is a continuation of the thoracic sympathetic chain as it passes under the medial arcuate ligament of the diaphragm. The chain passes anterior to the lumbar vertebral bodies and usually carries four ganglia which send grey rami communicans to the lumbar spinal nerves. The upper two ganglia receive white rami from L1 and L2.

The lumbar sympathetic chain, the splanchnic nerves and the vagus contribute sympathetic and parasympathetic branches to plexuses (coeliac, superior mesenteric, renal and inferior mesenteric) around the abdominal aorta. In addition, other branches continue inferiorly to form the *superior hypogastric plexus* (*presacral nerves*) from where they branch into right and left *inferior hypogastric plexuses*. The latter also receive a parasympathetic supply from the pelvic splanchnic nerves. The branches from the inferior hypogastric plexuses are distributed to the pelvic viscera along the course and branches of the internal iliac artery.

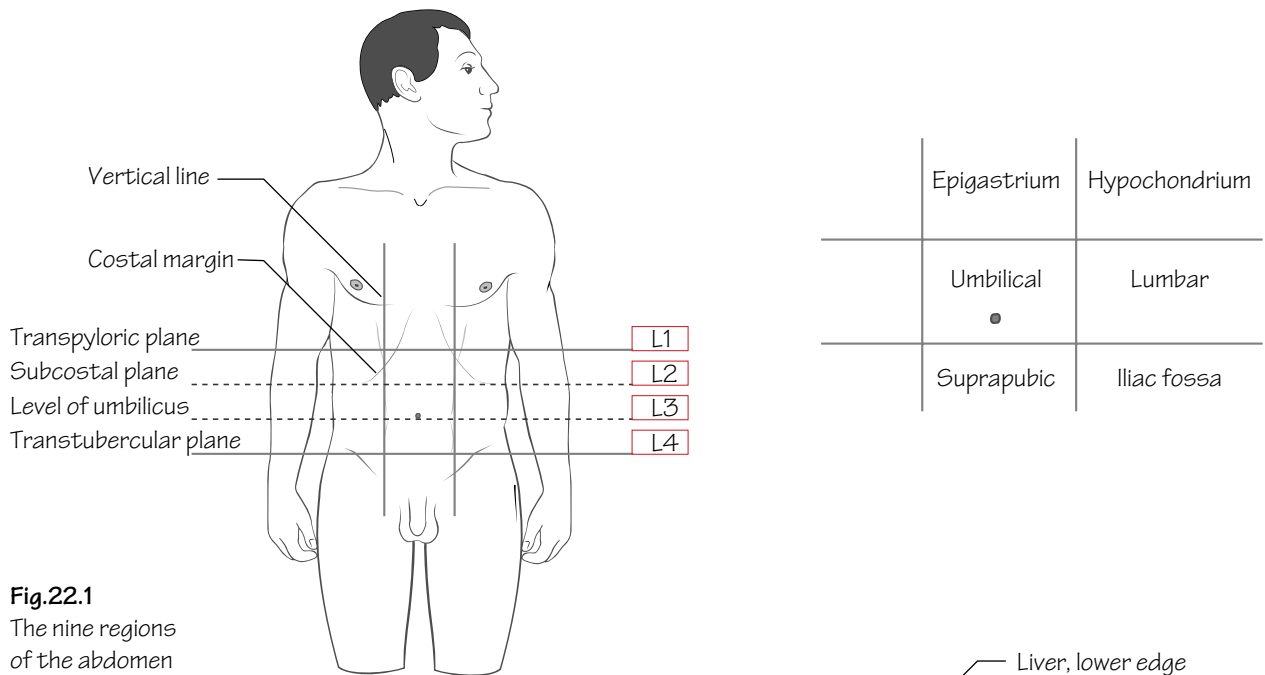
The *coeliac ganglia* are prominent and lie around the origins of the coeliac and superior mesenteric arteries.

- **Parasympathetic supply:** to the pelvic viscera arises from the anterior primary rami of S2,3,4—the *pelvic splanchnic nerves*. The latter parasympathetic supply reaches proximally as far as the junction between the hindgut and midgut on the transverse colon.

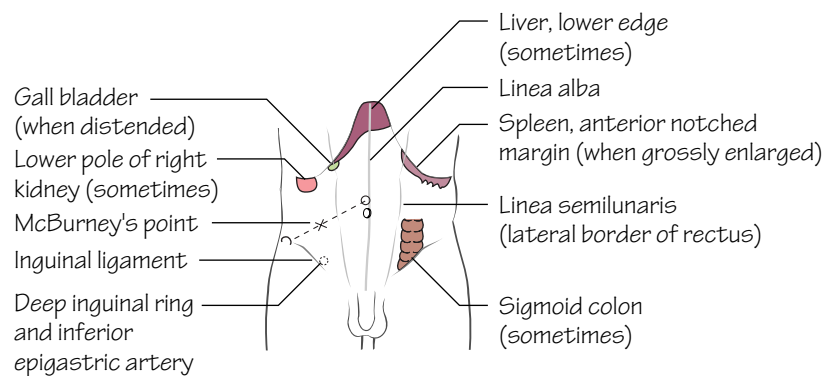
### Lumbar sympathectomy

*This procedure is performed in cases of severe peripheral vascular disease of the lower limbs where vascular reconstructive surgery is not possible and skin necrosis is imminent. The operation involves excision of the 2nd to 4th lumbar ganglia with the intermediate chain.*

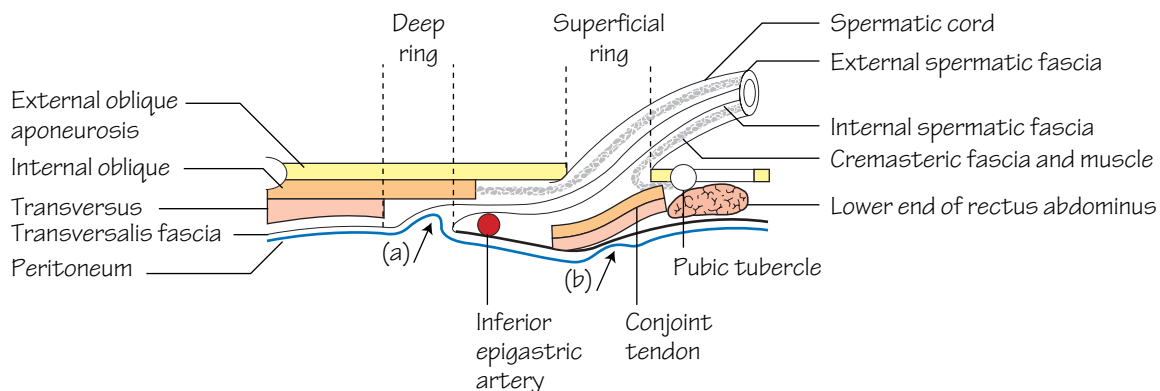
## 22 Surface anatomy of the abdomen



**Fig.22.1**  
The nine regions of the abdomen



**Fig.22.2**  
McBurney's point and some of the structures that may be palpated in the abdomen



**Fig.22.3**  
A horizontal section through the inguinal canal. Diagrammatic.  
(a) and (b) show the sites of indirect and direct herniae respectively



## Vertebral levels (Fig. 22.1)

(In each case the lower border is referred to.)

- **T9:** *xiphoid process*.
- **L1:** the *transpyloric plane* (of Addison). This horizontal plane passes approximately through the tip of the 9th costal cartilage, the pylorus, pancreatic neck, duodenojejunal flexure, the gall-bladder fundus and the hila of the kidneys. This plane also corresponds to the level at which the spinal cord terminates and the lateral edge of rectus abdominis crosses the costal margin.
- **L2:** the *subcostal plane*. This plane corresponds to a line joining the lowest points of the thoracic cage—the lower margin of the 10th rib laterally.
- **L3:** the level of the umbilicus (in a young slim person).
- **L4:** the *transtubercular plane*. This corresponds to a line which joins the tubercles of the iliac crests.

## Lines of orientation

*Vertical lines:* these are imaginary and most often used with the subcostal and intertubercular planes, for purposes of description, to subdivide the abdomen into nine regions (Fig. 22.1). They pass vertically, on either side, through the point halfway between the anterior superior iliac spine and the pubic tubercle. More commonly used, for description of pain location, are quadrants. The latter are imaginary lines arising by the bisection of the umbilicus by vertical and horizontal lines.

## Surface markings of the abdominal wall

- The *costal margin* (Fig. 22.1) is the inferior margin of the thoracic cage. It includes the costal cartilages anteriorly, the 7th–10th ribs laterally and the cartilages of the 11th and 12th ribs posteriorly.
- The *symphysis pubis* is an easily palpable secondary cartilaginous joint which lies between the pubic bones in the midline. The *pubic tubercle* is an important landmark and is identifiable on the superior surface of the pubis.
- The *inguinal ligament* (Figs 11.1 and 22.2) is attached laterally to the anterior superior iliac spine and medially to the pubic tubercle.
- The *superficial inguinal ring* (see Fig. 11.1) is a triangular-shaped defect in the external oblique aponeurosis. It is situated above and medial to the pubic tubercle.
- The *spermatic cord* can be felt passing medial to the pubic tubercle and descending into the scrotum.
- The *deep inguinal ring* (Fig. 22.3) lies halfway along a line from the anterior superior iliac spine to the pubic tubercle.
- The *linea alba* (see Fig. 11.1) is formed by the fusion of the aponeuroses of the muscles of the anterior abdominal wall. It extends as a depression in the midline from the xiphoid process to the symphysis pubis.

- The *linea semilunaris* is the lateral edge of the rectus abdominis muscle. It crosses the costal margin at the tip of the 9th costal cartilage.

## Inguinal herniae (Figs 22.3 and 52.1)

- **Indirect inguinal herniae:** arise as a result of persistence of the *processus vaginalis* of the embryo. Abdominal contents bulge through the deep inguinal ring, into the canal, and eventually into the scrotum. This hernia can be controlled by digital pressure over the deep ring.
- **Direct inguinal herniae:** arise as a result of weakness in the posterior wall of the inguinal canal. This hernia cannot be controlled by digital pressure over the deep ring and only rarely does the hernia pass into the scrotum.

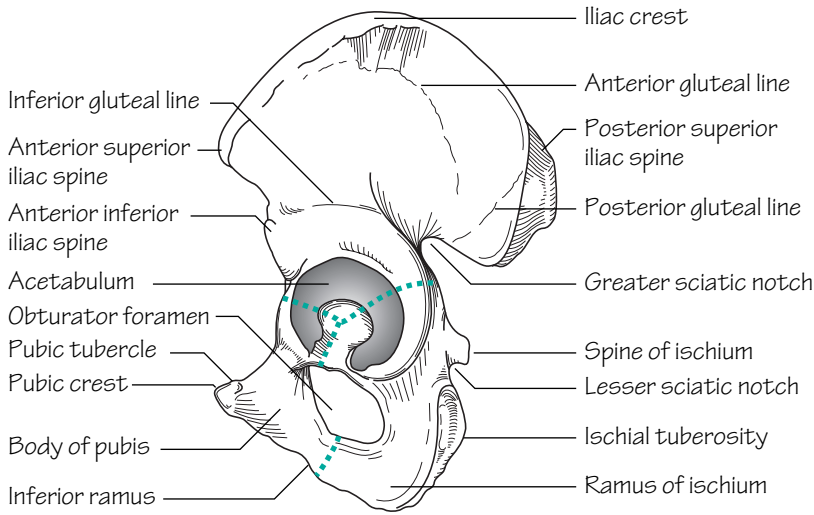
*The clinical distinction between direct and indirect inguinal hernias can be difficult. At operation, however, the relation of the hernial neck to the inferior epigastric artery defines the hernia type, i.e. the neck of the sac of an indirect hernia lies lateral to the artery whereas that of a direct type always lies medial to it.*

## Surface markings of the abdominal viscera (Fig. 22.2)

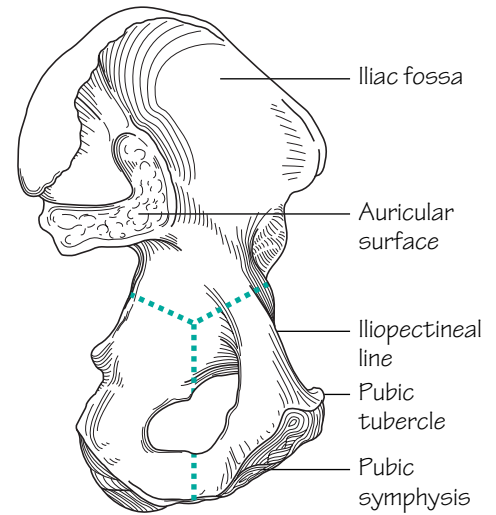
- **Liver:** the lower border of the liver is usually just palpable on deep inspiration in slim individuals. The upper border follows the undersurface of the diaphragm and reaches a level just below the nipple on each side.
- **Spleen:** this organ lies below the left hemidiaphragm deep to the 9th, 10th and 11th ribs posteriorly. The *anterior notch* reaches the mid-axillary line anteriorly.
- **Gall-bladder:** the fundus of the gall-bladder lies in the transpyloric plane (L1). The surface marking corresponds to a point where the lateral border of rectus abdominis (*linea semilunaris*) crosses the costal margin.
- **Pancreas:** the pancreatic neck lies on the level of the transpyloric plane (L1). The pancreatic head lies to the right and below the neck whereas the body and tail pass upwards and to the left.
- **Aorta:** the aorta bifurcates to the left of the midline at the level of L4.
- **Kidneys:** the kidney hila lie on the level of the transpyloric plane (L1). The lower pole of the right kidney usually extends 3 cm below the level of the left and is often palpable in slim subjects.
- **Appendix:** *McBurney's point* represents the surface marking for the base of the appendix. This point lies one third of the way along a line joining the anterior superior iliac spine and the umbilicus. *McBurney's point* is important surgically as it represents the usual site of maximal tenderness in appendicitis and also serves as the central point for the incision made when performing an appendicectomy.
- **Bladder:** in adults the bladder is a pelvic organ and can be palpated above the symphysis pubis only when full or enlarged.



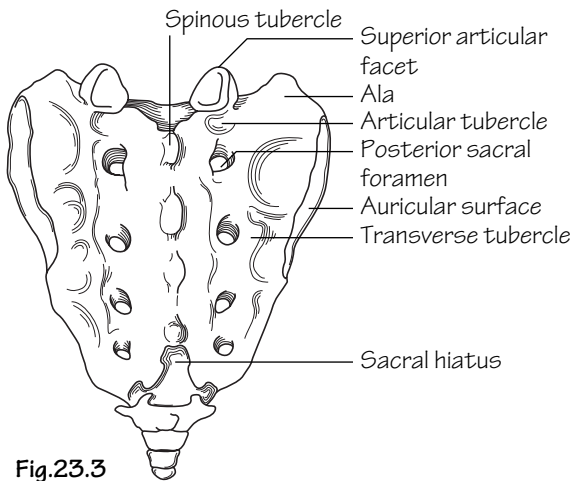
# 23 The pelvis I—the bony and ligamentous pelvis



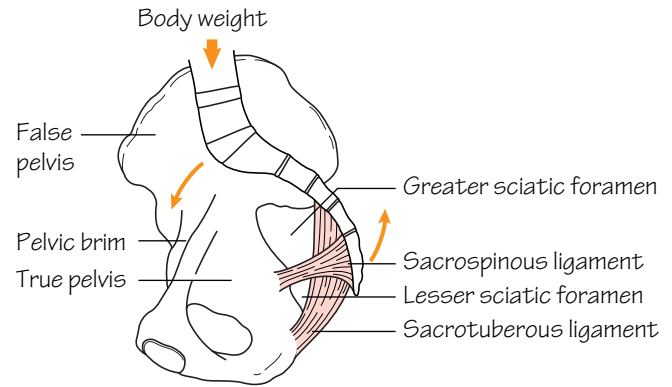
**Fig.23.1**  
The lateral surface of the left hip bone



**Fig.23.2**  
The medial surface of the left hip bone

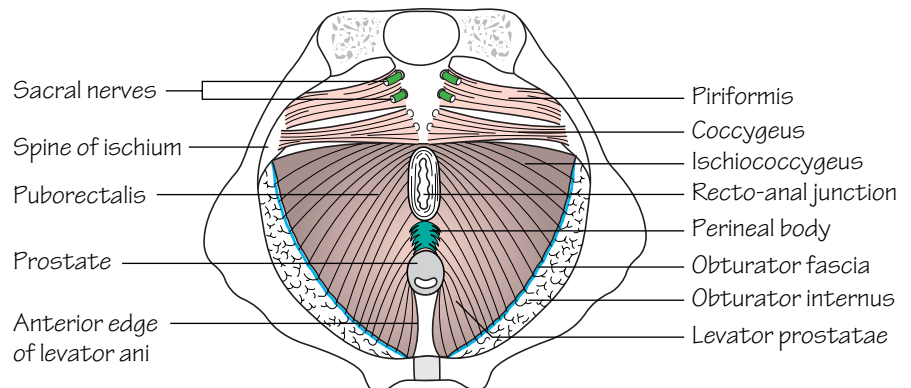


**Fig.23.3**  
The posterior surface of the sacrum



**Fig.23.4**  
The sacrospinous and sacrotuberous ligaments resist rotation of the sacrum due to the body weight

**Fig.23.5**  
The male pelvic floor from above. The blue line represents the origin of levator ani from the obturator fascia



The pelvis is bounded posteriorly by the sacrum and coccyx and anterolaterally by the innominate bones.

### Os innominatum (hip bone) (Figs 23.1 and 23.2)

This bone comprises three component parts, the: *ilium*, *ischium* and *pubis*. By adulthood the constituent bones have fused together at the acetabulum. Posteriorly each hip bone articulates with the sacrum at the *sacro-iliac joint* (a synovial joint).

- **Ilium:** the *iliac crest* forms the upper border of the bone. It runs backwards from the *anterior superior iliac spine* to the *posterior superior iliac spine*. Below each of these bony landmarks are the corresponding inferior spines. The outer surface of the ilium is termed the *gluteal surface* as it is where the gluteal muscles are attached. The *inferior, anterior* and *posterior gluteal lines* demarcate the bony attachments of the glutei. The inner surface of the ilium is smooth and hollowed out to form the *iliac fossa*. It gives attachment to the iliacus muscle. The *auricular* surface of the ilium articulates with the sacrum at the *sacro-iliac joints* (synovial joints). *Posterior, interosseous* and *anterior sacro-iliac ligaments* strengthen the sacro-iliac joints. The *iliopectineal line* courses anteriorly on the inner surface of the ilium from the auricular surface to the pubis. It forms the lateral margin of the *pelvic brim* (see below).
- **Ischium:** comprises a *spine* on its posterior part which demarcates the *greater* (above) and *lesser sciatic* (below) *notches*. The *ischial tuberosity* is a thickening on the lower part of the body of the ischium which bears weight in the sitting position. The *ischial ramus* projects forwards from the tuberosity to meet and fuse with the *inferior pubic ramus*.
- **Pubis:** comprises a *body* and *superior* and *inferior pubic rami*. It articulates with the pubic bone of the other side at the *symphysis pubis* (a secondary cartilaginous joint). The superior surface of the body bears the *pubic crest* and the *pubic tubercle* (Fig. 23.1).

The *obturator foramen* is a large opening bounded by the rami of the pubis and ischium.

### The sacrum and coccyx (Fig. 23.3)

- The sacrum comprises five fused vertebrae. The anterior and lateral aspects of the sacrum are termed the *central* and *lateral masses*, respectively. The upper anterior part is termed the *sacral promontory*. Four *anterior sacral foramina* on each side transmit the upper four sacral anterior primary rami. Posteriorly, the fused pedicles and laminae form the *sacral canal* representing a continuation of the vertebral canal. Inferiorly, the canal terminates at the *sacral hiatus*. *Sacral cornua* bound the hiatus inferiorly on either side. The subarachnoid space terminates at the level of S2. The sacrum is tilted anteriorly to form the *lumbosacral angle* with the lumbar vertebra.
- The coccyx articulates superiorly with the sacrum. It comprises between three and five fused rudimentary vertebrae.

### The obturator membrane

The obturator membrane is a sheet of fibrous tissue which covers the obturator foramen with the exception of a small area for the passage of the obturator nerve and vessels which traverse the canal to pass from the pelvis to gain access to the thigh.

### The pelvic cavity

The *pelvic brim* (also termed the pelvic inlet) separates the pelvis into the *false pelvis* (above) and the *true pelvis* (below). The brim is formed by the sacral promontory behind, the iliopectineal lines laterally and the symphysis pubis anteriorly. The *pelvic outlet* is bounded by the coccyx behind, the ischial tuberosities laterally and the *pubic arch* anteriorly. The true pelvis (pelvic cavity) lies between the inlet and outlet. The false pelvis is best considered as part of the abdominal cavity.

### The ligaments of the pelvis (Fig. 23.4)

These include the:

- **Sacro-tuberous ligament:** extends from the lateral part of the sacrum and coccyx to the ischial tuberosity.
- **Sacrospinous ligament:** extends from the lateral part of the sacrum and coccyx to the ischial spine.

The above ligaments, together with the sacro-iliac ligaments, bind the sacrum and coccyx to the os and prevent excessive movement at the sacro-iliac joints. In addition, these ligaments create the *greater* and *lesser sciatic foramina* with the greater and lesser sciatic notches.

### The pelvic floor (Fig. 23.5)

The pelvic floor muscles: support the viscera; produce a sphincter action on the rectum and vagina and help to produce increases in intra-abdominal pressure during straining. The rectum, urethra and vagina (in the female) traverse the pelvic floor to gain access to the exterior. The levator ani and coccygeus muscles form the pelvic floor, while piriformis covers the front of the sacrum.

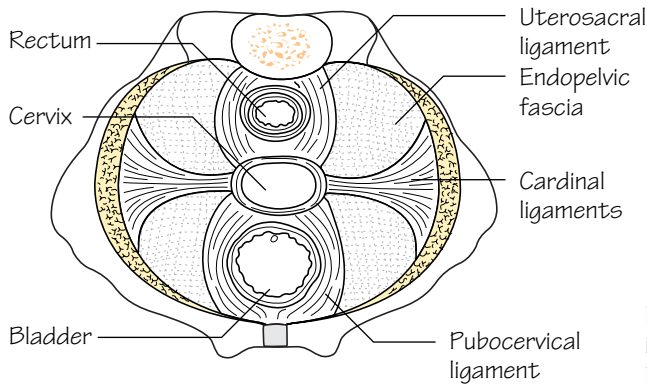
- **Levator ani:** arises from the posterior aspect of the pubis, the fascia overlying obturator internus on the side wall of the pelvis and the ischial spine. From this broad origin fibres sweep backwards towards the midline as follows:
  - **Anterior fibres** (*sphincter vaginae* or *levator prostatae*)—these fibres surround the vagina in the female (prostate in the male) and insert into the *perineal body*. The latter structure is a fibromuscular node which lies anterior to the anal canal.
  - **Intermediate fibres** (*puborectalis*)—these fibres surround the anorectal junction and also insert into the deep part of the anal sphincter. They provide an important voluntary sphincter action at the anorectal junction.
  - **Posterior fibres** (*iliococcygeus*)—these fibres insert into the lateral aspect of the coccyx and a median fibrous raphe (the anococcygeal body).
- **Coccygeus:** arises from the ischial spine and inserts into the lower sacrum and coccyx.

### Sex differences in the pelvis

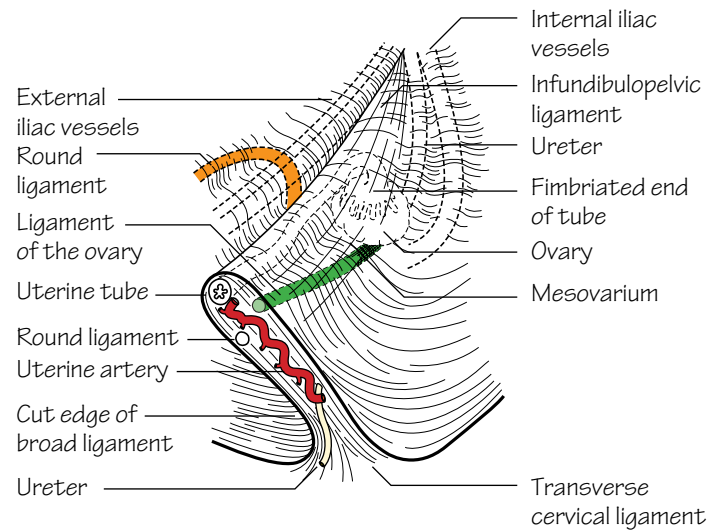
The female pelvis differs from that of the male for the purpose of child-bearing. The major sex differences include:

- 1 The pelvic inlet is oval in the female. In the male the sacral promontory is prominent, producing a heart-shaped inlet.
- 2 The pelvic outlet is wider in females as the ischial tuberosities are everted.
- 3 The pelvic cavity is more spacious in the female than in the male.
- 4 The false pelvis is shallow in the female.
- 5 The pubic arch (the angle between the inferior pubic rami) is wider and more rounded in the female when compared with that of the male.

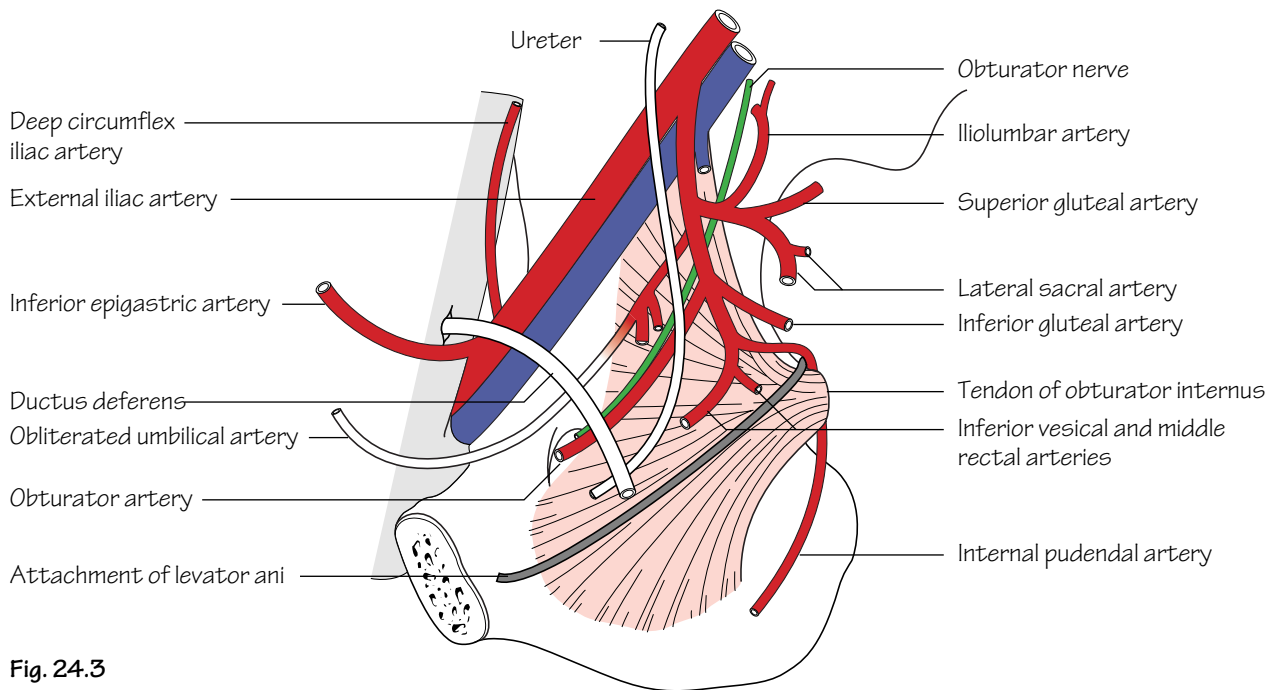
# 24 The pelvis II—the contents of the pelvis



**Fig. 24.1**  
The ligaments of the uterus



**Fig. 24.2**  
The broad ligament cut off close to the uterus



**Fig. 24.3**  
The pelvic arteries in the male

## Pelvic fascia (Fig. 24.1)

The *pelvic fascia* is the term given to the connective tissue that lines the pelvis covering levator ani and obturator internus. It is continuous with the fascial layers of the abdominal wall above and the perineum below. *Endopelvic fascia* is the term given to the loose connective tissue that covers the pelvic viscera. The endopelvic fascia is condensed into fascial ligaments which act as supports for the cervix and vagina. These ligaments include the:

- **Cardinal (Mackenrodt's) ligaments:** pass laterally from the cervix and upper vagina to the pelvic side walls.
- **Utero-sacral ligaments:** pass backwards from the cervix and vaginal fornices to the fascia overlying the sacro-iliac joints.
- **Pubocervical ligaments:** extend anteriorly from the cardinal ligaments to the pubis (puboprostatic in the male).
- **Pubovesical ligaments:** from the back of the symphysis pubis to the bladder neck.

## The broad and round ligaments (Fig. 24.2)

• **Broad ligament:** is a double fold of peritoneum which hangs between the lateral aspect of the uterus and the pelvic side walls. The ureter passes forwards under this ligament, but above and lateral to the lateral fornix of the vagina, to gain access to the bladder. The broad ligament contains the following structures:

- Fallopian tube.
  - Ovary.
  - Ovarian ligament.
  - Round ligament (see below).
  - Uterine and ovarian vessels.
  - Nerves and lymphatics.
- **Round ligament:** is a cord-like fibromuscular structure which is the female equivalent of the gubernaculum in the male. It passes from the lateral angle of the uterus to the labium majus by coursing in the broad ligament and then through the inguinal canal (p. 30).

## Arteries of the pelvis (Fig. 24.3)

- **Common iliac arteries:** arise from the aortic bifurcation to the left of the midline at the level of the umbilicus. These arteries, in turn, bifurcate into external and internal iliac branches anterior to the sacro-iliac joints on either side.
- **External iliac artery:** courses from its origin (described above) to become the femoral artery as it passes under the inguinal ligament at the mid-inguinal point. The external iliac artery gives rise to branches which supply the anterior abdominal wall. These include the: *deep cir-*

*cumflex iliac artery* and *inferior epigastric artery*. The latter branch gains access to the rectus sheath, which it supplies, and eventually anastomoses with the superior epigastric artery.

- **Internal iliac artery:** courses from its origin (described above) to divide into anterior and posterior trunks at the level of the greater sciatic foramen.

## Branches of the anterior trunk

- **Obturator artery:** passes with the obturator nerve through the obturator canal to enter the thigh.
- **Umbilical artery:** although the distal part is obliterated the proximal part is patent and gives rise to the *superior vesical artery* which contributes a supply to the bladder.
- **Inferior vesical artery:** as well as contributing a supply to the bladder it also gives off a *branch to the vas deferens* (in the male).
- **Middle rectal artery:** anastomoses with the superior and inferior rectal arteries to supply the rectum.
- **Internal pudendal artery:** is the predominant supply to the perineum. It exits the pelvis briefly through the greater sciatic foramen but then re-enters below piriformis through the lesser sciatic foramen to enter the pudendal canal together with the pudendal nerve.
- **Uterine artery:** passes medially on the pelvic floor and then over the ureter and lateral fornix of the vagina to ascend the lateral aspect of the uterus between the layers of the broad ligament.
- **Inferior gluteal artery:** passes out of the pelvis through the greater sciatic foramen to the gluteal region which it supplies.
- **Vaginal artery.**

## Branches of the posterior trunk

- **Superior gluteal artery:** contributes a supply to the gluteal muscles. It leaves the pelvis through the greater sciatic foramen.
- **Ilio-lumbar artery.**
- **Lateral sacral artery.**

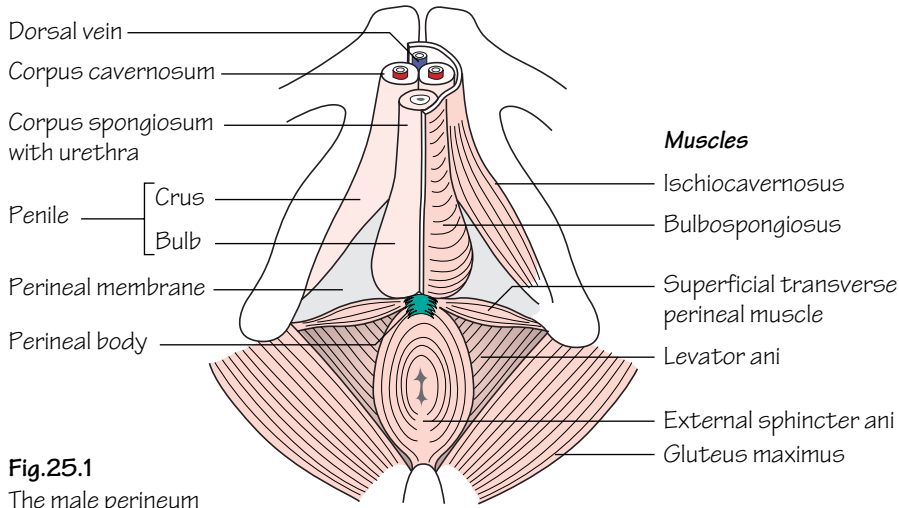
## Veins of the pelvis

The right and left common iliac veins join to form the inferior vena cava behind the right common iliac artery but anterolateral to the body of L5. The overall arrangement of pelvic venous drainage reciprocates that of the arterial supply.

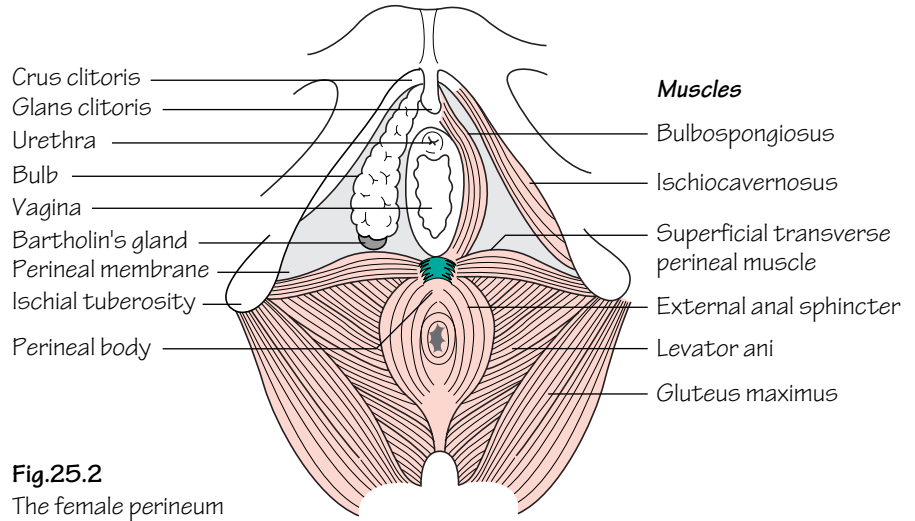
## Nerves of the pelvis

Sacral plexus (see p. 100).

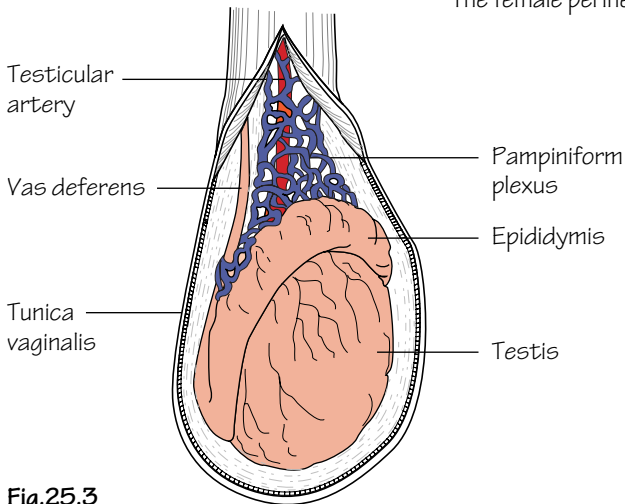
# 25 The perineum



**Fig.25.1**  
 The male perineum



**Fig.25.2**  
 The female perineum



**Fig.25.3**  
 The testis and epididymis



The perineum lies below the pelvic diaphragm. It forms a diamond-shaped area when viewed from below that can be divided into an anterior *urogenital* region and a posterior *anal* region by a line joining the ischial tuberosities horizontally.

### Anal region (Figs 25.1 and 17.2)

The anal region contains the anal canal and ischiorectal fossae.

- **Anal canal:** is described earlier (p. 43).
- **Anal sphincter:** comprises external and internal sphincter components. The *internal anal sphincter* is a continuation of the inner circular smooth muscle of the rectum. The *external anal sphincter* is a skeletal muscular tube which, at its rectal end, blends with puborectalis to form an area of palpable thickening termed the *anorectal ring*. The competence of the latter is fundamental to anal continence.
- **Ischiorectal fossae:** lie on either side of the anal canal. The medial and lateral walls of the ischiorectal fossa are the levator ani and anal canal and the obturator internus, respectively. The fossae are filled with fat. The anococcygeal body separates the fossae posteriorly; however, infection in one fossa can spread anteriorly to the contralateral fossa forming a horseshoe abscess. The *puddendal (Alcock's) canal* is a sheath in the lateral wall of the ischiorectal fossa. It conveys the pudendal nerve and internal pudendal vessels from the lesser sciatic notch to the deep perineal pouch (see below). The *inferior rectal branches* of the pudendal nerve and internal pudendal vessels course transversely across the fossa to reach the anus.

### Urogenital region

The urogenital region is triangular in shape. The *perineal membrane* is a strong fascial layer that is attached to the sides of the urogenital triangle. In the male it is pierced by the urethra and, in females, by the urethra and vagina.

#### (a) In the female (Fig. 25.2)

- **Vulva:** is the term given to the female external genitalia. The *mons pubis* is the fatty protuberance overlying the pubic symphysis and pubic bones. The *labia majora* are fatty hair-bearing lips that extend posteriorly from the mons. The *labia minora* lie internal to the labia majora and unite posteriorly at the *fourchette*. Anteriorly, the labia minora form the *prepuce* and split to enclose the *clitoris*. The clitoris corresponds to the penis in the male. It has a similar structure in that it is made up of three masses of erectile tissue: the bulb (corresponding to the penile bulb) and right and left crura covered by similar but smaller muscles than those in the male. As in the male, these form the contents of the superficial perineal pouch. The deep perineal pouch, however, contains the vagina as well as part of the urethra and sphincter urethrae and internal pudendal vessels. The *vestibule* is the area enclosed by the labia minora and contains the urethral and vaginal orifices. Deep to the posterior aspect of the labia majoris lie *Bartholin's glands*—a pair of mucus-secreting glands that drain anteriorly. They are not palpable in health but can become grossly inflamed when infected.
- **Urethra:** is short in the female (3–4 cm). This factor contributes towards the predisposition to urinary tract infection due to upward spread of bowel organisms. The urethra extends from the bladder neck to the external meatus. The meatus lies between the clitoris and vagina.
- **Vagina:** measures approximately 8–12 cm in length. It is a muscular tube that passes upwards and backwards from the vaginal orifice. The cervix projects into the upper anterior aspect of the vagina creating *fornices* anteriorly, posteriorly and laterally. Lymph from the upper vagina drains into the internal and external iliac nodes. Lymph from the

lower vagina drains to the superficial inguinal nodes. The blood supply to the vagina is from the *vaginal artery* (branch of the internal iliac artery) and the *vaginal branch of the uterine artery*.

#### (b) In the male (Fig. 25.1)

The external urethral sphincter (striated muscle) lies deep to the perineal membrane within a fascial capsule termed the *deep perineal pouch*. In addition to the sphincter, two *glands of Cowper* are also contained within the deep pouch. The ducts from these glands pass forwards to drain into the bulbous urethra. Inferior to the perineal membrane is the *superficial perineal pouch* which contains the:

- **Superficial transverse perineal muscles:** run from the perineal body to the ischial ramus.
- **Bulbo-spongiosus muscle:** covers the *corpus spongiosum*. The latter structure covers the spongy urethra.
- **Ischio-cavernosus muscle:** arises on each side from the ischial ramus to cover the *corpus cavernosum*. It is the engorgement of venous sinuses within these cavernosa that generate and maintain an erection.

Hence, the penile root comprises a well-vascularized bulb and two crura which are supplied by branches of the internal pudendal artery. The erectile penile tissue is enclosed within a tubular fascial sheath. At the distal end of the penis the corpus spongiosum expands to form the *glans penis*. On the tip of the glans the urethra opens as the *external urethral meatus*. The foreskin is attached to the glans below the meatus by a fold of skin—the *frenulum*.

### The scrotum

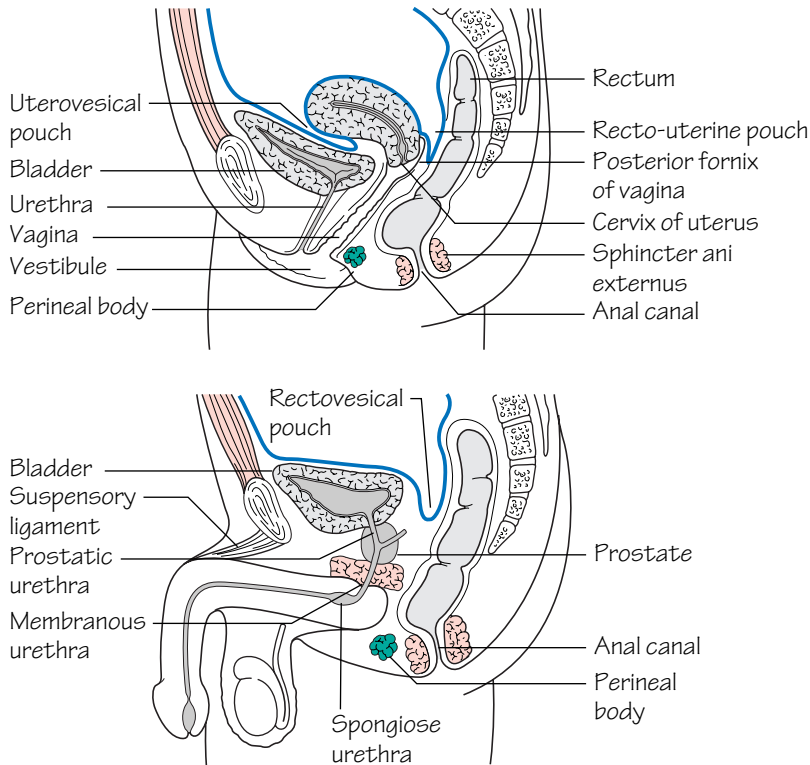
The skin of the scrotum is thin, rugose and contains many sebaceous glands. A longitudinal *median raphe* is visible in the midline. Beneath the skin lies a thin layer of involuntary *dartos* muscle. The terminal spermatic cords, the testes and their epididymes are contained within the scrotum.

### Testis and epididymis (Fig. 25.3)

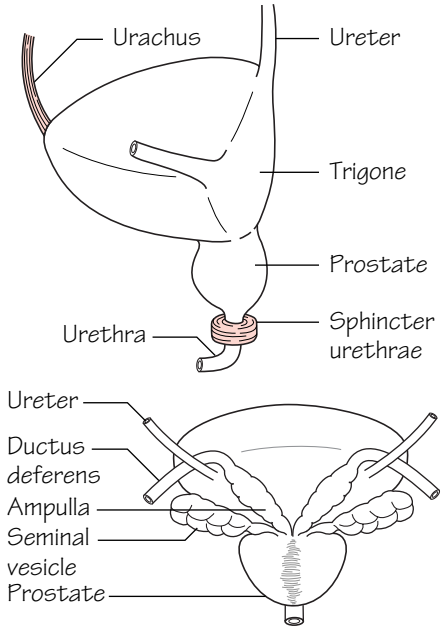
The testes are responsible for spermatogenesis. Their descent to an extra-abdominal position favours optimal spermatogenesis as the ambient scrotal temperature is approximately 3°C lower than body temperature.

- **Structure:** the testis is divided internally by a series of septa into approximately 200 lobules. Each lobule contains 1–3 *seminiferous tubules* which anastomose into a plexus termed the *rete testis*. Each tubule is coiled when *in situ*, but when extended measures approximately 60 cm. *Efferent ducts* connect the rete testis to the epididymal head. They serve to transmit sperm from the testicle to the epididymis.
  - The *tunica vaginalis*, derived from the peritoneum, is a double covering into which the testis is invaginated.
  - The *tunica albuginea* is a tough fibrous capsule that covers the testis.
  - The *epididymis* lies along the posterolateral and superior borders of the testicle. The tunica vaginalis covers the epididymis with the exception of the posterior border.
  - The upper poles of both the testis and epididymis bear an *appendix testis* and *appendix epididymis (hydatid of Morgagni)*, respectively.
- **Blood supply:** is from the testicular artery (a branch of the abdominal aorta, p. 32). Venous drainage from the testicle is to the pampiniform plexus of veins. The latter plexus lies within the spermatic cord but coalesces to form a single vein at the internal ring. The left testicular vein drains to the left renal vein whereas the right testicular vein drains directly to the inferior vena cava.
- **Lymphatic drainage:** is to the para-aortic lymph nodes.
- **Nerve supply:** is from T10 sympathetic fibres via the renal and aortic plexuses.

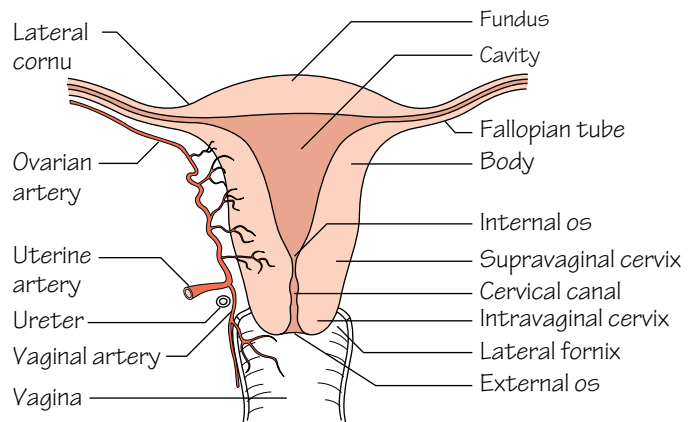
## 26 The pelvic viscera



**Fig.26.1**  
Sagittal sections through the male and female pelvis



**Fig.26.2**  
The bladder and prostate



**Fig.26.3**  
A vertical section through the uterus and vagina.  
Note the relation of the uterine artery to the ureter

### Contents of the pelvic cavity (see Fig. 24.1)

- **Sigmoid colon:** see p. 43.
- **Rectum:** see p. 43.
- **Ureters:** see p. 49.
- **Bladder** (Fig. 26.2): see below.

### Bladder

In adults the bladder is a pelvic organ. It lies behind the pubis and is covered superiorly by peritoneum. It acts as a receptacle for urine and has a capacity of approximately 500 mL.

- **Structure:** the bladder is pyramidal in shape. The *apex* of the pyramid points forwards and from it a fibrous cord, the *urachus*, passes upwards to the umbilicus as the *median umbilical ligament*. The *base* (posterior surface) is triangular. In the male, the seminal vesicles lie on the outer posterior surface of the bladder and are separated by the vas deferens. The rectum lies behind. In the female, the vagina intervenes between the bladder and rectum. The *inferolateral* surfaces are related inferiorly to the pelvic floor and anteriorly to the retropubic fat pad and pubic bones. The bladder *neck* fuses with the prostate in the male whereas it lies directly on the pelvic fascia in the female. The pelvic



fascia is thickened in the form of the *puboprostatic ligaments* (male) and *pubovesical ligaments* to hold the bladder neck in position. The mucous membrane of the bladder is thrown into folds when the bladder is empty with the exception of the membrane overlying the base (termed the *trigone*) which is smooth. The superior angles of the trigone mark the openings of the ureteric orifices. A muscular elevation, the *interureteric ridge*, runs between the ureteric orifices. The inferior angle of the trigone corresponds to the *internal urethral meatus*. The muscle coat of the bladder is composed of a triple layer of trabeculated smooth muscle known as the *detrusor* (muscle). The detrusor is thickened at the bladder neck to form the *sphincter vesicae*.

- **Blood supply:** is from the superior and inferior vesical arteries (branches of the internal iliac artery, p. 57). The vesical veins coalesce around the bladder to form a plexus that drains into the internal iliac vein.

- **Lymph drainage:** is to the para-aortic nodes.

- **Nerve supply:** motor input to the detrusor muscle is from efferent parasympathetic fibres from S2–4. Fibres from the same source convey inhibitory fibres to the internal sphincter so that co-ordinated micturition can occur. Conversely, sympathetic efferent fibres inhibit the detrusor and stimulate the sphincter.

## The male pelvic organs

### The prostate (Fig. 26.2)

In health the prostate is approximately the size of a walnut. It surrounds the prostatic urethra and lies between the bladder neck and the urogenital diaphragm. The apex of the prostate rests on the external urethral sphincter of the bladder. It is related anteriorly to the pubic symphysis but separated from it by extraperitoneal fat in the retropubic space (*cave of Retzius*). Posteriorly, the prostate is separated from the rectum by the *fascia of Denonvilliers*.

- **Structure:** the prostate comprises anterior, posterior, middle and lateral lobes. On rectal examination a posterior median groove can be palpated between the lateral lobes. The prostatic lobes contain numerous glands producing an alkaline secretion which is added to the seminal fluid at ejaculation. The prostatic glands open into the *prostatic sinus*. The *ejaculatory ducts*, which drain both the seminal vesicles and the vas, enter the upper part of the prostate and then the prostatic urethra at the *verumontanum*.

- **Blood supply:** is from the *inferior vesical artery* (branch of the internal iliac artery, p. 57). A prostatic plexus of veins is situated between the prostatic capsule and the outer fibrous sheath. The plexus receives the dorsal vein of the penis and drains into the internal iliac veins.

### The vas deferens

The vas deferens conveys sperm from the epididymis to the ejaculatory duct from which it can be passed to the urethra. The vas arises from the tail of the epididymis and traverses the inguinal canal to the deep ring, passes downwards on the lateral wall of the pelvis almost to the ischial tuberosity and turns medially to reach the base of the bladder where it joins with the duct of the seminal vesicle to form the ejaculatory duct.

### The seminal vesicles (Fig. 26.2)

The seminal vesicles consist of lobulated tubes which lie extraperitoneally on the bladder base lateral to the vas deferens.

### The urethra (Fig. 26.1)

The male urethra is approximately 20 cm long (4 cm in the female). It is considered in three parts:

- **Prostatic urethra** (3 cm): bears a longitudinal elevation (*urethral crest*) on its posterior wall. On either side of the crest a shallow depression, the *prostatic sinus*, marks the drainage point for 15–20 prostatic ducts. The *prostatic utricle* is a 5 mm blind ending tract which opens into an eminence in the middle of the crest—the *verumontanum*. The ejaculatory ducts open on either side of the utricle.

- **Membranous urethra** (2 cm): lies in the urogenital diaphragm and is surrounded by the external urethral sphincter (*sphincter urethrae*).

- **Penile urethra** (15 cm): traverses the corpus spongiosum of the penis (see perineum, p. 59) to the external urethral meatus.

## The female pelvic organs

### The vagina

See perineum, p. 59.

### The uterus and fallopian tubes (Fig. 26.3)

- **Structure:** the uterus measures approximately 8 cm in length in the nulliparous female. It comprises a: *fundus* (part lying above the entrance of the fallopian tubes), *body* and *cervix*. The cervix is sunken into the anterior wall of the vagina and is consequently divided into *supravaginal* and *vaginal* parts. The internal cavity of the cervix communicates with the cavity of the body at the *internal os* and with the vagina at the *external os*. The fallopian tubes lie in the free edges of the broad ligaments and serve to transmit ova from the ovary to the cornua of the uterus. They comprise an: *infundibulum*, *ampulla*, *isthmus* and *interstitial part*. The uterus is made up of a thick muscular wall (*myometrium*) and lined by a mucous membrane (*endometrium*). The endometrium undergoes massive cyclical change during menstruation.

- **Relations:** the uterus and cervix are related to the uterovesical pouch and superior surface of the bladder anteriorly. The recto-uterine pouch (of Douglas), which extends down as far as the posterior fornix of the vagina, is a posterior relation. The broad ligament is the main lateral relation of the uterus.

- **Position:** in the majority, the uterus is *anteverted*, i.e. the axis of the cervix is bent forward on the axis of the vagina. In some women the uterus is *retroverted*.

- **Blood supply:** is predominantly from the uterine artery (a branch of the internal iliac artery, p. 57). It runs in the broad ligament and, at the level of the internal os, crosses the ureter at right angles to reach, and supply, the uterus before anastomosing with the ovarian artery (a branch of the abdominal aorta, p. 32).

- **Lymph drainage:** lymphatics from the fundus accompany the ovarian artery and drain into the para-aortic nodes. Lymphatics from the body and cervix drain to the internal and external iliac lymph nodes.

### The ovary

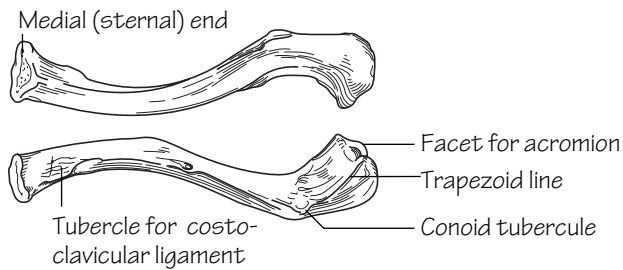
Each ovary contains a number of primordial follicles which develop in early fetal life and await full development into ova. In addition to the production of ova, the ovaries are also responsible for the production of sex hormones. Each ovary is surrounded by a fibrous capsule, the *tunica albuginea*.

- **Attachments:** the ovary lies next to the pelvic side wall and is secured in this position by two structures: the *broad ligament* which attaches the ovary posteriorly by the mesovarium; and the *ovarian ligament* which secures the ovary to the cornu of the uterus.

- **Blood supply:** is from the ovarian artery (a branch of the abdominal aorta). Venous drainage is to the inferior vena cava on the right and to the left renal vein on the left.

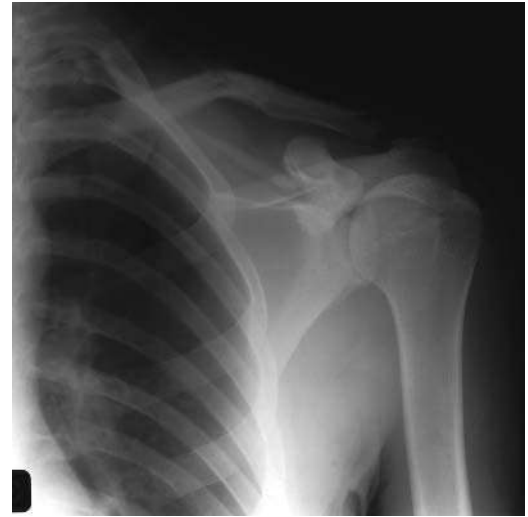- **Lymphatic drainage:** is to the para-aortic nodes.

## 27 The osteology of the upper limb



**Fig.27.1**

The upper and lower surfaces of the left clavicle



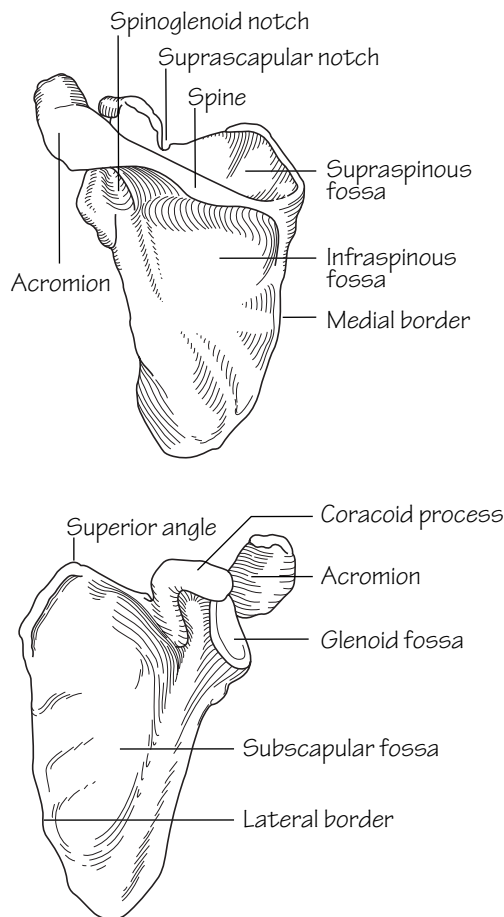
**Fig.27.2**

X-ray of a fractured clavicle

### The clavicle (Fig. 27.1)

- The clavicle is the first bone to ossify in the fetus (6 weeks).
- It develops in membrane and not in cartilage.
- It is subcutaneous throughout its length and transmits forces from the arm to the axial skeleton.
- The medial two-thirds are circular in cross-section and curved convex forwards. The lateral third is flat and curved convex backwards.
- The clavicle articulates medially with the sternum and 1st costal cartilage at the *sternoclavicular joint*. The clavicle is also attached medially to the 1st rib by strong *costoclavicular ligaments* and to the sternum by *sternoclavicular ligaments*.

- The clavicle articulates laterally with the acromion process of the scapula—the *acromioclavicular joint*. The *coracoclavicular ligaments* secure the clavicle inferolaterally to the coracoid process of the scapula. This ligament has two components—the *conoid* and *trapezoid ligaments* which are attached to the *conoid tubercle* and *trapezoid line* of the clavicle, respectively.
- The clavicle is the most commonly fractured bone in the body. The weakest point of the bone is the junction of the middle and outer thirds (Fig. 27.2).



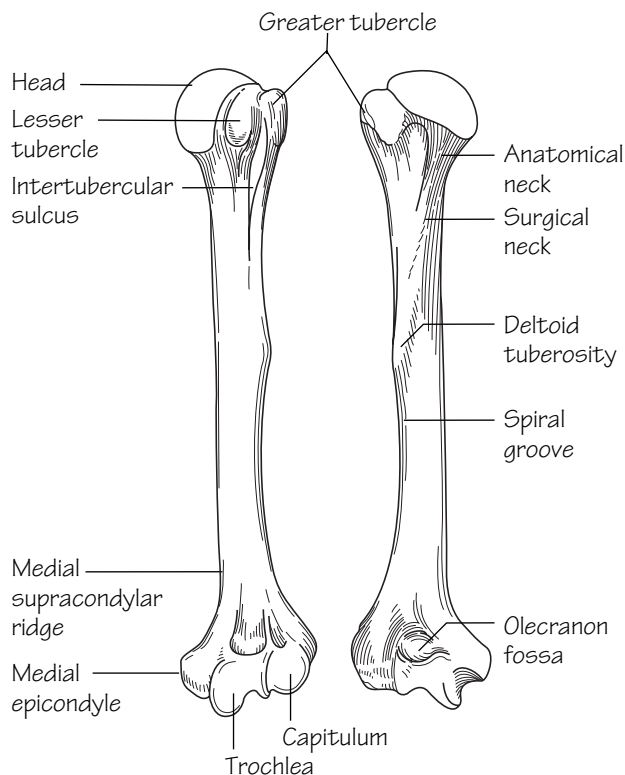
**Fig.27.3**  
Posterior and anterior views of the left scapula

### The scapula (Fig. 27.3)

- The scapula is triangular in shape. It provides an attachment for numerous muscles.
- The glenoid fossa articulates with the humeral head (gleno-humeral joint), and the acromion process with the clavicle (acromioclavicular joint).

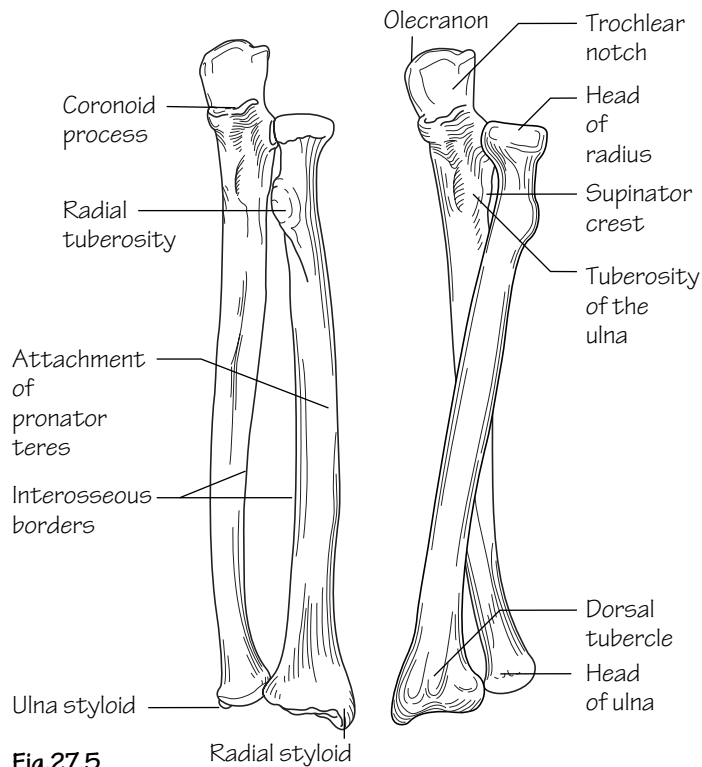
### The humerus (Fig. 27.4)

- The *humeral head* consists of one third of a sphere. The rounded head articulates with the shallow *glenoid*. This arrangement permits a wide range of shoulder movement.
- The *anatomical neck* separates the head from the greater and lesser tubercles. The *surgical neck* lies below the anatomical neck between the upper end of the humerus and shaft. The axillary nerve and circumflex vessels wind around the *surgical neck* of the humerus. These are at risk of injury in shoulder dislocations and humeral neck fractures (see Fig. 34.3).

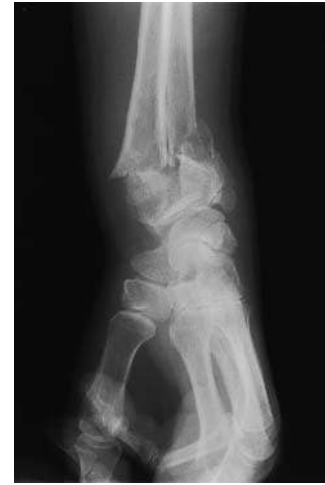

**Fig.27.4**  
Anterior and posterior views of the left humerus

- The *greater* and *lesser tubercles* provide attachment for the *rotator cuff* muscles. The tubercles are separated by the *intertubercular sulcus* in which the long head of biceps tendon courses.
- A faint *spiral groove* is visible on the posterior aspect of the humeral shaft traversing obliquely downwards and laterally. The *medial* and *lateral heads of triceps* originate on either side of this groove. The radial nerve passes between the two heads.
- The *ulnar nerve* winds forwards in a groove behind the *medial epicondyle*.
- At the elbow joint: the *trochlea* articulates with the *trochlear notch of the ulna*; and the rounded *capitulum* with the *radial head*. The medial border of the trochlea projects inferiorly a little further than the lateral border. This accounts for the *carrying angle*, i.e. the slight lateral angle made between the arm and forearm when the elbow is extended.



**Fig.27.5**  
The left radius and ulna in (a) supination and (b) pronation



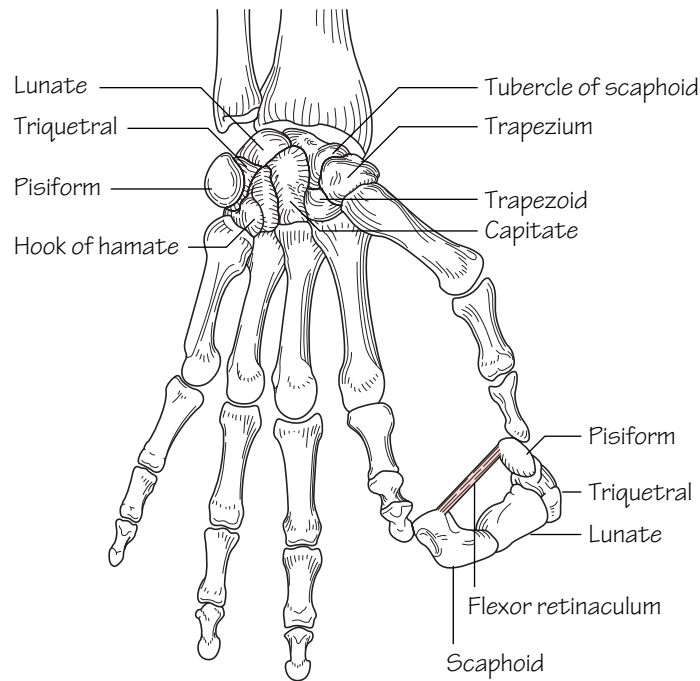
**Fig.27.6**  
X-ray of a fracture of the lower end of the radius (Colles' fracture)

### The radius and ulna (Fig. 27.5)

- Both the radius and ulna have *interosseous, anterior and posterior* borders.
- The *biceps tendon* inserts into the roughened posterior part of the *radial tuberosity*. The anterior part of the tuberosity is smooth where it is covered by a bursa.
- The *radial head* is at its proximal end whilst the *ulnar head* is at its distal end.
- The lower end of the radius articulates with the *scaphoid* and *lunate carpal bones* at the wrist joint. The distal ulna does not participate directly in the wrist joint.
- The *dorsal tubercle (of Lister)* is located on the posterior surface of the distal radius.

- In *pronation/supination* movements the radial head rotates in the radial notch of the ulna and the radial shaft pivots around the relatively fixed ulna (connected by the interosseous ligament). The distal radius rotates around the head of the ulna.

A *Colles fracture* is a common injury occurring at the wrist in the elderly and usually osteoporotic population. It classically follows a fall on the outstretched hand. The fracture line is usually about 2.5 cm proximal to the wrist and the distal fragment displaces posteriorly (*dinnerfork deformity* when viewed from the side) and radially. Some degree of shortening often occurs due to impaction of the component parts (Fig. 27.6).



**Fig.27.7**  
The skeleton of the left hand, holding a cross-section through the carpal tunnel

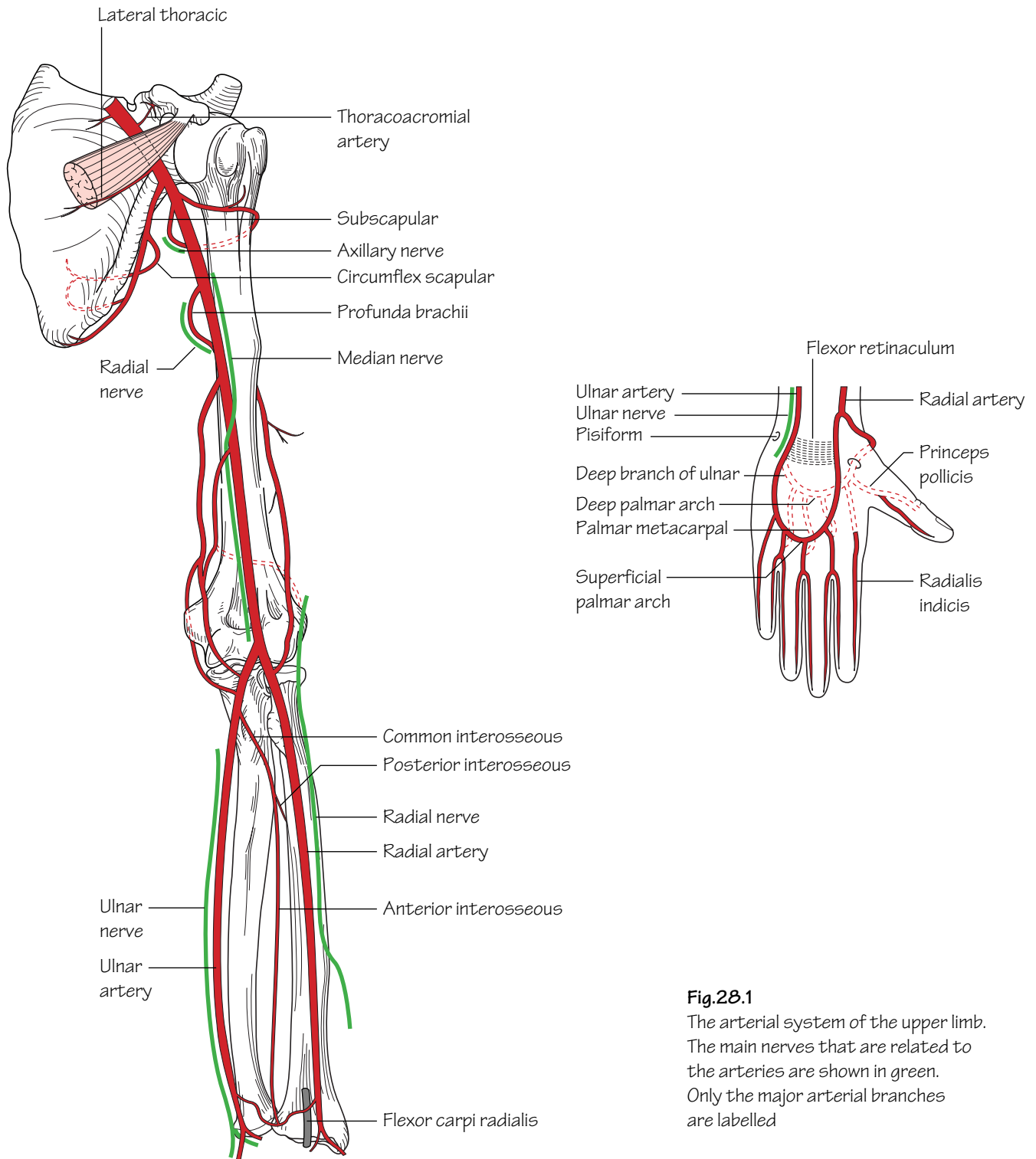
### The hand (Fig. 27.7)

The carpal bones are arranged into two rows. The palmar aspect of the carpus is concave. This is brought about by the shapes of the constituent bones and the *flexor retinaculum* bridging the bones anteriorly to form the *carpal tunnel* (see Fig. 38.1).

*The scaphoid may be fractured through a fall on the outstretched hand. This injury is common in young adults and must be suspected clinically when tenderness is elicited by deep palpation in the anatomi-*

*cal snuffbox. Radiographic changes are often not apparent and, if effective treatment is not implemented, permanent wrist weakness and secondary osteoarthritis may follow. The blood supply to the scaphoid enters via its proximal and distal ends. However, in as many as one third of cases the blood supply enters only from the distal end. Under these circumstances the proximal scaphoid fragment may be deprived of arterial supply and undergo avascular necrosis.*

## 28 Arteries of the upper limb



**Fig.28.1**

The arterial system of the upper limb. The main nerves that are related to the arteries are shown in green. Only the major arterial branches are labelled



## The axillary artery

• **Course:** the axillary artery commences at the lateral border of the 1st rib as a continuation of the subclavian artery (see Fig. 60.1) and ends at the *inferior border* of teres major where it continues as the *brachial artery*. The axillary vein is a medial relation throughout its course. It is crossed anteriorly by *pectoralis minor* which subdivides it into three parts:

- **First part** (medial to pectoralis minor).
- **Second part** (behind pectoralis minor)—gives off the *lateral thoracic artery* (which helps to supply the breast) and the *thoracoacromial artery* (p. 75).
- **Third part** (lateral to pectoralis minor)—gives off the *subscapular artery* which follows the lateral border of the scapula and gives off the *circumflex scapular artery*.

## The brachial artery

• **Course:** the brachial artery commences at the inferior border of teres major as a continuation of the axillary artery and ends by bifurcating into the radial and ulnar arteries at the level of the neck of the radius. It lies immediately below the deep fascia throughout its course. The brachial artery is crossed superficially by the median nerve in the mid-arm from lateral to medial and hence lies between the median nerve (medial relation) and biceps tendon (lateral relation) in the cubital fossa (see Fig. 36.3).

- **Branches:**
  - **Profunda brachii**—arises near the origin of the brachial artery and winds behind the humerus with the radial nerve in the spiral groove before taking part in the anastomosis around the elbow joint.
  - **Other branches**—include a *nutrient artery* to the humerus and *superior* and *inferior ulnar collateral* branches which ultimately take part in the anastomosis around the elbow.

*'Volkman's ischaemic contracture' is a deformity arising as a result of brachial artery spasm following injury (usually from fractures of the distal humerus). The reduced arterial flow results in ischaemic necrosis of the forearm musculature which is eventually replaced by shortened fibrous tissue. In the classical deformity the forearm is wasted and the wrist joint flexed with the fingers extended. When the wrist is extended the fingers flex.*

## The radial artery

• **Course:** the radial artery arises at the level of the neck of the radius from the bifurcation of the brachial artery. It passes over the biceps tendon to lie firstly on supinator then descends on the radial side of the forearm, lying under the edge of brachioradialis in the upper half of its course and then between the tendons of brachioradialis and flexor carpi radialis in the lower forearm. The radial artery passes sequentially over supinator, pronator teres, the radial head of flexor digitorum superficialis, flexor pollicis longus and pronator quadratus. At the wrist

the artery lies on the distal radius lateral to the tendon of flexor carpi radialis. This is where the radial pulse is best felt.

- **Branches:**
  - *Palmar* and *dorsal carpal branches* are given off at the wrist.
  - A *superficial palmar branch* arises at the wrist which supplies the thenar muscles and consequently anastomoses with the superficial palmar branch of the ulnar artery to form the *superficial palmar arch*.
  - The radial artery passes backwards under the tendons of abductor pollicis longus and extensor pollicis brevis to enter the *anatomical snuffbox*. It consequently passes over the scaphoid and trapezium in the snuffbox and exits by passing between the two heads of adductor pollicis to enter the palm and forms the *deep palmar arch* with a contribution from the ulnar artery (*deep palmar branch*). It gives off the *princeps pollicis* to the thumb and the *radialis indicis* to the index finger.
  - The deep palmar arch gives off three *palmar metacarpal arteries* which subsequently join the *common palmar digital arteries* (from the superficial arch) to supply the digits.

## The ulnar artery

• **Course:** the ulnar artery commences as the terminal bifurcation of the brachial artery at the level of the neck of the radius. It passes deep to the deep head of pronator teres and deep to the fibrous arch of flexor digitorum superficialis and descends on flexor digitorum profundus with the ulnar nerve lying medial to it and flexor carpi ulnaris overlapping it in the proximal half of the forearm.

At the wrist both the ulnar artery and nerve lie lateral (radial) to flexor carpi ulnaris and pass *over* the flexor retinaculum giving carpal branches which contribute to the *dorsal* and *palmar carpal arches*.

- **Branches:**
  - A *deep palmar branch* completes the deep palmar arch (see above) and the ulnar artery continues as the *superficial palmar arch* which is completed by the superficial palmar branch of the radial artery.
  - The *common interosseous artery* (see below).

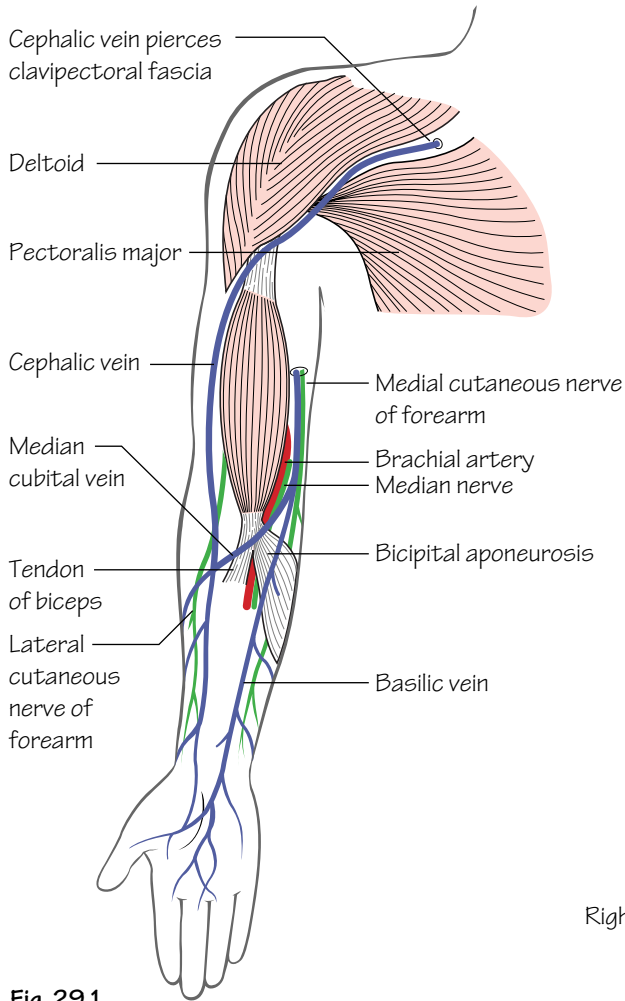
## The common interosseous artery

The common interosseous artery is the first ulnar branch to arise and it subdivides into the:

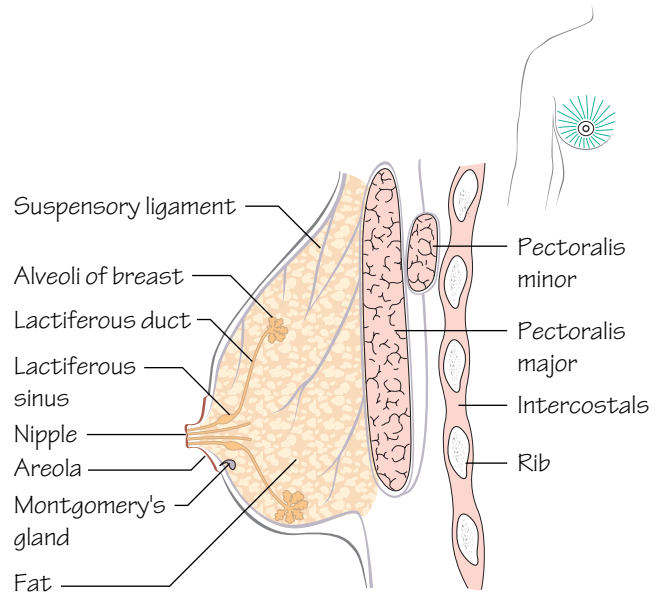
- *Anterior interosseous artery:* descends with the interosseous branch of the median nerve on the anterior surface of the interosseous membrane. It predominantly supplies the flexor compartment of the forearm.
- *Posterior interosseous artery:* passes above the upper border of the interosseous membrane to enter the extensor compartment where it runs with the deep branch of the radial nerve supplying the extensor muscles of the forearm, eventually anastomosing with the anterior interosseous artery.



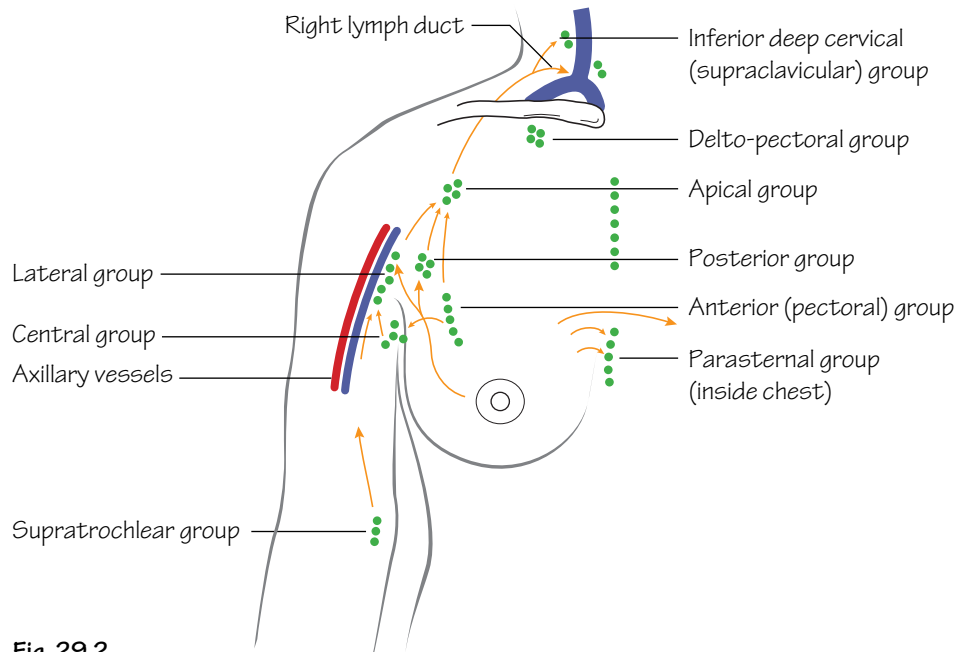
# 29 The venous and lymphatic drainage of the upper limb and the breast



**Fig. 29.1**  
The superficial venous system of the upper limb and two major cutaneous nerves



**Fig. 29.3**  
A section through the breast to show its major relations. The inset shows the radial arrangement of the lactiferous ducts



**Fig. 29.2**  
The lymph nodes of the axilla and the lymphatic drainage of the breast

## Venous drainage of the upper limb (Fig. 29.1)

As in the lower limb the venous drainage comprises interconnected superficial and deep systems.

- **The superficial system:** comprises the *cephalic* and *basilic veins*.
  - The *cephalic vein* commences from the lateral end of the *dorsal venous network* overlying the anatomical snuffbox. It ascends the lateral, then anterolateral, aspects of the forearm and arm and finally courses in the deltopectoral groove to pierce the clavipectoral fascia and drain into the axillary vein.
  - The *basilic vein* commences from the medial end of the dorsal venous network. It ascends along the medial then anteromedial aspects of the forearm and arm to pierce the deep fascia (in the region of the mid-arm) to join with the *venae comitantes of the brachial artery* to form the *axillary vein*.

The two superficial veins are usually connected by a median cubital vein in the cubital fossa.

- **The deep veins:** consist of *venae comitantes* (veins which accompany arteries).

The superficial veins of the upper limb are of extreme clinical importance for phlebotomy and peripheral venous access. The most commonly used sites are the *median cubital vein* in the antecubital fossa and the *cephalic vein* in the forearm.

## Lymphatic drainage of the chest wall and upper limb (Fig. 29.2)

Lymph from the chest wall and upper limb drains centrally via axillary, supratrochlear and infraclavicular lymph nodes.

### Axillary lymph node groups

There are approximately 30–50 lymph nodes in the axilla. They are arranged into five groups:

- **Anterior (pectoral) group:** these lie along the anterior part of the medial wall of the axilla. They receive lymph from the upper anterior part of the trunk wall and breast.
- **Posterior (subscapular) group:** these lie along the posterior part of the medial wall of the axilla. They receive lymph from the upper posterior trunk wall down as far as the iliac crest.
- **Lateral group:** these lie immediately medial to the axillary vein. They receive lymph from the upper limb and the breast.
- **Central group:** these lie within the fat of the axilla. They receive lymph from all of the groups named above.
- **Apical group:** these lie in the apex of the axilla. They receive lymph from all of the groups mentioned above. From here lymph is passed to the *thoracic duct* (on the left) or *right lymphatic trunks* (see Fig. 3.3), with some passing to the *inferior deep cervical (supraclavicular) group*.

### Lymph node groups in the arm

- The *supratrochlear group* of nodes lie subcutaneously above the

medial epicondyle. They drain lymph from the ulnar side of the forearm and hand. Lymph from this group passes to the *lateral group* of axillary lymph nodes and thence drains centrally.

- A small amount of lymph from the radial side of the upper limb drains directly into the *infraclavicular group* of nodes. This group is arranged around the cephalic vein in the deltopectoral groove. From this point the efferent vessels pass through the clavipectoral fascia to drain into the *apical group* of axillary nodes and thence centrally.

*This information can be applied to the clinical scenario. If a patient presents with an infected insect bite of the thumb, the infraclavicular nodes would reactively enlarge. If, however, infection occurred on the patient's little finger, lymphadenopathy of the supratrochlear nodes would result.*

## The breast (Fig. 29.3)

The breasts are present in both sexes and have similar characteristics until puberty when, in the female, they enlarge and develop the capacity for milk production. The breasts are essentially specialized skin glands comprising fat, glandular and connective tissue. The base of the breast lies in a constant position on the anterior chest wall. It extends from the 2nd to 6th ribs anteriorly and from the lateral edge of the sternum to the mid-axillary line laterally. A part of the breast, the *axillary tail*, extends laterally through the deep fascia beneath pectoralis to enter the axilla. Each breast comprises 15–30 functional ducto-lobular units arranged radially around the nipple. The lobes are separated by fibrous septa (*suspensory ligaments*) which pass from the deep fascia to the overlying skin thereby giving the breast structure. A lactiferous duct arises from each lobe and converges on the nipple. In its terminal portion the duct is dilated (*lactiferous sinus*) and thence continues to the nipple from where milk can be expressed. The *areola* is the darkened skin that surrounds the nipple. Its surface is usually irregular due to multiple small tubercles—*Montgomery's glands*.

- **Blood supply:** is from the perforating branches of the internal thoracic artery (p. 13) and the lateral thoracic and thoracoacromial branches of the axillary artery (p. 67). The venous drainage corresponds to the arterial supply.
- **Lymphatic drainage:** from the lateral half of the breast is to the anterior axillary nodes. Lymph from the medial breast drains into the internal mammary nodes (adjacent to the internal thoracic vessels beneath the chest wall).

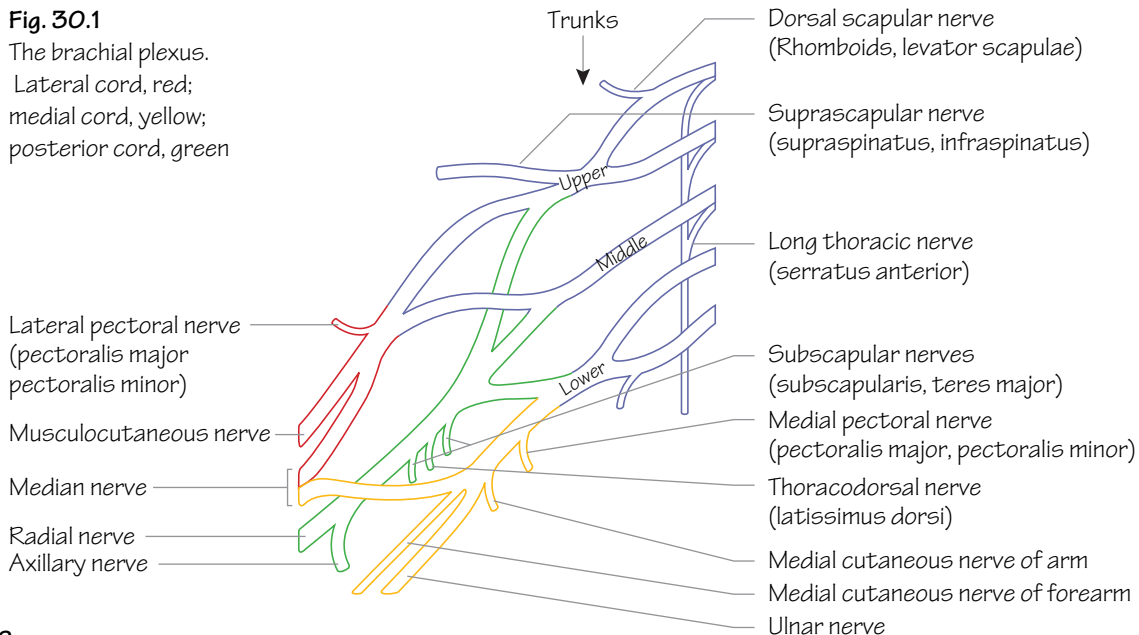
## Lymph drainage in carcinoma of the breast

*The axillary lymph nodes represent an early site of metastasis from primary breast malignancies and their surgical removal and subsequent examination provide important prognostic information as well as a basis for choice of adjuvant treatment. Damage to axillary lymphatics during surgical clearance of axillary nodes or resulting from radiotherapy to the axilla increases the likelihood of subsequent upper limb lymphoedema.*

# 30 Nerves of the upper limb I

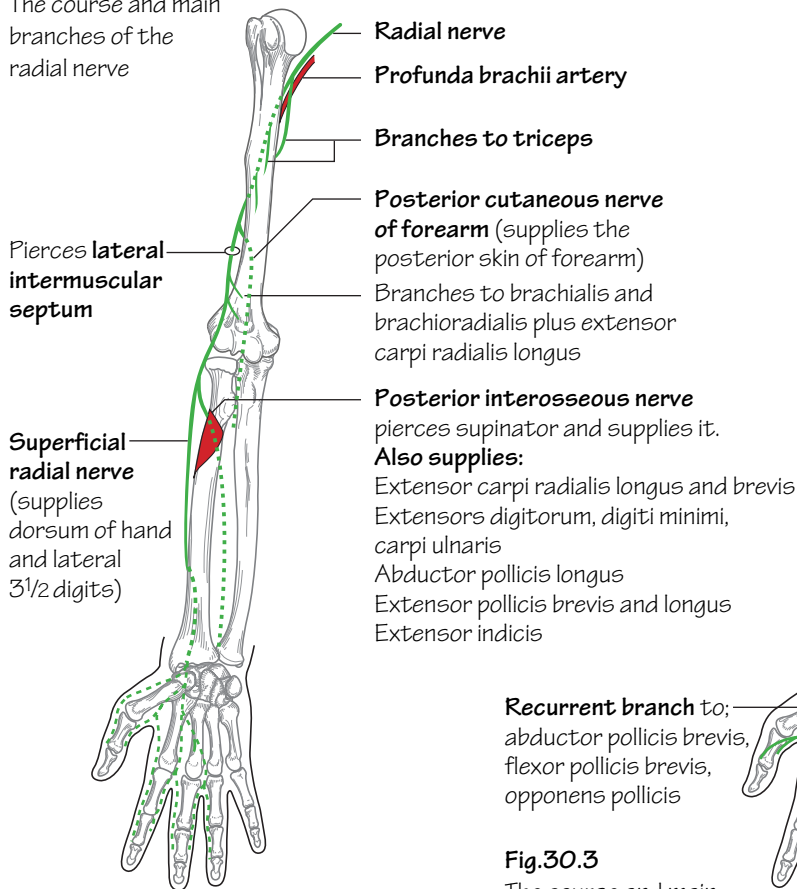
**Fig. 30.1**

The brachial plexus.  
Lateral cord, red;  
medial cord, yellow;  
posterior cord, green



**Fig. 30.2**

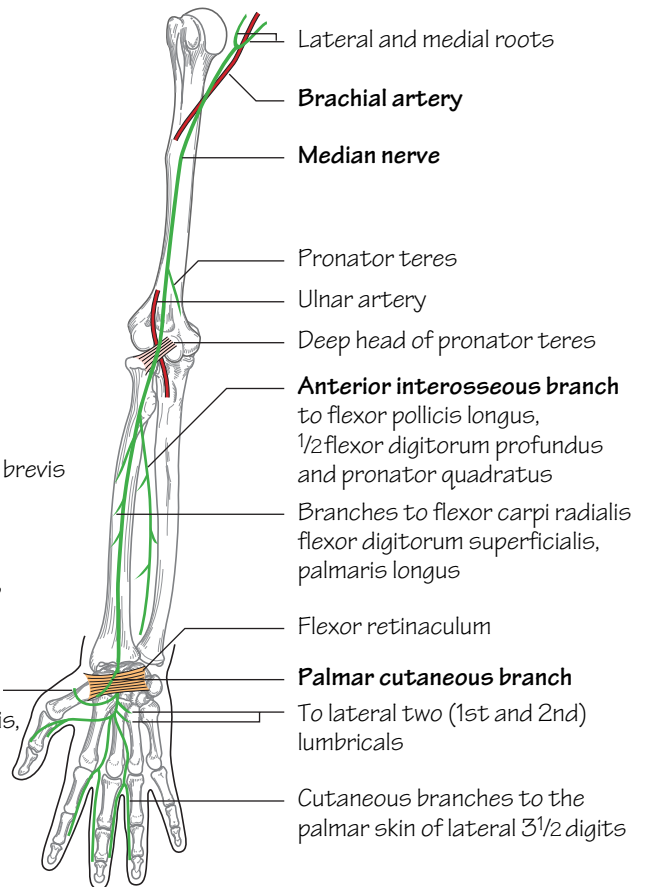
The course and main branches of the radial nerve



**Recurrent branch to:** abductor pollicis brevis, flexor pollicis brevis, opponens pollicis

**Fig. 30.3**

The course and main branches of the median nerve



### The brachial plexus (C5,6,7,8,T1) (Fig. 30.1)

- The plexus arises as five *roots*. These are the anterior primary rami of C5,6,7,8,T1. The roots lie between scalenus anterior and scalenus medius.
- The three *trunks* (upper, middle and lower) lie in the posterior triangle of the neck. They pass over the 1st rib to lie behind the clavicle.
- The *divisions* form behind the middle third of the clavicle around the axillary artery.
- The *cords* lie in the axilla and are related medially, laterally and posteriorly to the second part of the axillary artery.
- Terminal nerves arise from the cords surrounding the third part of the axillary artery.

### The axillary nerve (C5,6)

- **Type:** mixed sensory and motor nerve.
- **Origin:** it arises from the *posterior cord* of the brachial plexus.
- **Course:** it passes through the quadrangular space with the posterior circumflex humeral artery. It provides: a motor supply to deltoid and teres minor; a sensory supply to the skin overlying deltoid; and an articular branch to the shoulder joint.
- **Effect of injury:** the axillary nerve is particularly prone to injury from the downward displacement of the humeral head during shoulder dislocations.
  - *Motor deficit*—loss of deltoid abduction with rapid wasting of this muscle. Loss of teres minor function is not detectable clinically.
  - *Sensory deficit*—is limited to the ‘badge’ region overlying the lower half of deltoid.

### The radial nerve (C5,6,7,8,T1) (Fig. 30.2)

- **Type:** mixed sensory and motor.
- **Origin:** it arises as a continuation of the posterior cord of the brachial plexus.
- **Course and branches:** it runs with the profunda brachii artery between the long and medial heads of triceps into the posterior compartment and down between the medial and lateral heads of triceps. At the midpoint of the arm it enters the anterior compartment by piercing the lateral intermuscular septum. In the region of the lateral epicondyle the radial nerve lies under the cover of brachioradialis and divides into the superficial radial and posterior interosseous nerves.

The branches of the radial nerve include: *branches to triceps, brachioradialis and brachialis* as well as some cutaneous branches. It terminates by dividing into two major nerves:

- The *posterior interosseous nerve*—passes between the two heads of supinator at a point three fingerbreadths distal to the radial head thus passing into the posterior compartment. It supplies the extensor muscles of the forearm.
- The *superficial radial nerve*—descends the forearm under the cover of brachioradialis with the radial artery on its medial side. It termin-

ates as cutaneous branches supplying the skin of the back of the wrist and hand.

- **Effect of injury** (Fig. 31.2): e.g. humeral shaft fracture resulting in damage to the radial nerve in the spiral groove.
  - *Motor deficit*—loss of all forearm extensors: wristdrop.
  - *Sensory deficit*—usually small due to overlap: sensory loss over the anatomical snuffbox is usually constant.

### The musculocutaneous nerve (C5,6,7)

- **Type:** mixed sensory and motor.
- **Origin:** it arises from the lateral cord of the brachial plexus.
- **Course:** it passes laterally through the two conjoined heads of coracobrachialis and then descends the arm between brachialis and biceps, supplying all three of these muscles en route. It pierces the deep fascia just below the elbow (and becomes the *lateral cutaneous nerve of the forearm*). Here it supplies the skin of the lateral forearm as far as the wrist.

### The median nerve (C6,7,8,T1) (Fig. 30.3)

- **Type:** mixed sensory and motor.
- **Origin:** it arises from the confluence of two roots from the medial and lateral cords lateral to the axillary artery in the axilla.
- **Course and branches:** the median nerve initially lies lateral to the brachial artery but crosses it medially in the mid-arm. In the cubital fossa it lies medial to the brachial artery which lies medial to the bicipital tendon. The median nerve passes deep to the bicipital aponeurosis then between the two heads of pronator teres. A short distance below this the *anterior interosseous branch* is given off. This branch descends with the anterior interosseous artery to supply the deep muscles of the flexor compartment of the forearm except for the ulnar half of flexor digitorum profundus. In the forearm the median nerve lies between flexor digitorum superficialis and flexor digitorum profundus and supplies the remaining flexors except for flexor carpi ulnaris. A short distance above the wrist it emerges from the lateral side of flexor digitorum superficialis and gives off the *palmar cutaneous branch* which provides a sensory supply to the skin overlying the thenar eminence.

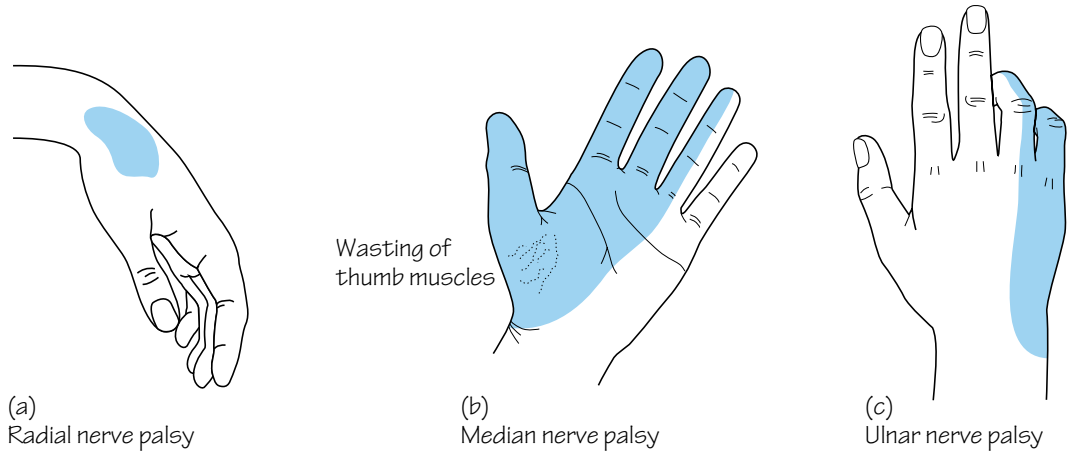
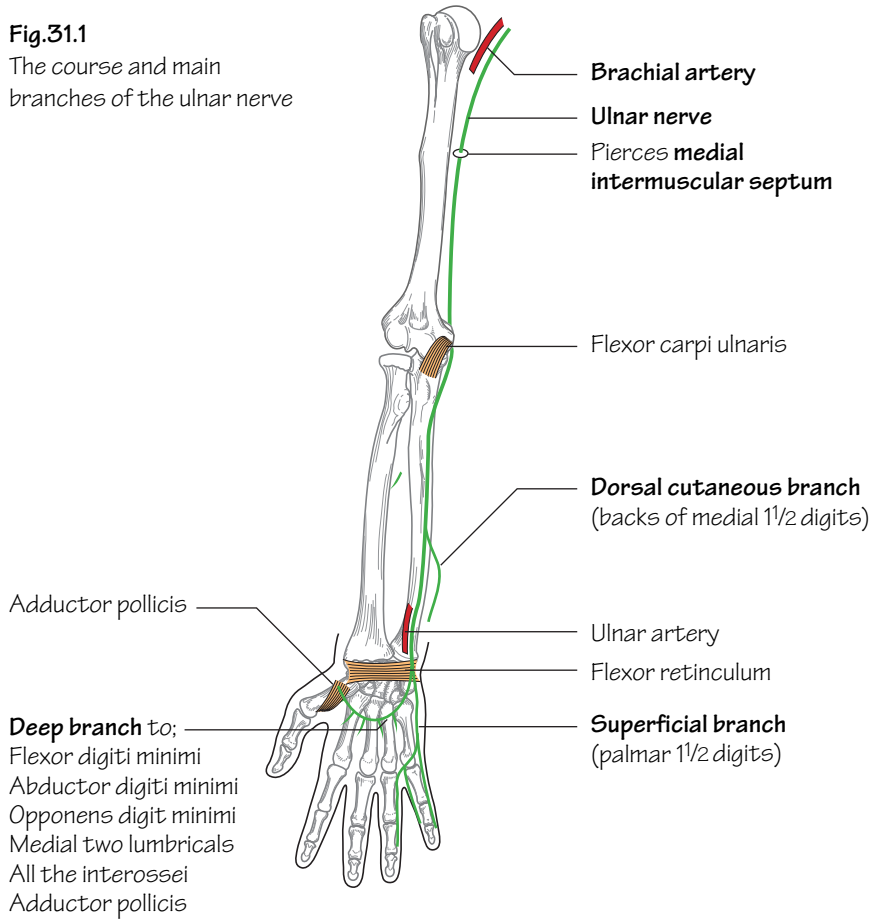
At the wrist the median nerve passes beneath the flexor retinaculum (i.e. through the carpal tunnel) in the midline and divides here into its terminal branches: the *recurrent branch* to the muscles of the thenar eminence (but not adductor pollicis); the *branches to the 1st and 2nd lumbricals*; and the *cutaneous supply* to the palmar skin of the thumb, index, middle and lateral half of the ring fingers.

- **Effect of injury** (see Fig. 31.2): e.g. compression as in carpal tunnel syndrome.
  - *Motor deficit*—weakness and wasting of the thenar muscles.
  - *Sensory deficit*—involves the skin over the lateral palm and lateral three digits. This is highly variable due to overlap.

# 31 Nerves of the upper limb II

**Fig.31.1**

The course and main branches of the ulnar nerve



**Fig.31.2**

Some common nerve palsies and the associated areas of altered sensation. These are very variable

### The ulnar nerve (C8, T1) (Fig. 31.1)

- **Type:** mixed sensory and motor.
- **Origin:** from the medial cord of the brachial plexus.
- **Course and branches:** it runs on coracobrachialis to the mid-arm where it pierces the medial intermuscular septum with the superior ulnar collateral artery to enter the posterior compartment. It winds under the medial epicondyle and passes between the two heads of flexor carpi ulnaris to enter the forearm and supplies flexor carpi ulnaris and half of flexor digitorum profundus. In the lower forearm the artery lies lateral to the ulnar nerve and the tendon of flexor carpi ulnaris. Here *dorsal* and *palmar cutaneous branches* are given off. The ulnar nerve passes superficial to the flexor retinaculum and subsequently divides into terminal branches. These are:
  - The *superficial terminal branch*—terminates as terminal digital nerves supplying the skin of the little and medial half of the ring fingers.
  - The *deep terminal branch*—supplies the hypothenar muscles as well as two lumbricals, the interossei and adductor pollicis.
- **Effect of injury** (Fig. 31.2): occurs commonly at the elbow (e.g. fracture of the medial epicondyle) or at the wrist due to a laceration.
  - **Motor deficit**—with low lesions the hand becomes ‘clawed’. Owing to the loss of interossei and lumbrical function the metacarpophalangeal joints of the ring and little fingers hyperextend and their interphalangeal joints flex. The ‘clawing’ is attributed to the unopposed action of the extensors and flexor digitorum profundus. When injury occurs at the elbow or above, the ring and little fingers are straighter because the ulnar supply to flexor digitorum profundus is lost. The small muscles of the hand waste with the exception of the thenar and lateral two lumbrical muscles (supplied by the median nerve).
  - **Sensory deficit**—occurs to the palmar and dorsal surfaces of the hand and medial 1½ digits. The loss is highly variable due to overlap.

### Other branches of the brachial plexus

#### Supraclavicular branches

- **Suprascapular nerve (C5,6):** passes through the suprascapular notch to supply supra- and infraspinatus muscles.
- **Long thoracic nerve (of Bell) (C5,6,7):** supplies serratus anterior.

#### Infraclavicular branches

- **Medial and lateral pectoral nerves:** supply pectoralis major and minor.
- **Medial cutaneous nerves of the arm and forearm.**
- **Thoracodorsal nerve (C6,7,8):** supplies latissimus dorsi.
- **Upper and lower subscapular nerves:** supply subscapularis and teres major.

### Brachial plexus injuries

#### Erb–Duchenne paralysis

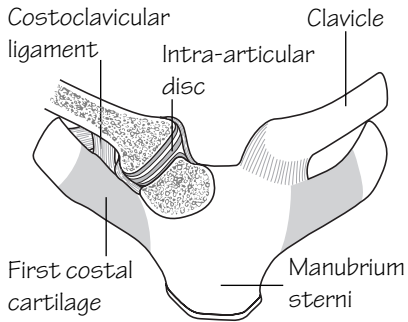
*Excessive downward traction on the upper limb during birth can result in injury to the C5 and C6 roots. This results in paralysis of the deltoid, the short muscles of the shoulder, brachialis and biceps. The combined effect is that the arm hangs down by the side with the forearm pronated and the palm facing backwards. This has been termed the ‘waiter’s tip’ position.*

#### Klumpke’s paralysis

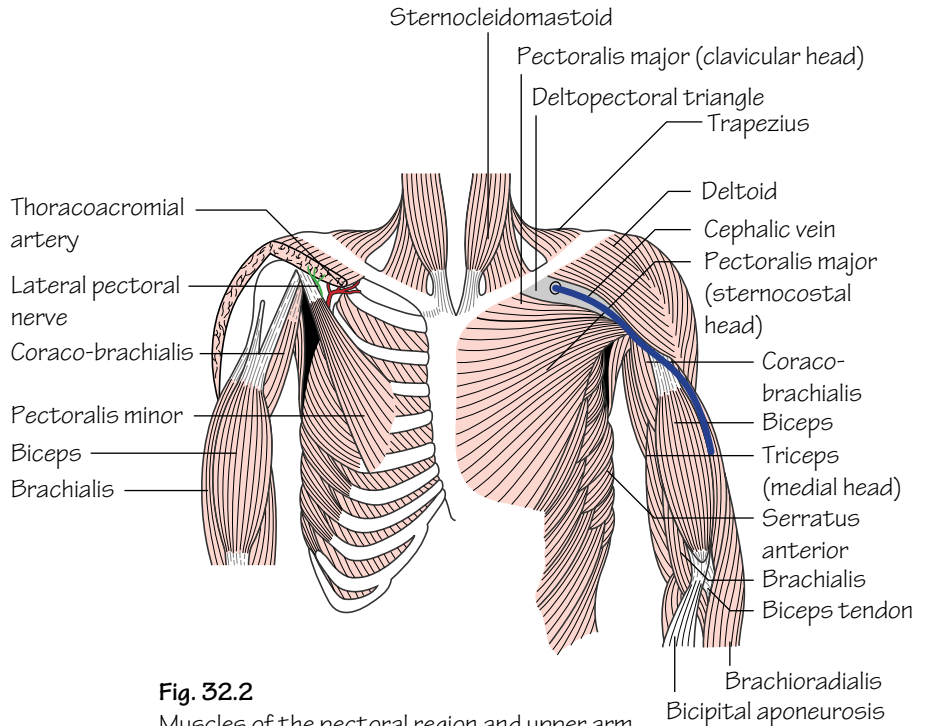
*Excessive upward traction on the upper limb can result in injury to the T1 root. As the latter is the nerve supply to the intrinsic muscles of the hand this injury results in ‘clawing’ (extension of the metacarpophalangeal joints and flexion of the interphalangeal joints) due to the unopposed action of the long flexors and extensors of the fingers. There is often an associated Horner’s syndrome (ptosis, pupillary constriction and ipsilateral anhidrosis) as the traction injury often involves the cervical sympathetic chain.*



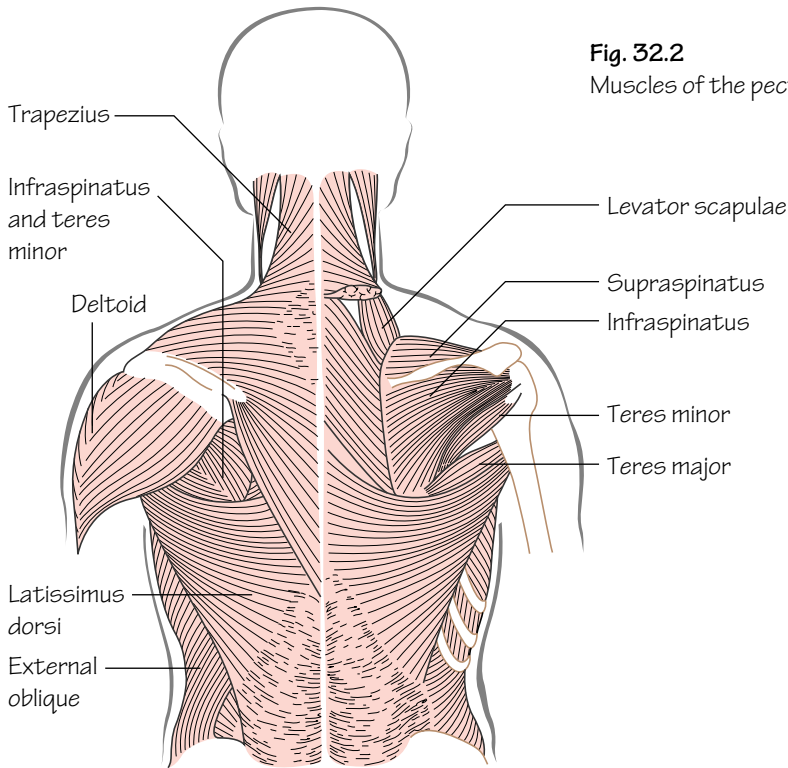
## 32 The pectoral and scapular regions



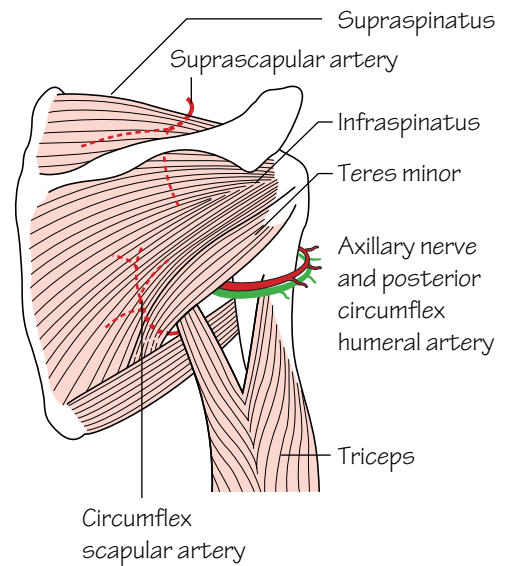
**Fig. 32.1**  
The sterno-clavicular joint



**Fig. 32.2**  
Muscles of the pectoral region and upper arm



**Fig. 32.3**  
Muscles of the scapular region and back



**Fig. 32.4**  
The triangular and quadrangular spaces



The upper limb is attached to the axial skeleton by way of the scapula and clavicle. It should be noted that this involves only two small joints—the *acromioclavicular* and *sternoclavicular joints*. The main attachment between the upper limb and the axial skeleton is muscular.

### The muscles of the outer chest wall (Figs 32.2 and 32.3)

See Muscle index, p. 162.

- Muscles of the outer anterior chest wall include *pectoralis major* and *pectoralis minor*.
- Muscles of the back and shoulder include: *latissimus dorsi*, *trapezius*, *deltoid*, *levator scapulae*, *serratus anterior*, *teres major and minor*, *rhomboids major and minor*, *subscapularis*, *supraspinatus* and *infraspinatus*.

### The sternoclavicular joint (Fig. 32.1)

- **Type:** *atypical synovial joint*.
- The articulation is between the sternal end of the clavicle and the manubrium. The articular surfaces are covered with fibrocartilage as opposed to the usual hyaline.
- A fibrocartilaginous *articular disc* separates the joint into two cavities.
- The fulcrum of movement at this joint is the *costoclavicular ligament*, i.e. when the lateral end of the clavicle moves upwards the medial end moves downwards.

### The acromioclavicular joint

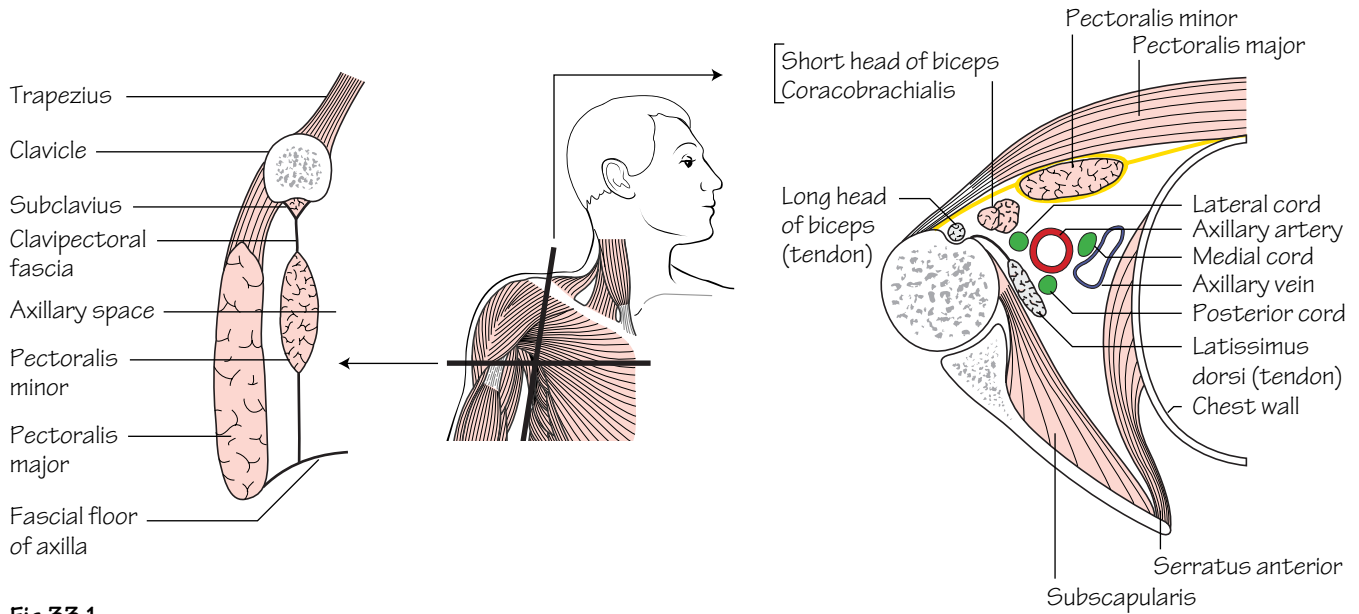
- **Type:** *atypical synovial joint*.
- The articulation is between the lateral end of the clavicle and the medial border of the acromion. As for the sternoclavicular joint, the articular surfaces are covered with fibrocartilage and an *articular disc* hangs into the joint from above.

- This is a weak joint. The main bond between the clavicle and the scapula is the *coracoclavicular ligament* (see Fig. 34.1).

### The deltopectoral triangle, clavipectoral fascia and the anatomical spaces (Fig. 32.2)

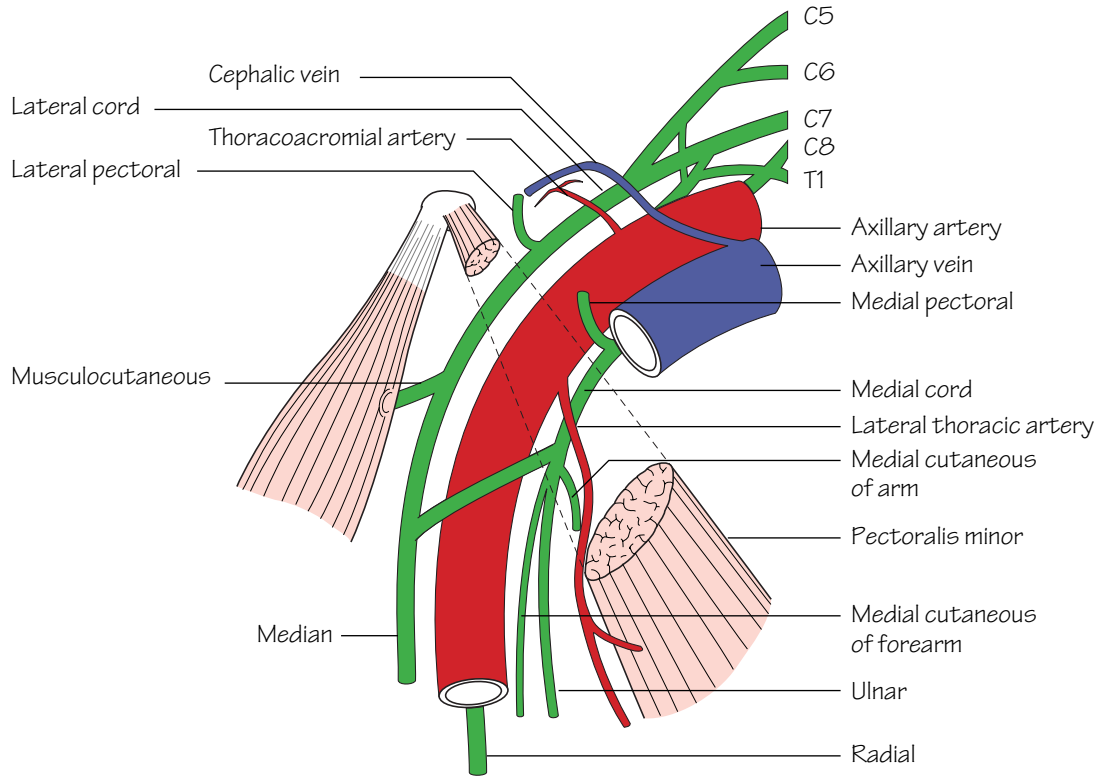
- The *deltopectoral triangle* is the region that is bounded by deltoid, pectoralis major and superiorly by the small bare length of clavicle that does not provide an origin for either of these muscles.
- The *clavipectoral fascia* is a sheet of strong connective tissue. The uppermost part of this fascia forms the floor of the deltopectoral triangle. It is attached superiorly to the clavicle around the subclavius muscle. Below it splits to enclose pectoralis minor. The fascia continues downwards as the *suspensory ligament of the axilla* and becomes continuous with the fascial floor of the armpit. The clavipectoral fascia is pierced by four structures in total. Two structures drain inwards: (1) the *cephalic vein* and (2) *lymphatics from the infraclavicular nodes*. Similarly, two structures pierce the fascia to pass outwards: (3) the *thoracoacromial artery* and (4) the *lateral pectoral nerve* (which supplies pectoralis major and minor).
- Two important *anatomical spaces* are found in the shoulder region (Fig. 32.4):
  - The *quadrangular space* is an intermuscular space through which the axillary nerve and posterior circumflex humeral vessels pass through backwards to encircle the surgical neck of the humerus. It is bounded above by subscapularis and teres minor and below by teres major. The long head of triceps and the surgical neck of the humerus are medial and lateral boundaries, respectively.
  - The *triangular space* is bounded by teres major, teres minor and the long head of triceps. The circumflex scapular artery passes from front to back through this space to gain access to the infraspinous fossa.

# 33 The axilla



**Fig.33.1**

Vertical and horizontal sections through the axilla; the planes of the sections are shown in the central diagram



**Fig.33.2**

The main contents of the axilla from the front.  
The posterior cord is hidden behind the axillary artery

The major nerves and vessels supplying and draining the upper limb pass through the axilla.

The axilla is a three-sided pyramid. Its apex is the small region between the 1st rib, the clavicle and the scapula through which the major nerves and vessels pass.

The walls of the axilla are composed as follows:

- The *anterior wall* is made up from the pectoralis major and minor muscles and the clavicular fascia.
- The *posterior wall* is made up of the subscapularis, teres major and latissimus dorsi.
- The *medial wall* consists of the upper part of serratus anterior, the upper ribs and intercostals.
- The *lateral wall* is almost non-existent but can be seen as the latissimus dorsi as it inserts into the floor of the intertubercular (bicipital) sulcus. Running downwards from above are the coracobrachialis and short head of biceps as well as the long head of biceps in the intertubercular sulcus.

### **The contents of the axilla** (Figs 33.1 and 33.2)

- **The axillary artery:** an important anastomosis exists between the subclavian artery and third part of the axillary artery—the *scapular*

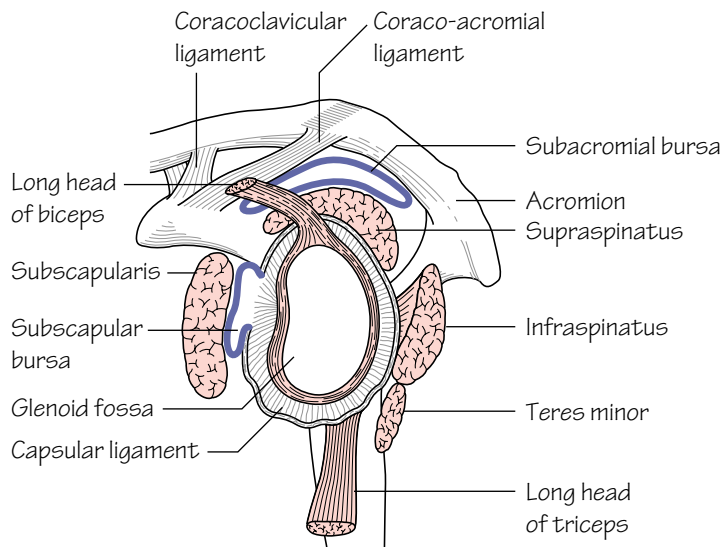
*anastomosis*. It compensates for compromised flow that may occur due to axillary artery obstruction. The principal arteries involved are the suprascapular, from the third part of the subclavian artery, and the subscapular, from the third part of the axillary artery with contributions from other arteries.

- **The axillary vein:** is formed by the confluence of the venae comitantes of the axillary artery and the basilic vein (p. 69). It becomes the subclavian vein at the lateral border of the 1st rib. The named tributaries of the axillary vein correspond to those of the axillary artery.
- **The cords and branches of the brachial plexus:** see p. 71.
- **The axillary lymph nodes:** see p. 69.
- **Fat.**

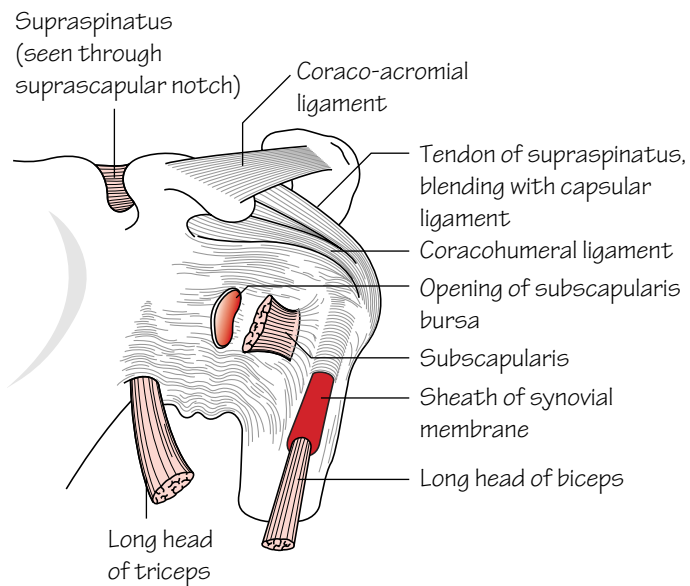
### **Axillary clearance**

*In breast cancer surgery the axillary lymph nodes are cleared routinely. During the dissection for this procedure one must clearly identify the axillary vein, and the thoracodorsal (C6,7,8) and long thoracic (C5,6,7) nerves. Injury to the thoracodorsal nerve results in paralysis of latissimus dorsi. Injury to the long thoracic nerve causes paralysis of serratus anterior resulting in weakened arm abduction. On clinical examination the latter injury results in winging of the scapula.*

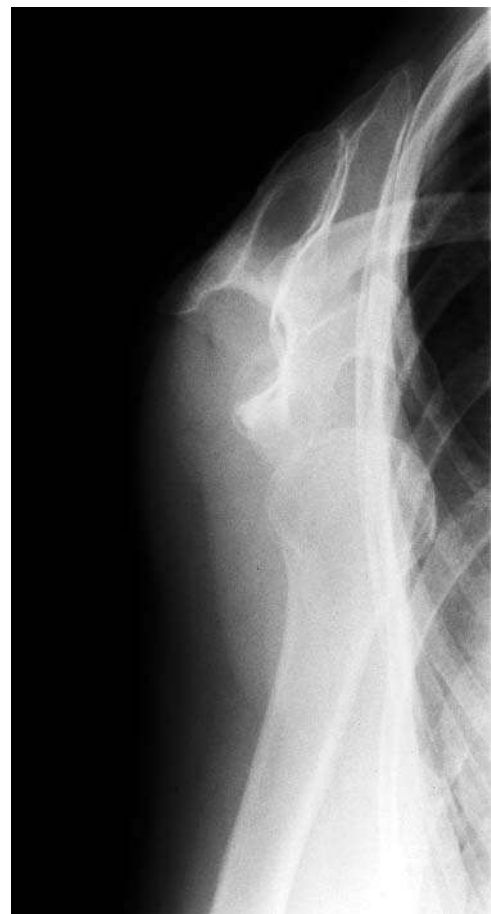## 34 The shoulder (gleno-humeral) joint



**Fig. 34.1**  
The glenoid cavity and its associated ligaments and rotator cuff muscles



**Fig. 34.2**  
Anterior aspect of the shoulder joint



**Fig. 34.3**  
X-ray of a dislocated shoulder

See Figs 34.1 and 34.2.

- **Type:** the shoulder is a *synovial 'ball and socket' joint* which permits multiaxial movement. It is formed by the articulation of the humeral head with the shallow glenoid fossa of the scapula (see p. 63). The glenoid is slightly deepened by a fibrocartilaginous rim—the *glenoid labrum*. Both articular surfaces are covered with hyaline cartilage.
- **The capsule:** of the shoulder joint is lax permitting a wide range of movement. It is attached medially to the margins of the glenoid and laterally to the anatomical neck of the humerus except inferiorly where it extends to the surgical neck. The capsule is significantly strengthened by slips from the surrounding rotator cuff muscle tendons.
- **Stability:** is afforded by the *rotator cuff* and the ligaments around the shoulder joint. The latter comprise: *three gleno-humeral ligaments* which are weak reinforcements of the capsule anteriorly; a *coraco-humeral ligament* which reinforces the capsule superiorly; and a *coracoacromial ligament* which protects the joint superiorly. The main stability of the shoulder is afforded by the *rotator cuff*. The cuff comprises: *subscapularis*, *supraspinatus*, *infraspinatus* and *teres minor* (see Muscle index, p. 162) which pass in front of, above and behind the joint, respectively. Each of these muscles can perform its own function and when all are relaxed free movement is possible, but when all are contracted they massively reinforce shoulder stability.
- **Bursae:** two large bursae are associated with the shoulder joint. The *subscapular bursa* separates the shoulder capsule from the tendon of subscapularis which passes directly anterior to it. The subscapular bursa communicates with the shoulder joint. The *subacromial bursa* separates the shoulder capsule from the coracoacromial ligament above. The subacromial bursa does not communicate with the joint. The tendon of supraspinatus lies in the floor of the bursa. Inflammation of the bursa due to adjacent inflammation of the supraspinatus tendon caused by impingement of the supraspinatus tendon on the coracoacromial ligament gives rise to severe pain and limitation of shoulder abduction (classically between 60 and 120°) known as the *painful arc syndrome*.
- **The synovial membrane:** lines the capsule and covers the articular surfaces. It surrounds the intracapsular tendon of biceps and extends slightly beyond the transverse humeral ligament as a sheath. It forms the subscapular bursa anteriorly by protruding through the anterior wall of the capsule.

- **Nerve supply:** from the axillary (C5,6) and suprascapular nerves (C5,6).

## Shoulder movements

The shoulder is a 'ball and socket' joint allowing a wide range of movement. Much of this range is attributed to the articulation of the shallow glenoid with a rounded humeral head. The drawback, however, is that of compromised stability of the joint.

The principal muscles acting on the shoulder joint are:

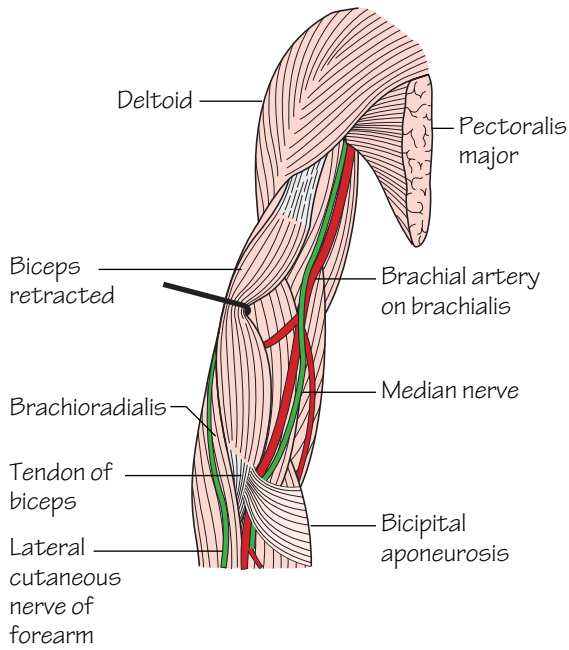
- **Flexion (0–90°):** pectoralis major, coracobrachialis and deltoid (anterior fibres).
- **Extension (0–45°):** teres major, latissimus dorsi and deltoid (posterior fibres).
- **Internal (medial) rotators (0–40°):** pectoralis major, latissimus dorsi, teres major, deltoid (anterior fibres) and subscapularis.
- **External (lateral) rotators (0–55°):** infraspinatus, teres minor and deltoid (posterior fibres).
- **Adductors (0–45°):** pectoralis major and latissimus dorsi.
- **Abductors (0–180°):** supraspinatus, deltoid, trapezius and serratus anterior.

Abduction at the shoulder joint is initiated by supraspinatus; deltoid continues it as soon as it obtains sufficient leverage. Almost simultaneously the scapula is rotated so that the glenoid faces upwards; this action is produced by the lower fibres of serratus anterior which are inserted into the inferior angle of the scapula and by the trapezius which pulls the lateral end of the spine of the scapula upwards and the medial end downwards.

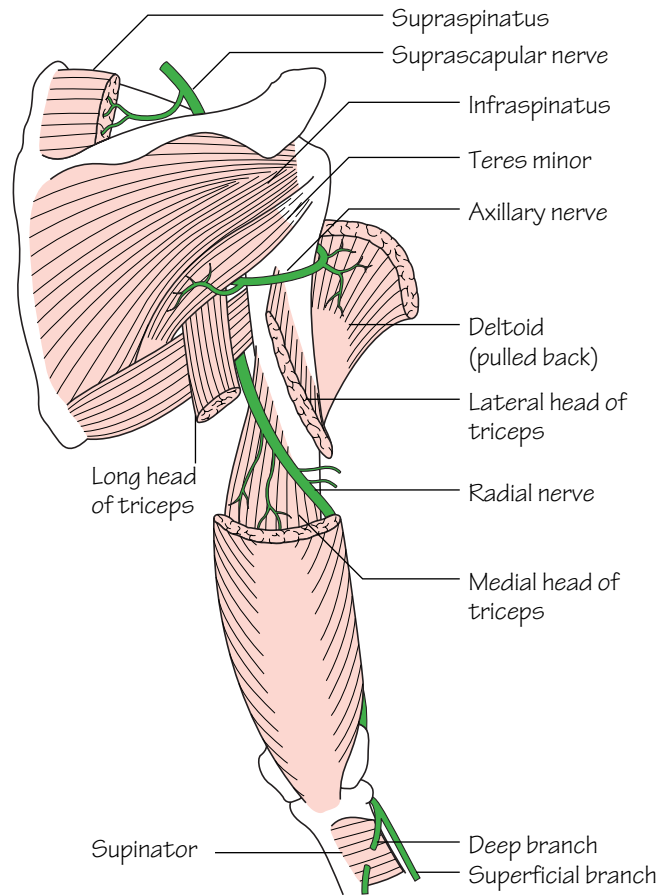
## Shoulder dislocation (Fig. 34.3)

*As has been described above, stability of the shoulder joint is mostly afforded anteriorly, superiorly and posteriorly by the rotator cuff. Inferiorly, however, the shoulder is unsupported and strong abduction, coupled with external rotation, can force the head of the humerus downwards and forwards (sometimes damaging the axillary nerve) to the point that the joint dislocates. This is termed the anterior shoulder dislocation as the head usually comes to lie anteriorly in the subcoracoid position. Sometimes the force of the injury is sufficient to tear the glenoid labrum anteriorly thereby facilitating recurrence. A surgical procedure is always required when the latter has led to repeated dislocations.*

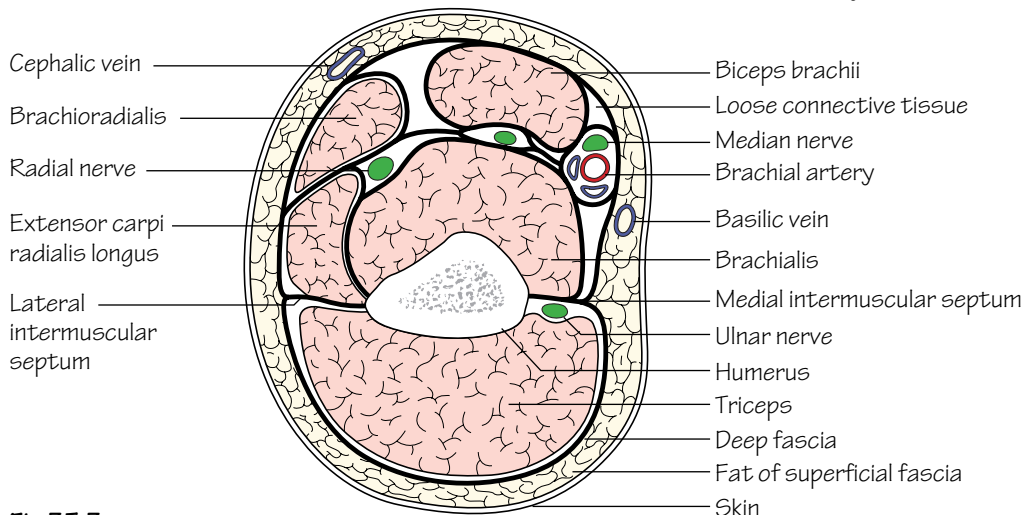
# 35 The arm



**Fig.35.1**  
The main blood vessels and nerves of the front of the arm



**Fig.35.2**  
The major nerves in the back of the arm



**Fig.35.3**  
Cross-section through the arm just above the elbow.  
The thick black lines represent the deep fascia and the intermuscular septa

When viewed in cross-section the arm consists of skin and subcutaneous tissue in which the superficial veins and sensory nerves course. Below lies a deep fascial layer. Medial and lateral intermuscular septa arise from the supracondylar lines of the humerus and extend to the deep fascia thereby dividing the arm into anterior and posterior compartments.

**The anterior (flexor) compartment contents include** (Figs 35.1 and 35.3):

- The *flexor muscles*: coracobrachialis, biceps and brachialis (see Muscle index, p. 162).
- The *brachial artery and branches*: see p. 67.
- The *median nerve*: see p. 71.
- The *ulnar nerve* (in the upper arm only—as it pierces the medial intermuscular septum to pass into the posterior compartment in the mid-arm): see p. 73.

- The *musculocutaneous nerve and branches* (remember that, after providing muscular supply to the flexor compartment, this nerve pierces the deep fascia in the mid-arm to become the lateral cutaneous nerve of the forearm): see p. 71.

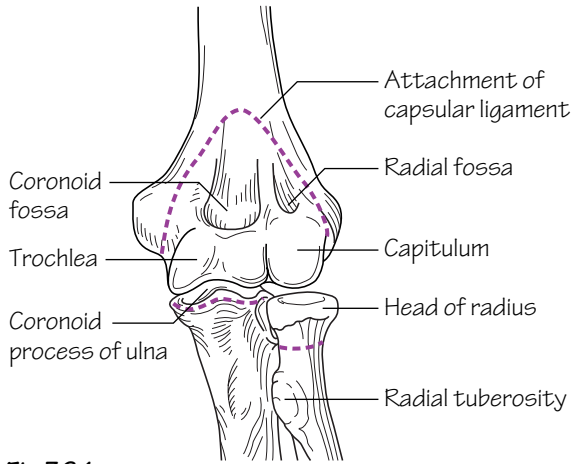
- The *basilic vein* (in the upper arm only—in the lower arm it is subcutaneous): see p. 69.

**The posterior (extensor) compartment contents include** (Figs 35.2 and 35.3):

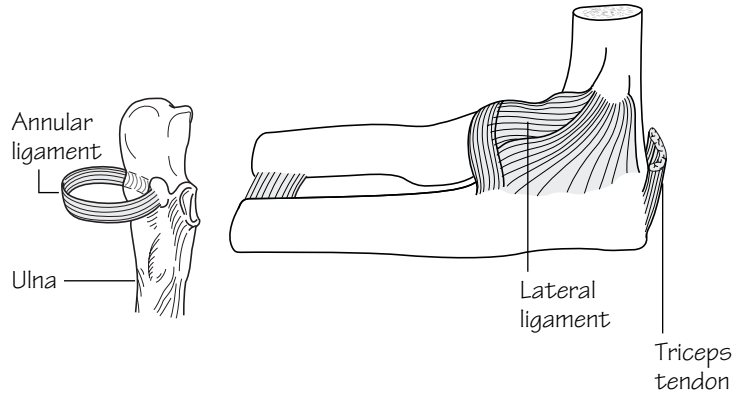
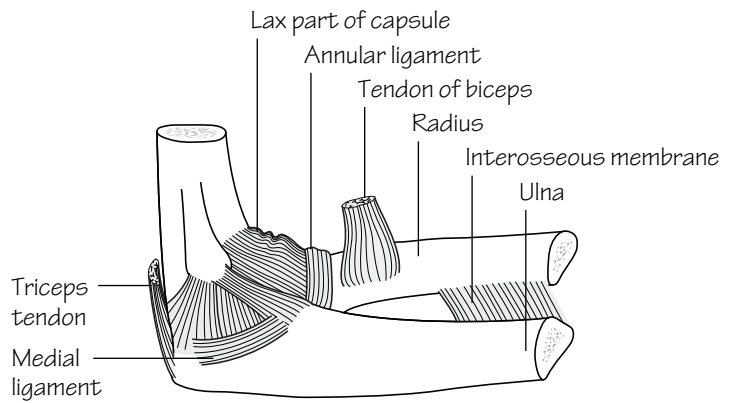
- The *extensor muscles*: triceps (see Muscle index, p. 162).
- The *radial nerve and branches*: see p. 71.
- The *profunda brachii artery*: see p. 67.
- The *ulnar nerve* (in the lower arm only): see p. 73.



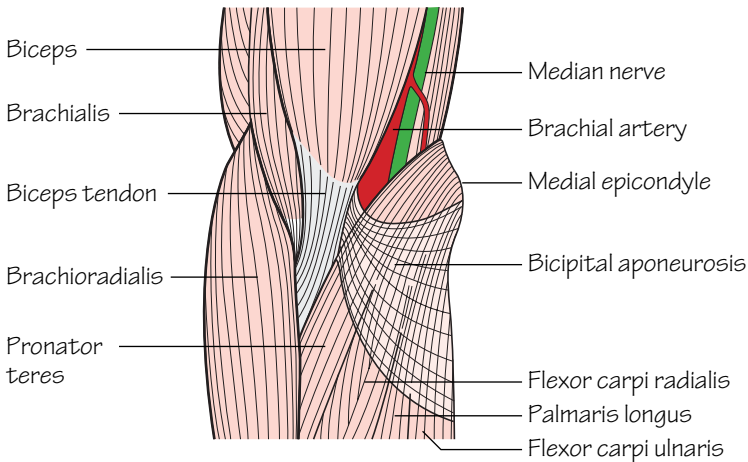
# 36 The elbow joint and cubital fossa



**Fig.36.1**  
The bones of the elbow joint; the dotted lines represent the attachments of the capsular ligament



**Fig.36.2**  
The ligaments of the elbow joint and the superior radio-ulnar joint



**Fig.36.3**  
The cubital fossa. It is crossed by the median cubital vein

## The elbow joint (Figs 36.1 and 36.2)

- **Type:** *synovial hinge joint*. At the elbow the humeral capitulum articulates with the radial head, and the trochlea of the humerus with the trochlear notch of the ulna. Fossae immediately above the trochlea and capitulum admit the coronoid process of the ulna and the radial head, respectively, during full flexion. Similarly the olecranon fossa admits the olecranon process during full elbow extension. The elbow joint communicates with the superior radio-ulnar joint.
- **Capsule:** the capsule is lax in front and behind to permit full elbow flexion and extension. The non-articular medial and lateral epicondyles are extracapsular.
- **Ligaments** (Fig. 36.2): the capsule is strengthened medially and laterally by *collateral ligaments*.
  - The *medial collateral ligament* is triangular and consists of anterior, posterior and middle bands. It extends from the medial epicondyle of the humerus and the olecranon to the coronoid process of the ulna. The ulnar nerve is adjacent to the medial collateral ligament as it passes forwards below the medial epicondyle. Owing to the close proximity of the ulnar nerve to the humerus it is at risk in many types of injury, e.g. fracture dislocations, compression and even during surgical explorations.
  - The *lateral collateral ligament* extends from the lateral epicondyle of the humerus to the *annular ligament*. The annular ligament is attached medially to the radial notch of the ulna and clasps, but does not attach to, the radial head and neck. As the ligament is not attached to the head this is free to rotate within the ligament.

## Elbow dislocation

*The classical injury is a posterior dislocation caused by a fall on the outstretched hand. It is commonest in children whilst ossification is incomplete.*

## The superior radio-ulnar joint

This is a *pivot joint*. It is formed by the articulation of the radial head and the radial notch of the ulna. The superior radio-ulnar joint communicates with the elbow joint.

## Movements at the elbow

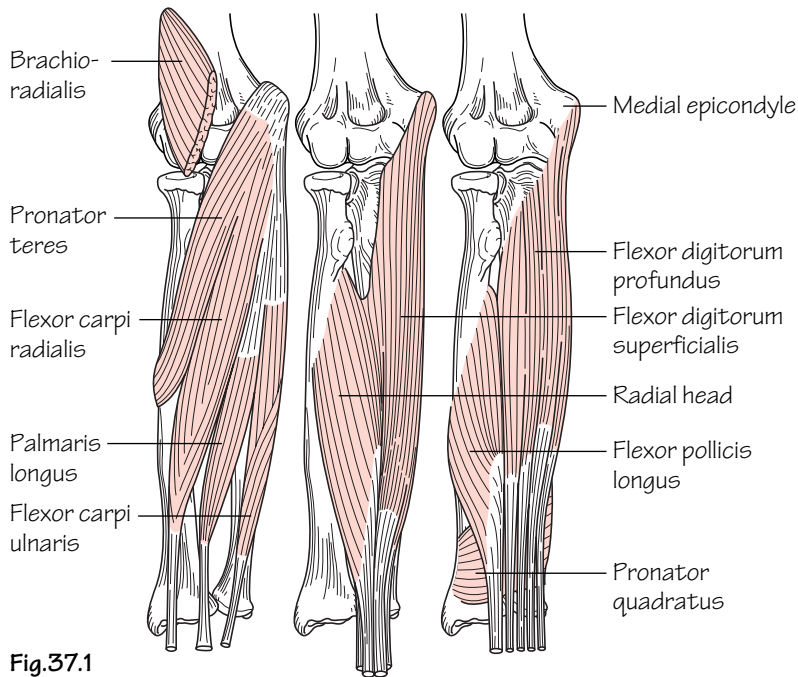
*Flexion/extension* occur at the elbow joint. *Supination/pronation* occur mostly at the *superior radio-ulnar joint* (in conjunction with movements at the inferior radio-ulnar joint).

- **Flexion (140°):** biceps, brachialis, brachioradialis and the forearm flexor muscles.
- **Extension (0°):** triceps and to a lesser extent anconeus.
- **Pronation (90°):** pronator teres and pronator quadratus.
- **Supination (90°):** biceps is the most powerful supinator. This movement is afforded by the insertion of the muscle on the posterior aspect of the radial tuberosity. Supinator, extensor pollicis longus and brevis are weaker supinators.

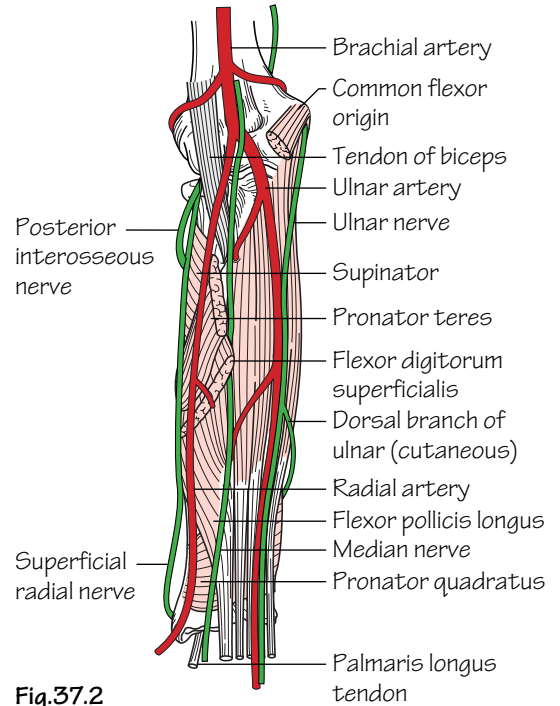
## The cubital fossa (Fig. 36.3)

- This fossa is defined by: a horizontal line joining the two epicondyles; the medial border of brachioradialis; and the lateral border of pronator teres. The *floor* of the fossa consists of brachialis muscle and the overlying *roof* of superficial fascia. The median cubital vein runs in the superficial fascia and connects the basilic to cephalic veins.
- Within the fossa the biceps tendon can be palpated. Medial to this lie the brachial artery and the median nerve.
- The radial and ulnar nerves lie outside the cubital fossa. The radial nerve passes anterior to the lateral epicondyle between brachialis and brachioradialis muscles. The ulnar nerve winds behind the medial epicondyle.

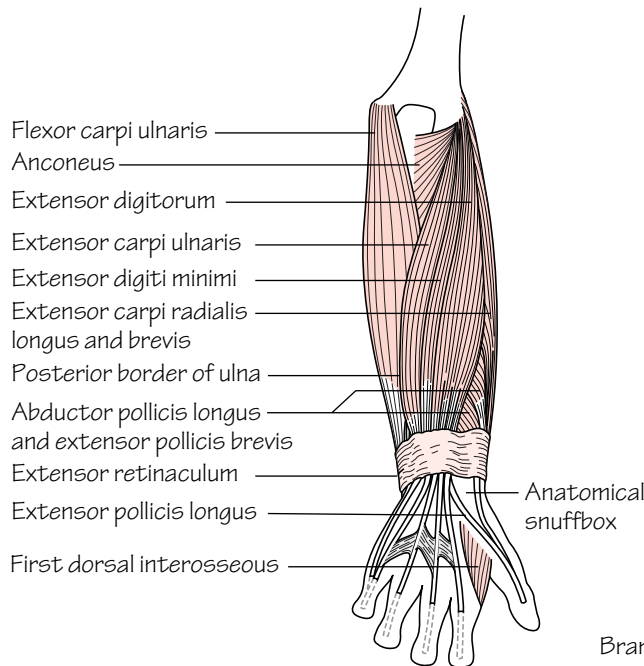
# 37 The forearm



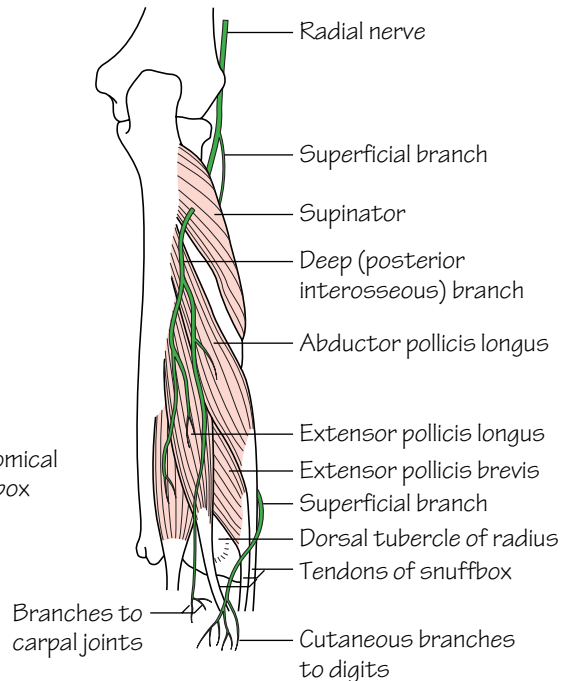
**Fig.37.1**  
 The superficial, intermediate and deep layers of the front of the forearm



**Fig.37.2**  
 The main arteries and nerves of the front of the forearm



**Fig.37.3**  
 The muscles of the superficial and deep layers of the back of the forearm and the radial nerve



The forearm is enclosed in deep fascia which is continuous with that of the arm. It is firmly attached to the periosteum of the subcutaneous border of the ulna. Together with the interosseous membrane this divides the forearm into anterior and posterior compartments each possessing its own muscles and arterial and nervous supplies. The superficial veins and cutaneous sensory nerves course in the subcutaneous tissue superficial to the deep fascia.

### The interosseous membrane

- The interosseous membrane unites the interosseous borders of the radius and ulna. The fibres of this tough membrane run obliquely downwards and medially. A downwards force (e.g. fall on the outstretched hand) is transmitted from the radius to the ulna and from here to the humerus and shoulder.
- The interosseous membrane provides attachment for neighbouring muscles.

### The contents of the anterior (flexor) compartment of the forearm

- **Muscles** (Fig. 37.1): the muscles within this compartment are considered in *superficial*, *intermediate* and *deep layers*. All of the muscles of the *superficial group* and part of *flexor digitorum superficialis* arise from the *common flexor origin* on the medial epicondyle of the humerus. With the exceptions of *flexor carpi ulnaris* and the *ulnar half*

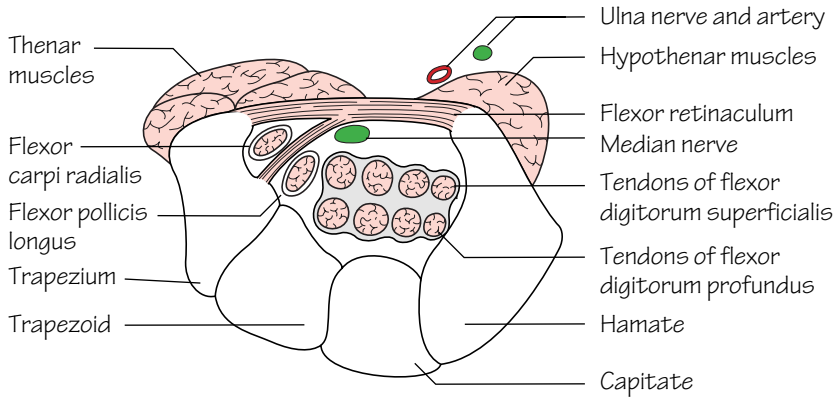
of *flexor digitorum profundus*, all of the muscles of the anterior compartment are supplied by the *median nerve* or its *anterior interosseous branch* (see Muscle index, p. 162).

- **Arteries** (Fig. 37.2): ulnar artery and its anterior interosseous branch (via the common interosseous artery); radial artery.
- **Nerve supply** (Fig. 37.2): median nerve and its anterior interosseous branch; ulnar nerve; superficial radial nerve.

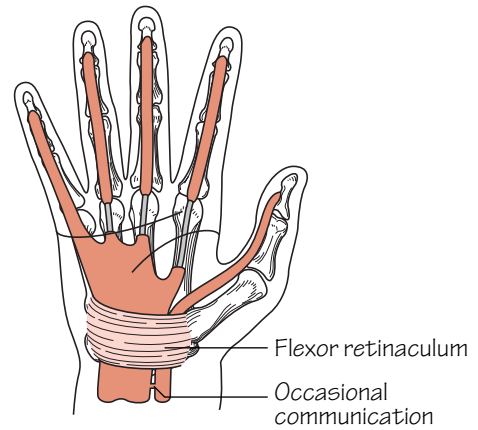
### The contents of the posterior fascial (extensor) compartment of the forearm

- **Muscles** (Fig. 37.1): *brachioradialis* and *extensor carpi radialis longus* arise separately from the *lateral supracondylar ridge* of the humerus. They are innervated by the *radial nerve*. The remaining extensor muscles are considered in *superficial* and *deep layers* which are innervated by the *posterior interosseous branch* of the radial nerve. The muscles of the superficial layer arise from the *common extensor origin* on the *lateral epicondyle of the humerus*. The muscles of the deep layer arise from the backs of the radius, ulna and interosseous membrane (see Muscle index, p. 162).
- **Arteries:** posterior interosseous artery (branch of the common interosseous artery).
- **Nerve supply:** posterior interosseous nerve (branch of the radial nerve) (Fig. 37.3).

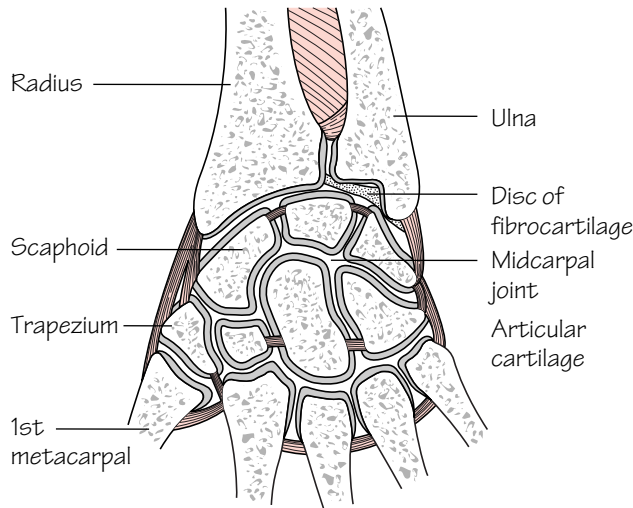
# 38 The carpal tunnel and joints of the wrist and hand



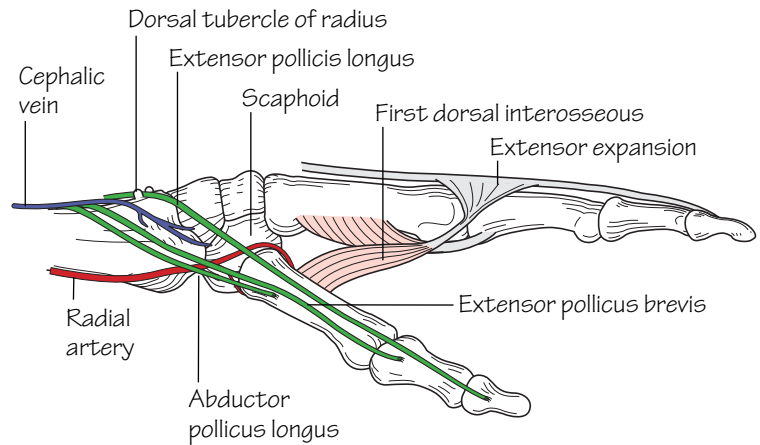
**Fig.38.1**  
A diagrammatic cross-section through the carpal tunnel



**Fig.38.2**  
The synovial sheaths of the flexor tendons



**Fig.38.3**  
The wrist and carpal joints



**Fig.38.4**  
The anatomical snuffbox

### The flexor retinaculum and carpal tunnel (Fig. 38.1)

The carpal tunnel is formed by the carpal bones and the overlying flexor retinaculum. It is through this tunnel that most, but not all, of the forearm tendons and the median nerve pass. The flexor retinaculum is attached to four bony points—the pisiform, the hook of the hamate, the scaphoid and the trapezium.

The carpal tunnel is narrow and no arteries or veins are transmitted through it for risk of potential compression. The median nerve is however at risk of compression when the tunnel is narrowed for any reason. This is the *carpal tunnel syndrome* and results in signs of median nerve motor and sensory impairment. Note that the ulnar nerve and artery pass over the retinaculum and are thus outside the carpal tunnel.

### The synovial sheaths of the flexor tendons (Fig. 38.2)

The diagram illustrates the arrangement of the synovial sheaths that surround the flexor tendons. It can be seen that *flexor pollicis longus* has its own sheath and *flexor digitorum superficialis* and *profundus* share one which ends in the palm (except that for the little finger).

### The wrist (radiocarpal) joint (Fig. 38.3)

- **Type:** the wrist is a *condyloid synovial joint*. The distal radius and a triangular disc of fibrocartilage covering the distal ulna form the proximal articulating surface. This disc is attached to the edge of the ulnar notch of the radius and to the base of the styloid process of the ulna and separates the wrist joint from the inferior radio-ulnar joint. The distal articulating surface is formed by the scaphoid and lunate bones with the triquetrum participating in adduction.
- **Capsule:** a defined capsule surrounds the joint. It is thickened on either side by the *radial* and *ulnar collateral ligaments*.
- **Nerve supply:** from the anterior interosseous (median) and posterior interosseous (radial) nerves.

### Wrist movements

Flexion/extension movements occurring at the wrist are accompanied by movements at the midcarpal joint. Of a total of 80° of wrist flexion the majority occurs at the midcarpal joint whereas in extension a corresponding increased amount occurs at the wrist joint.

The muscles acting on the wrist joint include:

- **Flexion:** all long muscles crossing the joint anteriorly.
- **Extension:** all long muscles crossing the joint posteriorly.
- **Abduction:** flexor carpi radialis and extensors carpi radialis longus and brevis.
- **Adduction:** flexor carpi ulnaris and extensor carpi ulnaris.

### The joints of the hand (Fig. 38.3)

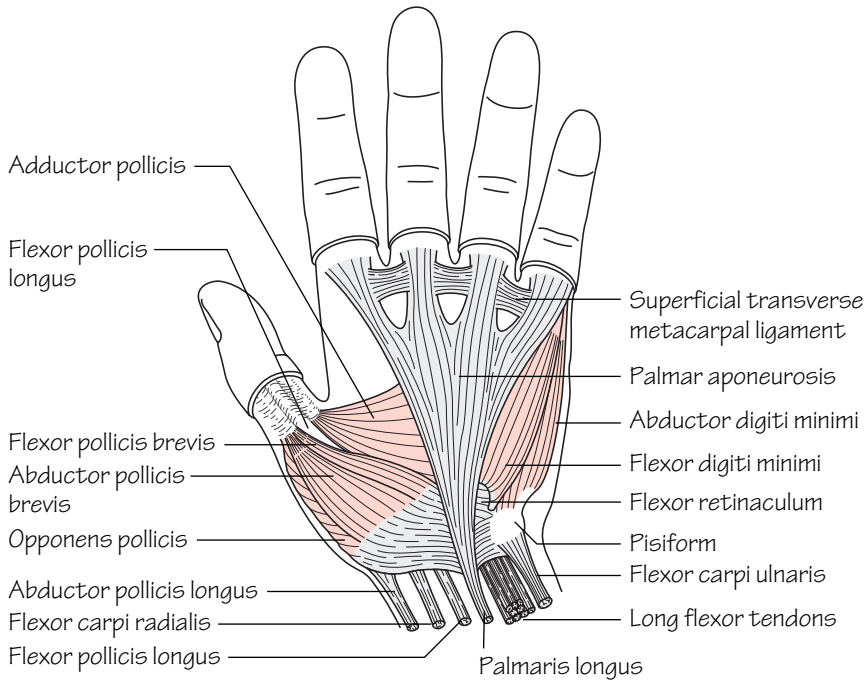
- **Intercarpal joints:** the *midcarpal joint*, located between the proximal and distal rows of carpal bones, is the most important of these as it participates in wrist movement (see above).
- **Carpometacarpal joints:** the most important of these is the *1st carpometacarpal (thumb) joint*. This is a saddle-shaped joint between the trapezium and the 1st metacarpal. It is a condyloid synovial joint which is separate from others in the hand, permitting a range of movement similar to that of a ball and socket joint. The most important movement of the thumb is opposition in which the thumb is opposed to the fingers as in holding a pen.
- **Metacarpophalangeal joints:** are synovial condyloid joints.
- **Interphalangeal joints:** are synovial hinge joints.

### The anatomical snuffbox

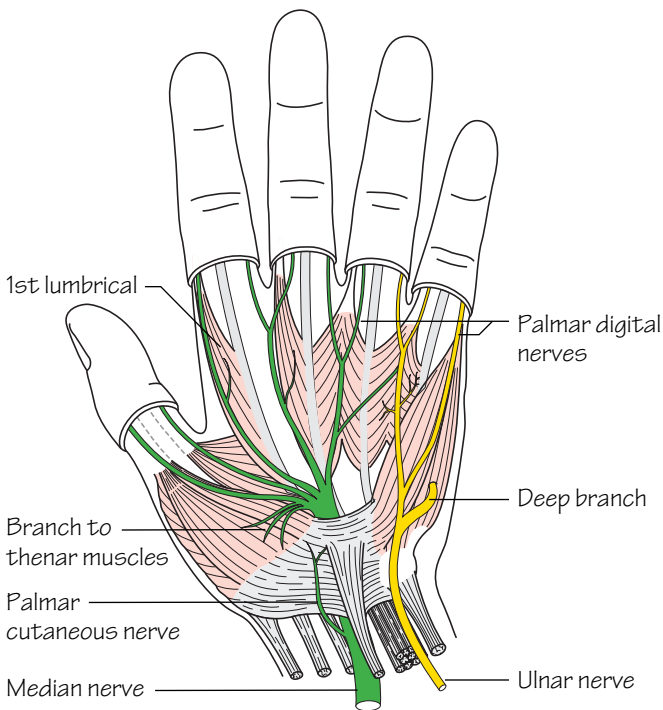
Figure 38.4 illustrates the boundaries and contents of the anatomical snuffbox.



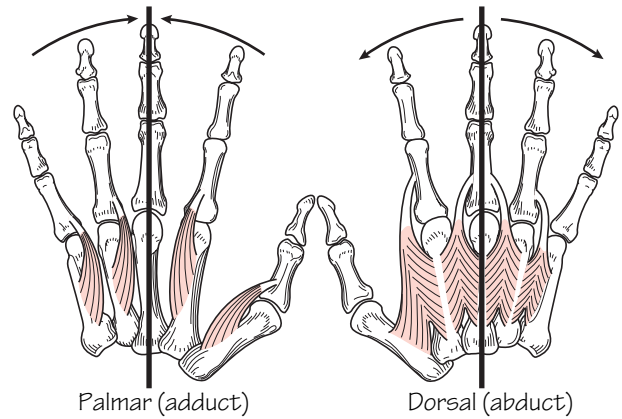
# 39 The hand



**Fig.39.1**  
The superficial muscles of the hand



**Fig.39.3**  
The ulnar (yellow) and median (green) nerves in the hand.  
Note particularly the recurrent branch of the median nerve which supplies the thenar muscles



**Fig.39.2**  
The palmar (L.) and dorsal (R.) interossei and their actions in abduction and adduction



### The palm of the hand (Fig. 39.1)

- **Skin:** the skin of the palm is bound to underlying fascia by fibrous bands.
- **Deep fascia:** the *palmar aponeurosis* is a triangular layer which is attached to the distal border of the flexor retinaculum. Distally the aponeurosis splits into four slips at the bases of the fingers which blend with the fibrous flexor sheaths (see below). The aponeurosis provides firm attachment of the overlying skin with protection of the underlying structures.
- **Fibrous flexor sheaths:** these are fibrous tunnels in which the flexor tendons and their synovial sheaths lie. They arise from the metacarpal heads and pass to the bases of the distal phalanges on the anterior aspect of the digits. They insert into the sides of the phalanges. These sheaths are lax over the joints and thick over the phalanges and hence do not restrict flexion.
- **Synovial flexor sheaths:** these are sheaths that limit friction between the flexor tendons and the carpal tunnel and fibrous flexor sheaths.
- **Long flexor tendons:** the tendons of flexor digitorum superficialis (FDS) divide into two halves at the level of the proximal phalanx and pass around flexor digitorum profundus (FDP) where they reunite. At this point they then split again to insert into the sides of the middle phalanx. FDP continues along its path to insert into the distal phalanx. Flexor pollicis longus (FPL) passes through the carpal tunnel in its own synovial sheath and inserts into the distal phalanx. The tendons of flexor carpi radialis, palmaris longus and flexor carpi ulnaris pass through the forearm and also insert in the proximal hand (see Muscle index, p. 162).

### Muscles of the hand (Fig. 39.1)

- The *thenar muscles*: these are the short muscles of the thumb. They include: abductor pollicis brevis, flexor pollicis brevis, opponens pollicis and adductor pollicis.
- The *hypothenar muscles*: these are the short muscles of the little finger. They include abductor digiti minimi, flexor digiti minimi and opponens digiti minimi.
- *Lumbricals*: these four muscles arise from the tendons of flexor digitorum profundus. They insert into the radial side of each of the proximal phalanges and into the dorsal extensor expansions. The lumbricals serve to flex the metacarpophalangeal joints without flexing the interphalangeal joints.
- The *interosseous muscles* (Fig. 39.2): these comprise eight muscles which arise from the shafts of the metacarpals. They are responsible for flexion at the metacarpophalangeal joints and extension of the interphalangeal joints. They also perform abduction and adduction movements

of the fingers. These movements occur around the middle finger hence adduction is the bringing together of all fingers towards the middle finger, abduction is moving them away from the middle finger. The dorsal interossei each arise from two metacarpals and insert into the proximal phalanges so as to provide adduction (P.AD). The dorsal interossei arise from only one metacarpal and are inserted into the proximal phalanges so as to provide abduction (D.AB). Note that the middle finger cannot be adducted (and hence has no palmar interosseous) but can be abducted in either direction so it has two dorsal interosseous insertions.

### The dorsum of the hand

- **Skin:** unlike the palm of the hand the skin is thin and freely mobile over the underlying tendons.
- **Long extensor tendons:** the four tendons of extensor digitorum (ED) pass under the extensor retinaculum. On the dorsum of the hand the ED tendon to the index finger is accompanied by the tendon of extensor indicis. The ED tendon to the little finger is accompanied by the double tendon of extensor digiti minimi. The ED tendons of the little, ring and middle fingers are connected to each other by fibrous slips. On the posterior surface of each finger the extensor tendon spreads to form a dorsal digital expansion. This expansion is triangular shaped and at its apex splits into three parts: a middle slip which is attached to the base of the middle phalanx; and two lateral slips which converge to attach to the base of the distal phalanx. The base of the expansion receives the appropriate interossei and lumbricals. The tendons of abductor pollicis longus, extensor pollicis brevis and longus form the boundaries of the anatomical snuffbox and proceed to insert into the thumb.

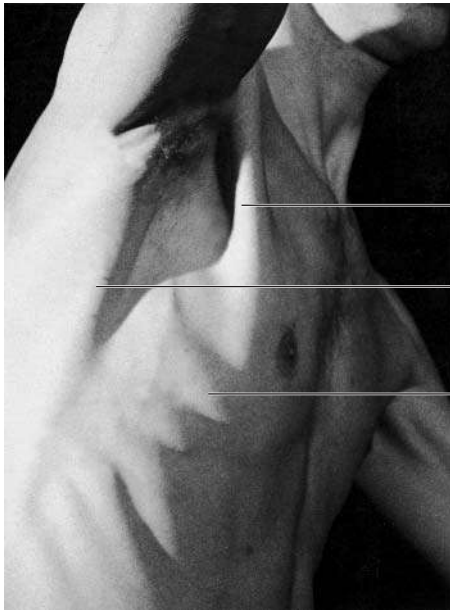### Neurovascular structures of the hand (Fig. 39.3)

See chapters on upper limb: arteries, nerves, veins and lymphatics.

### Movements of the fingers and thumb

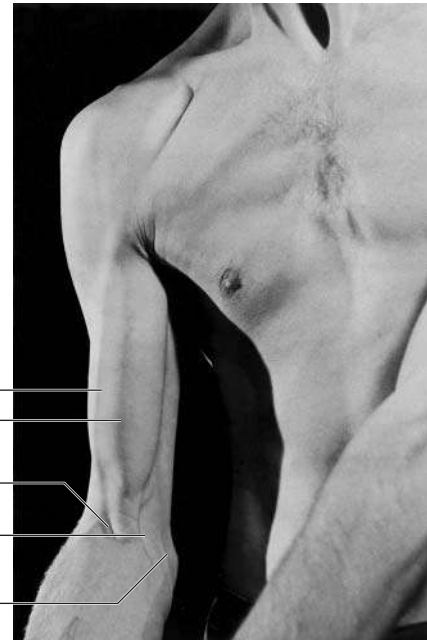The hand is required to perform a versatile range of movement extending from a firm grasp, such as that needed to carry heavy bags, to precision gripping such as that required to hold a pencil. For precision grips the thumb is used to oppose the index finger in which the interphalangeal joint is extended and the metacarpophalangeal joint is flexed. The thumb opposition is carried out mainly by opponens pollicis whilst the lumbricals and interossei are responsible for maintaining flexion at the metacarpophalangeal joints and extension at the interphalangeal joints. Since the thumb is at right angles to the plane of the fingers, abduction of the thumb is a movement away from the plane of the palm. This is used in testing the integrity of the median nerve (abductor pollicis).

## 40 Surface anatomy of the upper limb



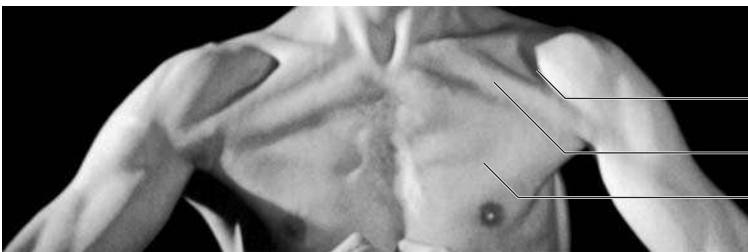Pectoralis major  
Latissimus dorsi  
and teres major  
Serratus  
anterior

**Fig.40.1**  
The axilla with the arm fully abducted



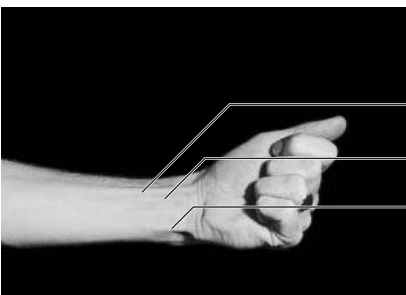
Cephalic vein  
Biceps brachii  
Biceps tendon  
Aponeurosis  
Basilic vein

**Fig.40.2**  
The biceps tendon and aponeurosis which are a guide to the positions of the brachial artery and the median nerve at the elbow



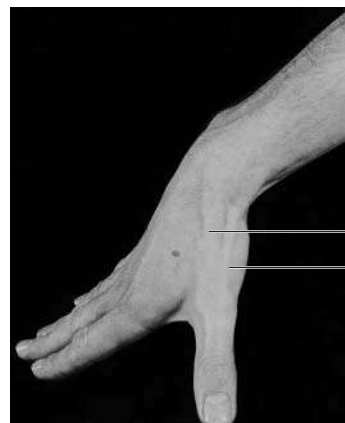
Deltopectoral triangle  
Clavicular head  
Sternocostal head } of pectoralis major

**Fig.40.3**  
Strong contraction of the pectoral muscles produced by adduction



Flexor carpi radialis  
Palmaris longus  
Flexor carpi ulnaris

**Fig.40.4**  
The visible tendons at the front of the wrist.  
Palmaris longus is a guide to the position of the median nerve



Extensor pollicis longus  
Extensor pollicis brevis  
Abductor pollicis longus

**Fig.40.5**  
The anatomical snuffbox.  
Details are shown in Fig.38.4

## Bones and joints

- **Vertebrae:** if a finger is passed down the posterior neck in the midline the first bony structure palpated is the spinous process of the 7th cervical vertebra (vertebra prominens)—the first six spinous processes are covered by the *ligamentum nuchae*.
- **Scapula:** the *acromion process* can be palpated as a lateral extension of the *spine of the scapula*. The *spine, superior angle, inferior angle* and *medial border* are palpable posteriorly. The *coracoid process* can be palpated below the clavicle anteriorly within the lateral part of the deltopectoral triangle (Fig 40.1).
- **Clavicle:** is subcutaneous and therefore palpable throughout its length.
- **Humerus:** the *head* is palpable in the axilla with the shoulder abducted. The *lesser tuberosity* can be felt lateral to the *coracoid process*. When the arm is externally and internally rotated the lesser tuberosity can be felt moving next to the fixed coracoid process.
- **Elbow:** the *medial and lateral epicondyles of the humerus* and *olecranon process of the ulna* can be palpated in line when the elbow is extended. With the elbow flexed they form a triangle. This assumes importance clinically in differentiating supracondylar fractures of the humerus, where the ‘triangle’ is preserved, from elbow dislocations where the olecranon comes into line with the epicondyles.
- **Radius:** the *radial head* can be felt in a hollow distal to the lateral epicondyle on the posterolateral aspect of the extended elbow. The head can be felt rotating when the forearm is pronated and supinated.
- **Ulna:** the posterior border is subcutaneous and therefore palpable.
- **Wrist:** the *styloid processes of the radius and ulna* are palpable. The *dorsal tubercle (of Lister)* can be felt on the posterior aspect of the distal radius.
- **Hand:** the *pisiform* can be palpated at the base of the hypothenar eminence. The *hook of the hamate* can be felt on deep palpation in the hypothenar eminence just distal to the pisiform. The *scaphoid bone* can be felt within the anatomical snuffbox (Fig, 40.5).

## The soft tissues

- **Axilla:** the anterior axillary fold (formed by the lateral border of pectoralis major) and the posterior axillary fold (formed by latissimus dorsi as it passes around the lower border of teres major) are easily palpable (Fig. 40.1).
- **Pectoralis major:** contracts strongly during arm adduction (Fig. 40.3); this is useful in the examination of breast lumps.
- **Breast:** the base of the breast overlaps the 2nd to 6th ribs and extends from the sternum to the mid-axillary line. The nipple (in males) usually overlies the 4th intercostal space.

- **Anterior wrist:** the *proximal transverse crease* corresponds to the level of the wrist joint. The *distal transverse crease* lies at the level of the proximal border of the flexor retinaculum.
- **Anatomical snuffbox:** the boundaries are formed medially by extensor pollicis longus and laterally by the tendons of abductor pollicis longus and extensor pollicis brevis.

## Vessels

- The *subclavian artery* can be felt pulsating as it crosses the 1st rib.
- The *brachial artery* bifurcates into radial and ulnar branches at the level of the neck of the radius. The brachial pulse is felt by pressing laterally at a point medial to the bicipital tendon (Fig. 40.2). This is the pulse used when taking blood pressure measurements.
- At the wrist the *radial artery* courses on the radial side of flexor carpi radialis (Fig. 40.4) and the *ulnar artery* and nerve course on the radial side of flexor carpi ulnaris. The pulses of both are easily felt at these points. The radial artery can also be felt in the anatomical snuffbox.
- The *superficial palmar arch* is impalpable and reaches as far as the proximal palmar crease. The *deep palmar arch* reaches a point approximately one fingerbreadth proximal to the superficial arch.
- The *dorsal venous network* (on the dorsum of the hand) drains laterally into the cephalic vein and medially into the basilic. These veins can be identified in most lean subjects. The median cubital vein is usually visible in the cubital fossa.

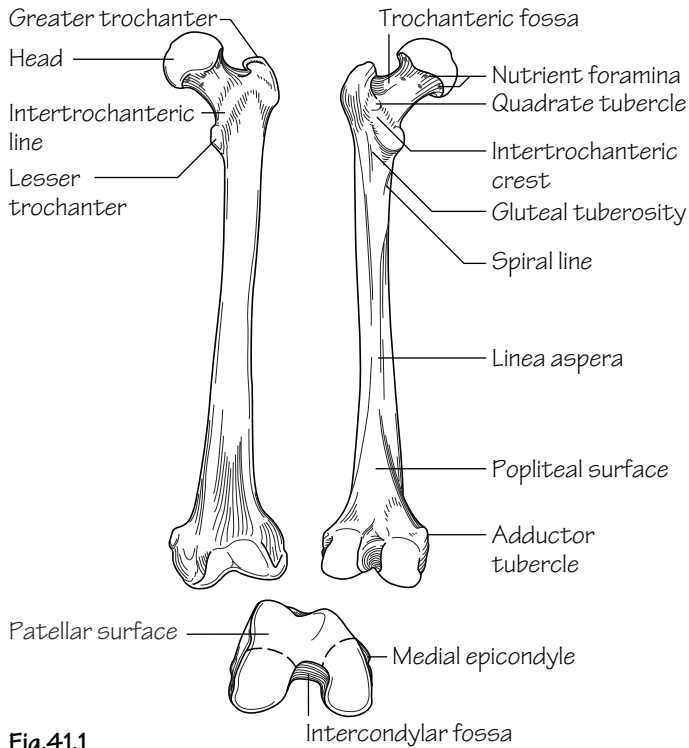
## Nerves

The *ulnar nerve* can usually be rolled as it courses behind the medial epicondyle—an important point when considering surgical approaches to the elbow and fractures of the medial epicondyle.

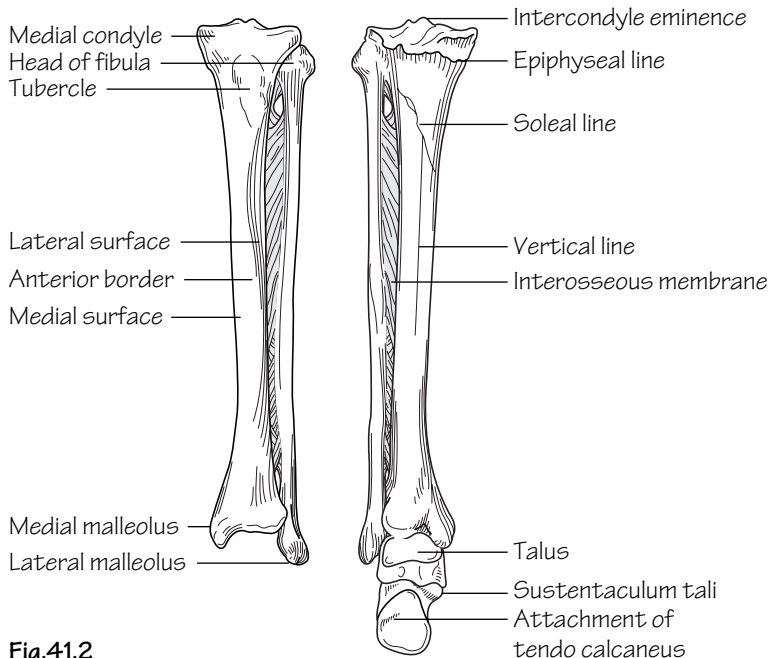
The surface markings of *impalpable nerves* must be known for safe surgical incisions. These correspond to:

- **Axillary nerve:** winds around behind the surgical neck of the humerus.
- **Radial nerve:** crosses from medial to lateral behind the humeral shaft at its midpoint.
- **Posterior interosseous branch (of radial nerve):** winds around the radius three fingerbreadths distal to the head of the radius.
- **Median nerve** (at the wrist): lies in the midline, just lateral to the tendon of palmaris longus.
- **Ulnar nerve** (at the wrist): lies immediately medial to the ulnar artery.

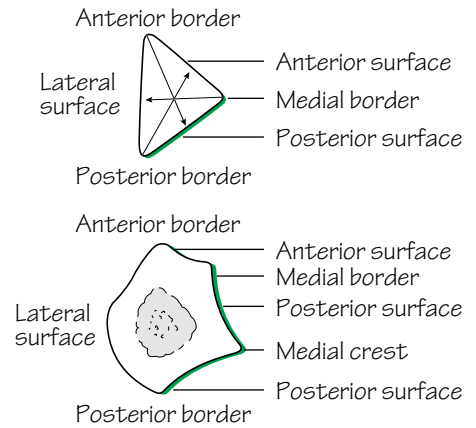
# 41 The osteology of the lower limb



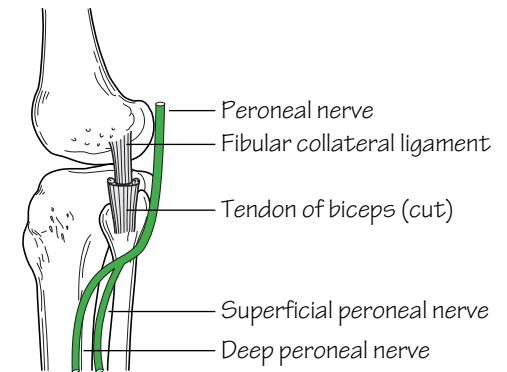
**Fig.41.1**  
The femur, anterior and posterior views and the lower end from below



**Fig.41.2**  
The front and back of the tibia, fibula and ankle region. The interosseous membrane and its openings are also shown



**Fig.41.3**  
Diagram to explain the borders and surfaces of the fibula (see text)



**Fig.41.4**  
The knee viewed from the lateral side showing the common peroneal nerve

## The femur (Fig. 41.1)

The femur is the longest bone in the body. It has the following characteristic features:

- The *femoral head* articulates with the *acetabulum* of the hip bone at the hip joint. It extends from the femoral neck and is rounded, smooth and covered with articular cartilage. This configuration permits a wide range of movement. The head faces medially, upwards and forwards into the acetabulum. The *fovea* is the central depression on the head to which the *ligamentum teres* is attached.
- The *femoral neck* forms an angle of 125° with the femoral shaft. Pathological lessening or widening of the angle is termed *coxa vara* and *coxa valga* deformity, respectively.
- The *femoral shaft* constitutes the length of the bone. At its upper end it carries the *greater trochanter* and, posteromedially, the *lesser trochanter*. Anteriorly the rough *trochanteric line*, and posteriorly the smooth *trochanteric crest*, demarcate the junction between the shaft and neck. The *linea aspera* is the crest seen running longitudinally along the posterior surface of the femur splitting in the lower portion into the *supracondylar lines*. The medial supracondylar line terminates at the *adductor tubercle*.
- The lower end of the femur comprises the medial and lateral *femoral condyles*. These bear the articular surfaces for articulation with the tibia at the knee joint. The lateral condyle is more prominent than the medial. This prevents lateral displacement of the patella. The condyles are separated posteriorly by a deep *intercondylar notch*. Anteriorly the lower femoral aspect is smooth for articulation with the posterior surface of the patella.

## The tibia (Fig. 41.2)

The tibia serves to transfer weight from the femur to the talus. It has the following characteristics:

- The flattened upper end of the tibia—the *tibial plateau*—comprises medial and lateral *tibial condyles* for articulation with the respective femoral condyles. In contrast to the femoral condyles, the medial tibial condyle is the larger of the two.
- The *intercondylar area* is the space between the tibial condyles on which can be seen two projections—the *medial* and *lateral intercondylar tubercles*. Together these constitute the *intercondylar eminence*. The horns of the lateral meniscus are attached close to either side of the eminence.
- On the anterior upper shaft the *tibial tuberosity* is easily identifiable. This is the site of insertion of the *ligamentum patellae*.
- The shaft is triangular in cross-section. It has anterior, medial and lateral borders and posterior, lateral and medial surfaces.
- The anterior border and medial surface of the shaft are subcutaneous throughout its length. For this reason the tibial shaft is the commonest site for open fractures.

- On the posterior surface of the shaft an oblique line—the *soleal line*—demarcates the tibial origin of soleus. Popliteus inserts into the triangular area above the soleal line.
- The fibula articulates with the tibia superiorly at an articular facet on the postero-inferior aspect of the lateral condyle—the *superior tibiofibular joint (synovial)*.
- The *fibular notch* is situated laterally on the lower end of the tibia for articulation with the fibula at the *inferior tibiofibular joint (fibrous)*.
- The tibia projects inferiorly as the *medial malleolus*. It constitutes the medial part of the mortice that stabilizes the talus. The medial malleolus is grooved posteriorly for the passage of the tendon of tibialis posterior.

## The fibula (Fig. 41.2)

The fibula does *not* form part of the knee joint and does *not* participate in weight transmission. The main functions of the fibula are to provide origin for muscles and to participate in the ankle joint. It has the following characteristic features:

- The *styloid process* is a prominence on the fibular *head* onto which the tendon of biceps is inserted (around the *lateral collateral ligament*) (Fig. 41.4).
- The fibular *neck* separates the head from the fibular shaft. The common peroneal nerve winds around the neck prior to dividing into superficial and deep branches. This nerve is subject to injury in fibular neck fractures with resulting footdrop (Fig. 41.4).
- The fibula is triangular in cross-section. It has anterior, medial (interosseous) and posterior borders with anterior, lateral and posterior surfaces. The *medial crest* is on the posterior surface (Fig. 41.3).
- The lower end of the fibula constitutes the *lateral malleolus*. This is the lateral part of the mortice that stabilizes the talus. It bears a smooth medial surface for articulation with the talus. The posterior aspect of the malleolus is grooved for the passage of the tendons of peroneus longus and brevis. The lateral malleolus projects further downwards than the medial malleolus.

## The patella

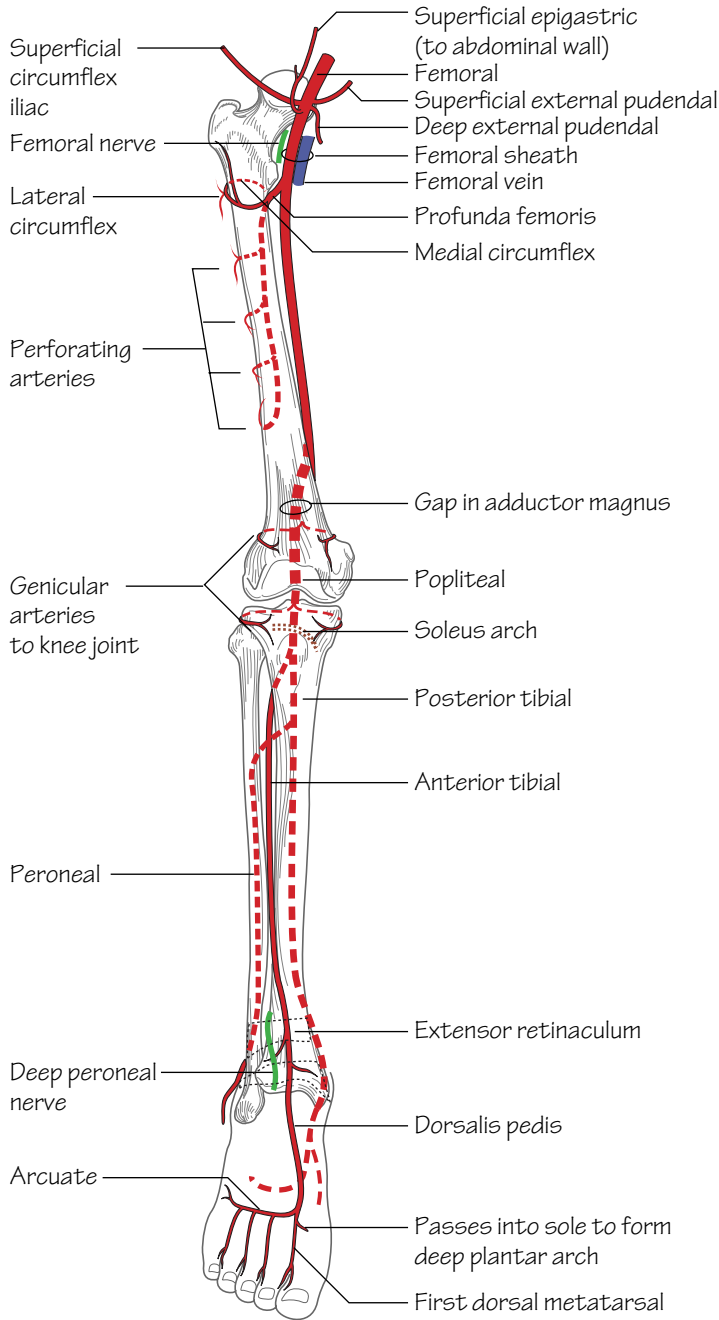
- The ligamentum patellae, which is attached to the apex of the patella and the tibial tuberosity, is the true insertion of the quadriceps and the patella is thus a sesamoid bone (the largest in the body). This arrangement constitutes the *extensor mechanism*. *Injuries can occur to any part of the mechanism due to forcible quadriceps contraction, e.g. ruptured quadriceps expansion, rupture of the ligamentum patellae or avulsion of the tibial tuberosity.*
- The posterior surface of the patella is smooth and covered with articular cartilage. It is divided into a large lateral and a smaller medial facet for articulation with the femoral condyles.

## Bones of the foot

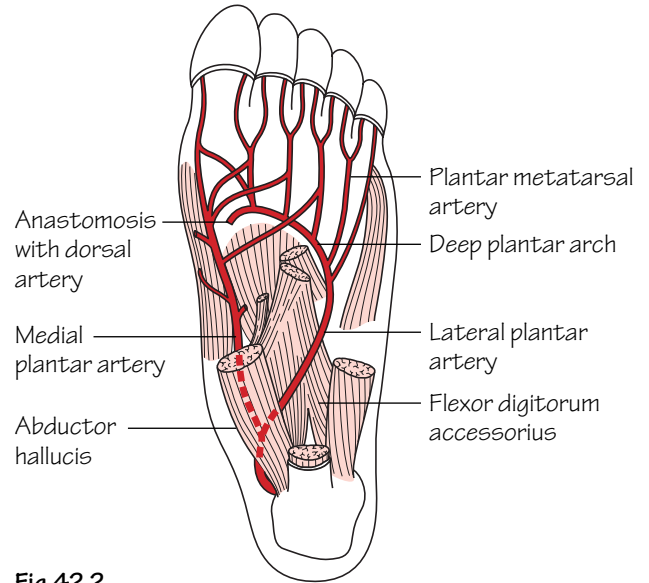
See p. 114.



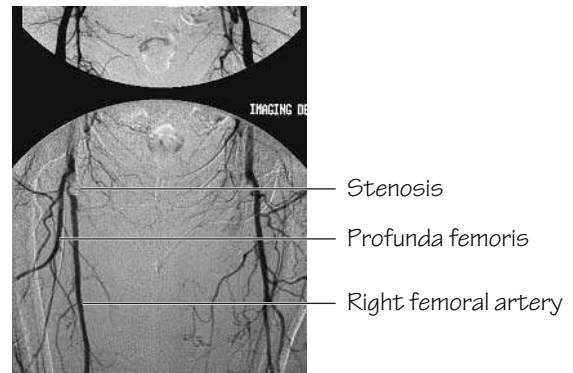
## 42 The arteries of the lower limb



**Fig.42.1**  
The course and major branches of the femoral artery



**Fig.42.2**  
The medial and lateral plantar arteries



**Fig.42.3**  
An angiogram of the lower limb showing stenosis of the femoral artery on the right side. (The profunda is often known as the deep femoral and the continuation of the femoral artery as the superficial femoral)

## The femoral artery

• **Course:** the *femoral artery* commences as a continuation of the *external iliac artery* behind the inguinal ligament at the mid-inguinal point. In the groin the femoral vein lies immediately medial to the artery and both are enclosed in the femoral sheath. In contrast, the femoral nerve lies immediately lateral to the femoral sheath. The femoral artery descends the thigh to pass under sartorius and then through the *adductor (Hunter's) canal* to become the *popliteal artery*.

• **Branches:**

- **Branches in the upper part of the femoral triangle**—four branches are given off which supply the superficial tissues of the lower abdominal wall and perineum (see Fig. 44.1).
- **Profunda femoris**—arises from the lateral side of the femoral artery 4 cm below the inguinal ligament. Near its origin it gives rise to *medial* and *lateral circumflex femoral branches*. These contribute to the *trochanteric* and *cruciate anastomoses* (see below). The profunda descends deep to adductor longus in the medial compartment of the thigh and gives rise to four *perforating* branches. These circle the femur posteriorly perforating, and supplying, all muscles in their path. The profunda and perforating branches ultimately anastomose with the genicular branches of the popliteal artery.

## The trochanteric anastomosis

This arterial anastomosis is formed by branches from the *medial* and *lateral circumflex femoral*, the *superior gluteal* and, usually, the *inferior gluteal arteries*. It lies close to the trochanteric fossa and provides branches that ascend the femoral neck beneath the retinacular fibres of the capsule to supply the femoral head.

## The cruciate anastomosis

This anastomosis constitutes a collateral supply. It is formed by: the *transverse* branches of the *medial* and *lateral circumflex femoral arteries*, the *descending* branch of the *inferior gluteal artery* and the *ascending* branch of the *1st perforating* branch of the profunda.

## The popliteal artery

• **Course:** the *femoral artery* continues as the *popliteal artery* as it passes through the hiatus in adductor magnus to enter the popliteal space. From above, it descends on the posterior surface of the femur, the capsule of the knee joint and then on the fascia overlying popliteus to pass under the fibrous arch of soleus where it bifurcates into *anterior* and *posterior tibial arteries*. In the fossa it is the deepest structure, rendering it difficult to feel its pulsations. The *popliteal vein* crosses the artery superficially and the *tibial nerve* crosses from lateral to medial over the vein. The *peroneal* branch of the posterior tibial may arise early to form the *popliteal trifurcation*.

• **Branches:** *muscular*, *sural* and five *genicular* arteries are given off. The last form a rich anastomosis around the knee.

## The anterior tibial artery

• **Course:** the *anterior tibial artery* passes anteriorly from its origin, accompanied by its *venae comitantes*, over the upper border of the interosseous membrane and then descends over the anterior surface of the membrane giving off *muscular* branches to the extensor compartment of the leg. The artery crosses the front of the ankle joint midway be-

tween the malleoli where it becomes the *dorsalis pedis artery*. Tibialis anterior and extensor digitorum longus flank the artery throughout its course on its medial and lateral sides, respectively. Extensor hallucis longus commences on the lateral side but crosses the artery to lie medial by the end of its course. The dorsalis pedis artery passes on the dorsum of the foot to the level of the base of the metatarsals and then between the two heads of the first dorsal interosseous muscle to gain access to the sole and complete the deep plantar arch. Prior to passing to the sole it gives off the *1st dorsal metatarsal* branch and via an *arcuate* branch the three remaining *dorsal metatarsal* branches (Fig. 42.1).

• **Branches of the anterior tibial artery include:** *muscular* and *malleolar* branches.

## The posterior tibial artery

• **Course:** the *posterior tibial artery* arises as a terminal branch of the popliteal artery. It is accompanied by its *venae comitantes* and supplies the flexor compartment of the leg. Approximately midway down the calf the tibial nerve crosses behind the artery from medial to lateral. The artery ultimately passes behind the medial malleolus to divide into *medial* and *lateral plantar arteries* under the flexor retinaculum. The latter branches gain access to the sole deep to abductor hallucis. Posterior to the medial malleolus the structures which can be identified—from front to back—are: tibialis posterior, flexor digitorum longus, posterior tibial artery and *venae comitantes*, the tibial nerve and flexor hallucis longus.

• **Branches:**

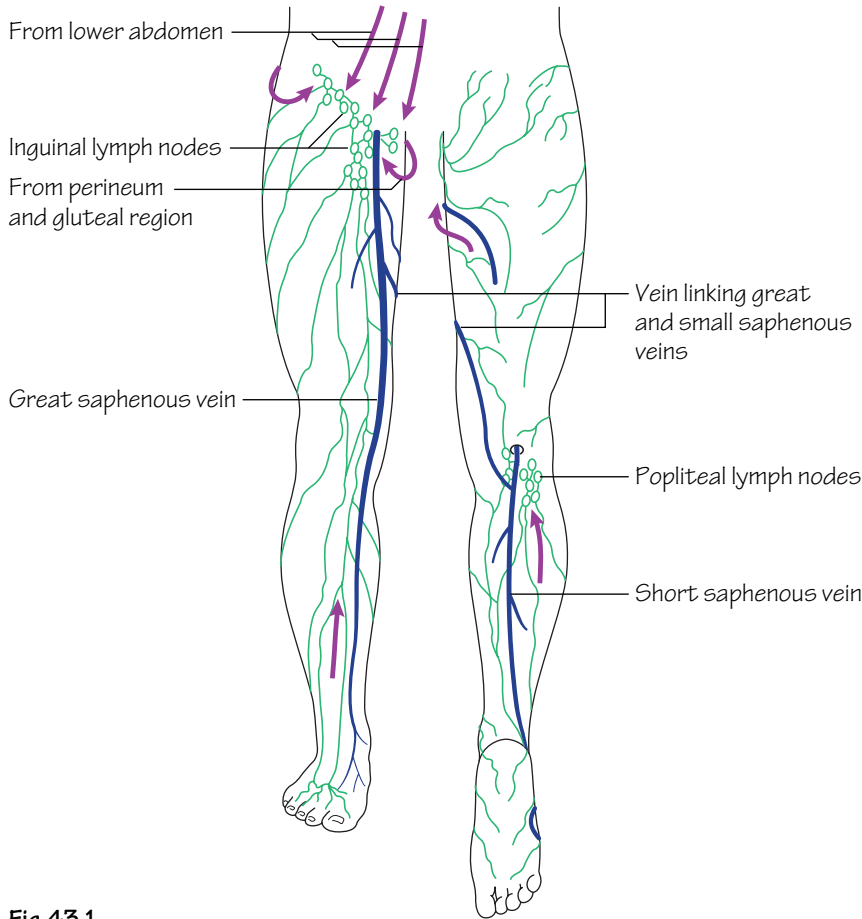
- **Peroneal artery**—this artery usually arises from the posterior tibial artery approximately 2.5 cm along its length. It courses between tibialis posterior and flexor hallucis longus and supplies the peroneal (lateral) compartment of the leg. It ends by dividing into a *perforating branch* that pierces the interosseous membrane and a *lateral calcaneal branch*.
- **Other branches**—the *posterior tibial artery* gives rise to *nutrient* and *muscular* branches throughout its course.
- **Lateral plantar artery**—passes between flexor accessorius and flexor digitorum brevis to the lateral aspect of the sole where it divides into *superficial* and *deep* branches. The deep branch runs between the 3rd and 4th muscle layers of the sole to continue as the *deep plantar arch* which is completed by the termination of the dorsalis pedis artery. The arch gives rise to *plantar metatarsal* branches which supply the toes (Fig. 42.2).
- **Medial plantar artery**—runs on the medial aspect of the sole and sends branches which join with the plantar metatarsal branches of the lateral plantar artery to supply the toes.

## Peripheral vascular disease (Fig. 42.3)

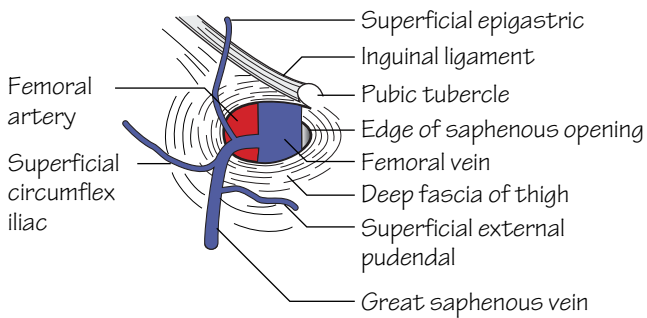
*Atheroma causes narrowing of the peripheral arteries with a consequent reduction in flow. Whilst flow may be adequate for tissue perfusion at rest, exercise causes pain due to ischaemia (intermittent claudication). When symptoms are intolerable, pain is present at rest or ischaemic ulceration has occurred, arterial reconstruction is required. Reconstruction is performed using either the patient's own saphenous vein or a synthetic graft (Dacron or PTFE) to bypass the occlusion. Disease which is limited in extent may be suitable for interventional procedures such as percutaneous transluminal angioplasty (PTA) or stent insertion.*



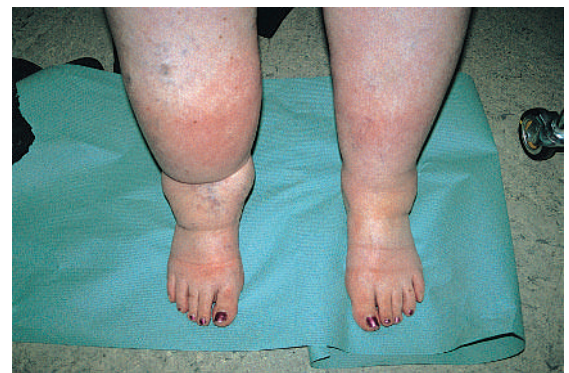# 43 The veins and lymphatics of the lower limb



**Fig.43.1**  
The superficial veins and lymphatics of the lower limb.  
The arrows indicate the direction of lymph flow



**Fig.43.2**  
The termination of the great saphenous vein



**Fig.43.3**  
Lymphoedema of the lower limb

### The superficial veins of the lower limb (Fig. 43.1)

The superficial system comprises the *great* and *small saphenous veins*. These are of utmost clinical importance as they are predisposed towards becoming varicose and consequently often require surgery. They are also the commonly used conduits for coronary artery surgery.

- The *great saphenous vein* arises from the medial end of the dorsal venous network on the foot. It passes anterior to the medial malleolus, along the anteromedial aspect of the calf (with the saphenous nerve), migrates posteriorly to a handbreadth behind patella at the knee and then courses forward to ascend the anteromedial thigh. It pierces the cribriform fascia to drain into the femoral vein at the saphenous opening. The terminal part of the great saphenous vein usually receives superficial tributaries from the external genitalia and the lower abdominal wall (Fig. 43.2). At surgery these help to distinguish the saphenous from the femoral vein as the only tributary draining into the latter is the saphenous vein. *Anteromedial* and *posterolateral femoral (lateral accessory)* tributaries, from the medial and lateral aspects of the thigh, also sometimes drain into the great saphenous vein below the saphenous opening.

The great saphenous vein is connected to the deep venous system at multiple levels by *perforating veins*. These usually occur above and below the medial malleolus, in the gaiter area, in the mid-calf region, below the knee and one long connection in the lower thigh. The valves in the perforators are directed inwards so that blood flows from superficial to deep systems from where it can be pumped upwards assisted by the muscular contractions of the calf muscles. The deep system is consequently at higher pressure than the superficial and thus, should the valves in the perforators become incompetent, the increased pressure is transmitted to the superficial system and these veins become varicose.

- The *small saphenous vein* arises from the lateral end of the dorsal venous network on the foot. It passes behind the lateral malleolus and over the back of the calf to pierce the deep fascia in an inconstant position to drain into the popliteal vein.

### The deep veins of the lower limb

The deep veins of the calf are the *venae comitantes* of the *anterior* and *posterior tibial arteries* which go on to become the *popliteal* and *femoral veins*. The deep veins form an extensive network within the

posterior compartment of the calf—the *soleal plexus* from which blood is assisted upwards against gravitational forces by muscular contraction during exercise. Failure of this ‘muscle pump’ to work efficiently, as occurs, for instance, during long flights in cramped conditions, may cause deep venous thrombosis (DVT).

### Varicose veins

*These are classified as:*

- **Primary:** due to inherent valve dysfunction.
- **Secondary:** due to impedance of flow within the deep venous circulation. These can occur in pregnancy or due to obstruction caused by pelvic tumours or previous deep venous thrombosis.

*In both cases the superficial veins are subjected to increased pressure and become varicose.*

### The lymphatics of the lower limb (Fig. 43.1)

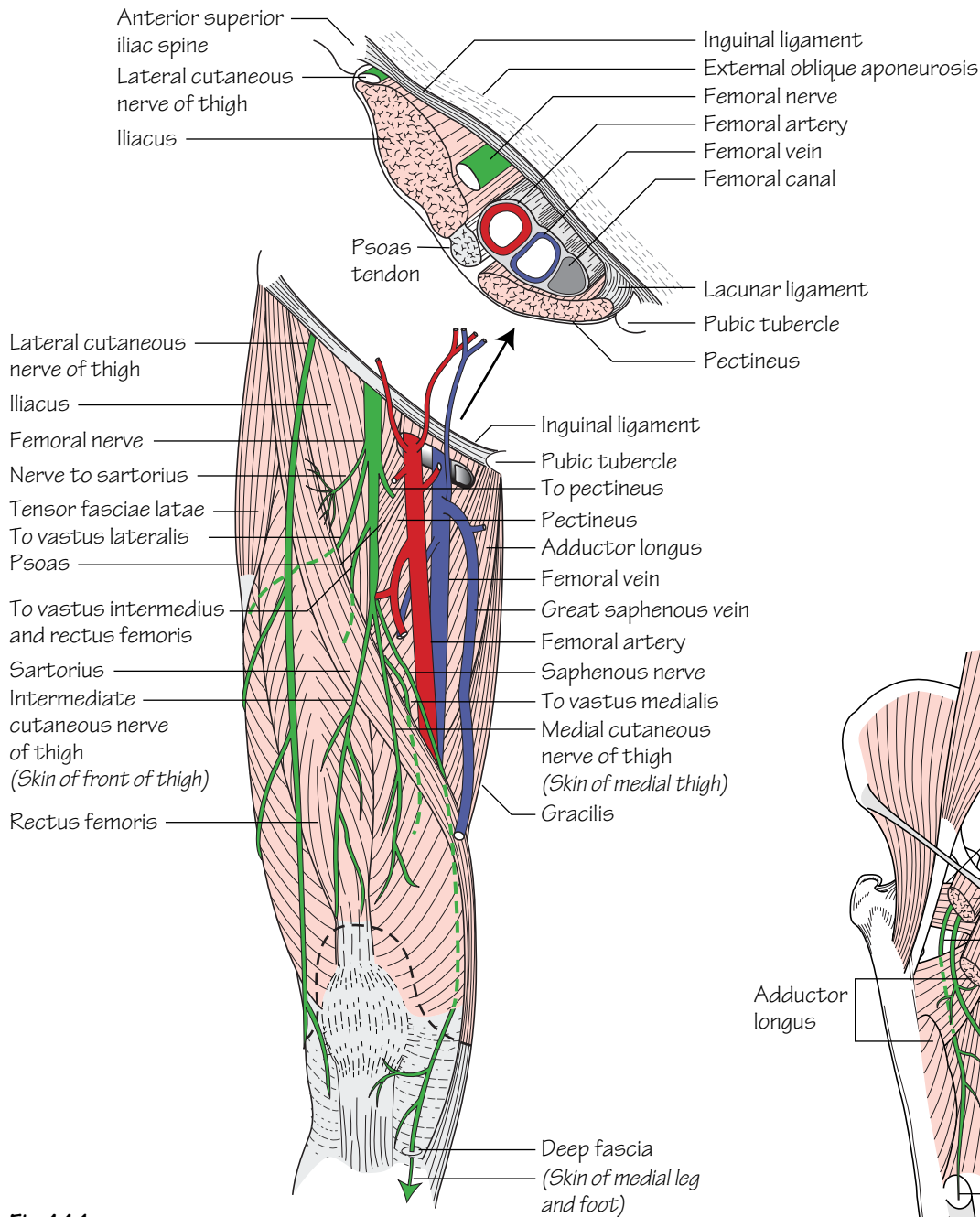
The lymph nodes of the groin are arranged into *superficial* and *deep* groups. The superficial inguinal group lie in the superficial fascia and are arranged in two chains:

- *Longitudinal chain:* these lie along the terminal portion of the saphenous vein. They receive lymph from the majority of the superficial tissues of the lower limb.
- *Horizontal chain:* these lie parallel to the inguinal ligament. They receive lymph from the superficial tissues of the lower trunk below the level of the umbilicus, the buttock, the external genitalia and the lower half of the anal canal. The superficial nodes drain into the deep nodes through the saphenous opening in the deep fascia.

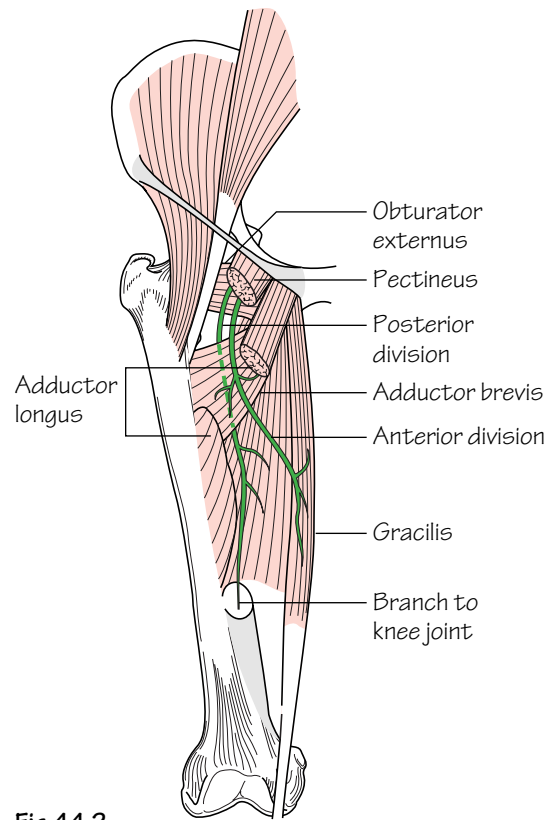
The deep inguinal nodes are situated medial to the femoral vein. They are usually three in number. These nodes receive lymph from all of the tissues deep to the fascia lata of the lower limb. In addition they also receive lymph from the skin and superficial tissues of the heel and lateral aspect of the foot by way of the popliteal nodes. The deep nodes convey lymph to external iliac and thence to the para-aortic nodes.

*Obstruction of lymphatics results in lymphoedema (Fig. 43.3). This can be congenital, due to aberrant lymphatic formation, or acquired such as post radiotherapy or following certain infections. In developing countries infection with *Filaria bancrofti* is a significant cause of lymphoedema that can progress to massive proportions requiring limb reduction or even amputation.*

# 44 The nerves of the lower limb I



**Fig.44.1**  
The femoral nerve and its major branches. The upper diagram shows the structures that pass under the inguinal ligament



**Fig.44.2**  
The anterior and posterior divisions of the obturator nerve

### The lumbar plexus (T12–L5) (see Fig. 21.1)

See Chapter 21.

- **Origins:** from the anterior primary rami of T12–L5.
- **Course:** the majority of the branches of the plexus pass through the substance of psoas major and emerge at its lateral border except for the genitofemoral and obturator nerves.
- **Branches:**
  - **Intra-abdominal branches**—these are described in Chapter 21.
  - **Femoral nerve (L2,3,4)**—see below.
  - **Obturator nerve (L2,3,4)**—see below.
  - **Lateral cutaneous nerve of the thigh (L2,3)**—crosses the iliac fossa over iliacus and passes under the lateral part of the inguinal ligament to enter the superficial tissue of the lateral thigh which it supplies. Obese patients sometimes describe paraesthesiae over the lateral thigh. This is termed *meralgia paraesthetica* and results from compression of this nerve as it passes under the inguinal ligament.

### The femoral nerve (L2,3,4) (Fig. 44.1)

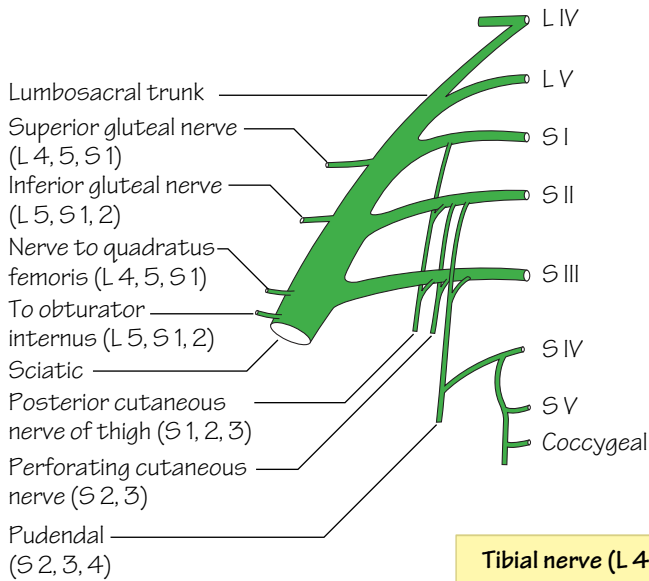
- **Origins:** the *posterior divisions* of the anterior primary rami of L2,3,4.
- **Course:** the femoral nerve traverses psoas to emerge at its lateral border. It descends through the iliac fossa to pass under the inguinal ligament. At this point it lies on iliacus, which it supplies, and is situated immediately lateral to the femoral sheath. It branches within the femoral triangle only a short distance (5 cm) beyond the inguinal ligament. The *lateral circumflex femoral artery* passes through these branches to divide them into *superficial* and *deep* divisions:

- **Superficial division**—consists of *medial* and *intermediate cutaneous branches*, which supply the skin over the anterior and medial aspects of the thigh, and two muscular branches. The latter supply sartorius and pectineus.
- **Deep division**—consists of four muscular branches which supply the components of quadriceps femoris and one cutaneous nerve—the *saphenous* nerve. The latter nerve is the only branch to extend beyond the knee. It pierces the deep fascia overlying the adductor canal and descends through the leg, accompanied by the great saphenous vein, to supply the skin over the medial aspect of the leg and foot.

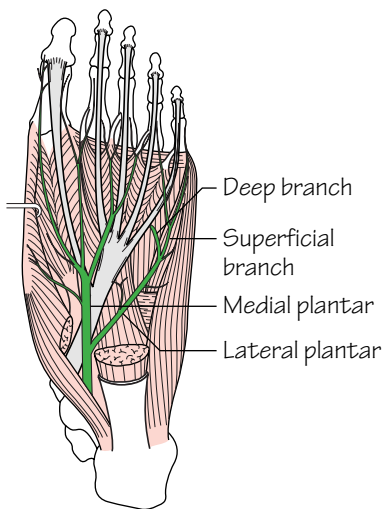
### The obturator nerve (L2,3,4) (Fig. 44.2)

- **Origins:** the *anterior divisions* of the anterior primary rami of L2,3,4.
- **Course:** the obturator nerve emerges at the medial border of psoas (cf. other nerves which traverse psoas to emerge at the lateral border). It passes over the pelvic brim to pass through the upper aspect of the *obturator foramen* with other obturator vessels. In the obturator notch it divides into *anterior* and *posterior* divisions which pass in front of and behind adductor brevis to supply the muscles of the adductor compartment:
  - **Anterior division**—gives rise to an articular branch to the hip joint as well as muscular branches to adductor longus, brevis and gracilis. It terminates by supplying the skin of the medial aspect of the thigh.
  - **Posterior division**—supplies muscular branches to obturator externus, adductor brevis and magnus and obturator externus as well as an articular branch to the knee.

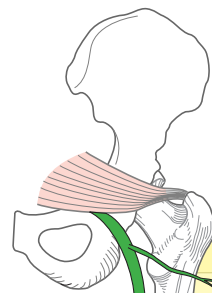
# 45 The nerves of the lower limb II



**Fig.45.1**  
The sacral plexus



**Fig.45.3**  
The medial and lateral plantar nerves



**Fig.45.2**  
The sciatic nerve and its major branches

**Sciatic nerve (L 4–S 3)**

- Nerve to quadratus femoris (L 4, 5, S 1)
- Nerve to obturator internus (L 5, S 1, 2)
- Muscular branches to hamstrings (semitendinosus, semimembranosus and biceps femoris) and hamstring part of adductor magnus

**Tibial nerve (L 4, 5, S 1, 2, 3)**

Muscular branches to:

- plantaris
- popliteus
- gastrocnemius
- soleus

Knee joint

Sural nerve (skin of lower lateral calf, lateral foot and little toe)

Muscular branches to:

- flexor digitorum longus
- flexor hallucis longus
- tibialis posterior

Medial plantar (L 4, 5)

Lateral plantar (S 1, 2)

**Common peroneal nerve (L 4–S 2)**

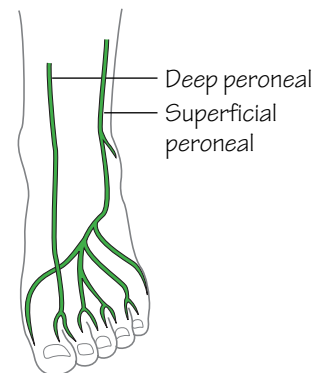
Lateral cutaneous nerve of the calf

Knee joint

Sural communicating nerve

Superficial peroneal nerve (supplies: peroneus longus, brevis, and skin)

Deep peroneal nerve (supplies: extensor digitorum longus, tibialis anterior, extensor hallucis longus, peroneus tertius, extensor digitorum brevis and skin of the 1st dorsal web space)





### The sacral plexus (L4–S4) (Fig. 45.1)

- **Origins:** from the anterior primary rami of L4–S4.
- **Course:** the sacral nerves emerge through the anterior sacral foramina. The nerves unite, and are joined by the lumbosacral trunk (L4,5), anterior to piriformis.
- **Branches:** the branches of the sacral plexus include:
  - **The superior gluteal nerve (L4,5,S1)**—arises from the roots of the sciatic nerve and passes through the greater sciatic foramen above the upper border of piriformis. In the gluteal region it runs below the middle gluteal line between gluteus medius and minimus (both of which it supplies) before terminating in the substance of tensor fasciae latae.
  - **The inferior gluteal nerve (L5,S1,2)**—arises from the roots of the sciatic nerve and passes through the greater sciatic foramen below piriformis. In the gluteal region it penetrates and supplies gluteus maximus.
  - **The posterior cutaneous nerve of the thigh (S1, 2, 3)**—passes through the greater sciatic foramen below piriformis. Its branches supply the skin of the scrotum, buttock and back of the thigh up to the knee.
  - **The perforating cutaneous nerve (S2, 3)**—perforates gluteus maximus to supply the skin of the buttock.
  - **The pudendal nerve (S2, 3, 4)**—passes briefly into the gluteal region by passing out of the greater sciatic foramen below piriformis over the sacrospinous ligament and passes back into the pelvis through the lesser sciatic foramen. It runs forwards in the pudendal (Alcock's) canal and gives off its inferior rectal branch in the ischio-rectal fossa. It continues its course to the perineum and divides into dorsal and perineal branches that pass deep and superficial to the urogenital diaphragm, respectively.
- The sciatic nerve—see below.

### The sciatic nerve (L4–S3) (Fig. 45.2)

- **Origins:** anterior primary rami of L4,5,S1,S2,S3.
- **Course:** the sciatic nerve passes through the greater sciatic foramen below piriformis under the cover of gluteus maximus. In the gluteal region it passes over the superior gemellus, obturator internus and inferior gemellus and then over quadratus femoris and adductor magnus in the thigh as it descends in the midline. The sciatic divides into its terminal branches, the tibial and common peroneal nerves, usually just below the mid-thigh, although a higher division is not uncommon.
- **Branches:**
  - **Muscular branches**—to the hamstrings and the ischial part of adductor magnus.
  - **Nerve to obturator internus (L5,S1,2)**—supplies obturator internus and the superior gemellus.
  - **Nerve to quadratus femoris (L4,5,S1)**—supplies quadratus femoris and the inferior gemellus.
  - **Tibial nerve**—see below.
  - **Common peroneal nerve**—see below.

### The tibial nerve (L4–S3) (Fig. 45.2)

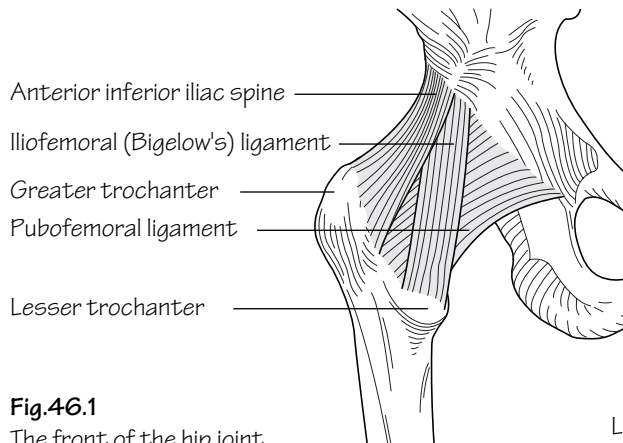
- **Origins:** it is a terminal branch of the sciatic nerve.
- **Course:** it traverses the popliteal fossa over the popliteal vein and artery from the lateral to medial side. It leaves the popliteal fossa by passing under the fibrous arch of soleus and, in the leg, descends with the posterior tibial artery under the cover of this muscle. The nerve crosses the posterior tibial artery from medial to lateral in the mid-calf and, together with the artery, passes behind the medial malleolus and then under the flexor retinaculum where it divides into its terminal branches, the *medial* and *lateral plantar* nerves.
- **Main branches:**
  - **Genicular branches**—to the knee joint.
  - **Muscular branches**—to plantaris, soleus, gastrocnemius and the deep muscles at the back of the leg.
  - **Sural nerve**—arises in the popliteal fossa and is joined by the sural communicating branch of the deep peroneal nerve. It pierces the deep fascia in the calf and descends subcutaneously with the small saphenous vein. It passes behind the lateral malleolus and under the flexor retinaculum to divide into its cutaneous terminal branches which supply the skin of the lower lateral calf, foot and little toe.
  - **Medial plantar nerve (L4,5)** (Fig. 45.3)—runs with the medial plantar artery between abductor hallucis and flexor digitorum brevis. It sends four motor branches and a cutaneous supply to the medial 3½ digits.
  - **Lateral plantar nerve (S1,2)** (Fig. 45.3)—runs with the lateral plantar artery to the base of the 5th metatarsal where it divides into superficial and deep branches. These collectively supply the skin of the lateral 1½ digits and the remaining muscles of the sole.

### The common peroneal nerve (L4–S2) (Fig. 45.2)

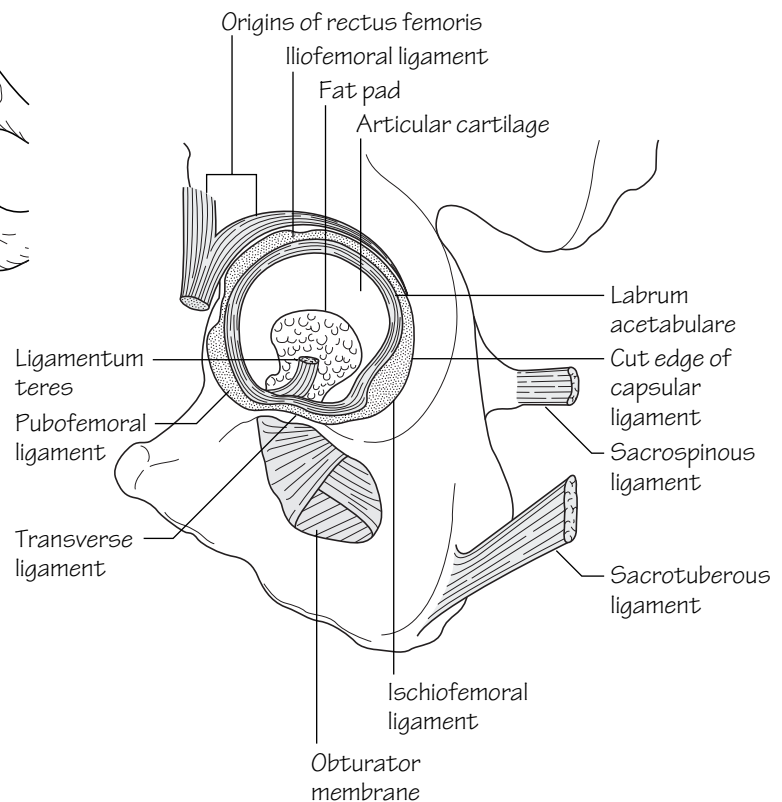
- **Origin:** a terminal branch of the sciatic nerve.
- **Course:** it passes along the medial border of the biceps tendon along the superolateral margin of the popliteal fossa. The nerve winds around the neck of the fibula and, in the substance of peroneus longus, it divides into its terminal branches, the *superficial* and *deep peroneal nerves*.
- **Branches:**
  - **Genicular branches** to the knee joint.
  - **Lateral cutaneous nerve of the calf.**
  - **A sural communicating branch.**
  - **Superficial peroneal nerve (L5,S1,2)**—this branch runs in and supplies the muscles of the lateral (peroneal) compartment of the leg. In addition it supplies the skin over the lateral lower two-thirds of the leg and the whole of the dorsum of the foot except for the area between the 1st and 2nd toes, which is supplied by the deep peroneal nerve.
  - **Deep peroneal nerve (L4,5,S1,2)**—runs with the anterior tibial vessels over the interosseous membrane into the anterior compartment of the leg and then over the ankle to the dorsum of the foot. It supplies all of the muscles of the anterior compartment as well as providing a cutaneous supply to the area between the 1st and 2nd toes.



## 46 The hip joint and gluteal region



**Fig.46.1**  
The front of the hip joint



**Fig.46.2**  
The structures around the acetabulum

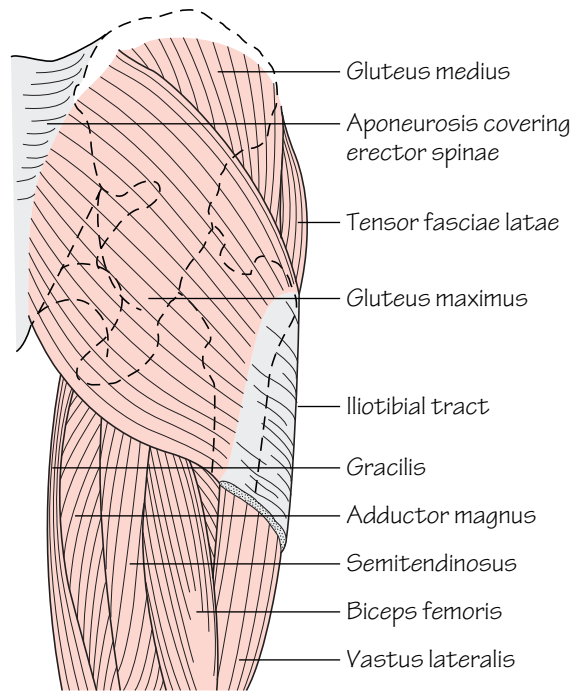
### The hip joint (Figs 46.1, 46.2 and 46.5)

- **Type:** the hip is a *synovial ball and socket joint*. The articulation is between the rounded femoral head and the acetabulum which, like the shoulder, is deepened at its margins by a fibrocartilaginous rim—the *labrum acetabulare*. The central and inferior parts of the acetabulum are devoid of articulating surface. This region is termed the *acetabular notch* from which the *ligamentum teres* passes to the *fovea* on the femoral head. The inferior margin below the acetabular notch is completed by the *transverse acetabular ligament*.
- **Capsule:** the capsule of the hip joint is attached above to the acetabular margin, including the transverse acetabular ligament. The capsule attaches to the femur anteriorly at the *trochanteric line* and to the bases of the trochanters. Posteriorly the capsule attaches to the femur at a higher level—approximately 1 cm above the *trochanteric crest*. The capsular fibres are reflected from the lower attachment upwards on the

femoral neck as *retinacula*. These fibres are of extreme importance as they carry with them a blood supply to the femoral head.

- **Stability:** the stability of the hip is dependent predominantly on bony factors. Ligamentous stability is provided by three ligaments:

- (a) *Iliofemoral ligament (Bigelow's ligament)*—is inverted, Yshaped and strong. It arises from the *anterior inferior iliac spine* and inserts at either end of the *trochanteric line*. This ligament prevents hyperextension at the hip.
- (b) *Pubofemoral ligament*—arises from the iliopubic junction and passes to the capsule over the trochanteric line where it attaches.
- (c) *Ischiofemoral ligament*—fibres arise from the ischium and some encircle laterally to attach to the base of the greater trochanter. The majority of the fibres, however, spiral and blend with the capsule around the neck of the femur—the *zona orbicularis*.



**Fig.46.3**

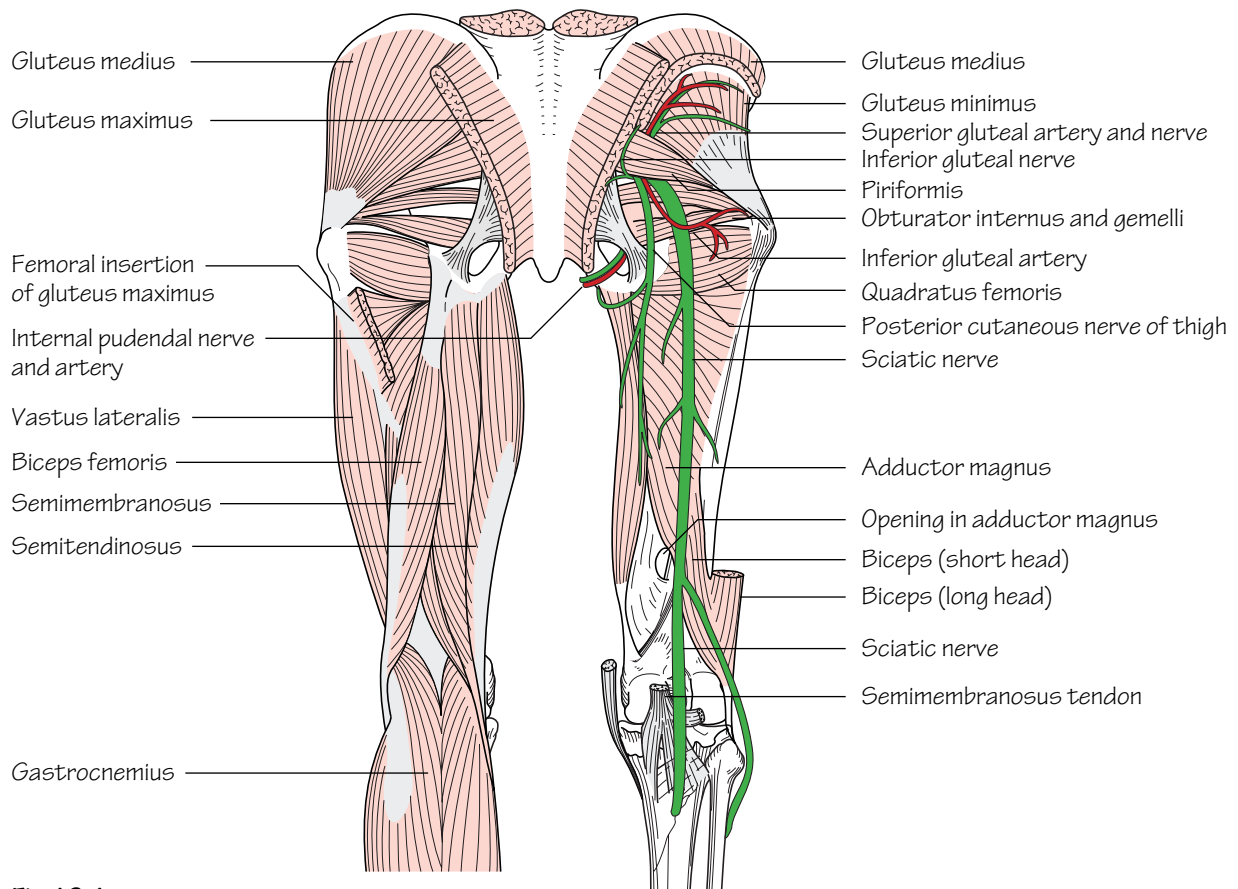
The superficial muscles of the gluteal region

- **Synovium:** the synovial membrane lines the capsule of the hip joint and is reflected back along the femoral neck. It invests the ligamentum teres as a sleeve and attaches to the articular margins. A *psoas bursa* occurs in 10% of the population. This is an outpouching of synovial membrane through a defect in the anterior capsular wall under the psoas tendon.
- **Blood supply** (Fig. 46.6): the femoral head derives its blood supply from three main sources:
  - 1 Vessels which pass along the neck with the capsular retinacula and enter the head through large foramina at the base of the head.

These are derived from branches of the circumflex femoral arteries via the cruciate and trochanteric anastomoses. This is the most important supply in the adult.

- 2 Vessels in the ligamentum teres which enter the head through small foramina in the fovea. These are derived from branches of the obturator artery.
- 3 Through the diaphysis via nutrient femoral vessels.

- **Nerve supply:** is from branches of the femoral, sciatic and obturator nerves.



**Fig.46.4**

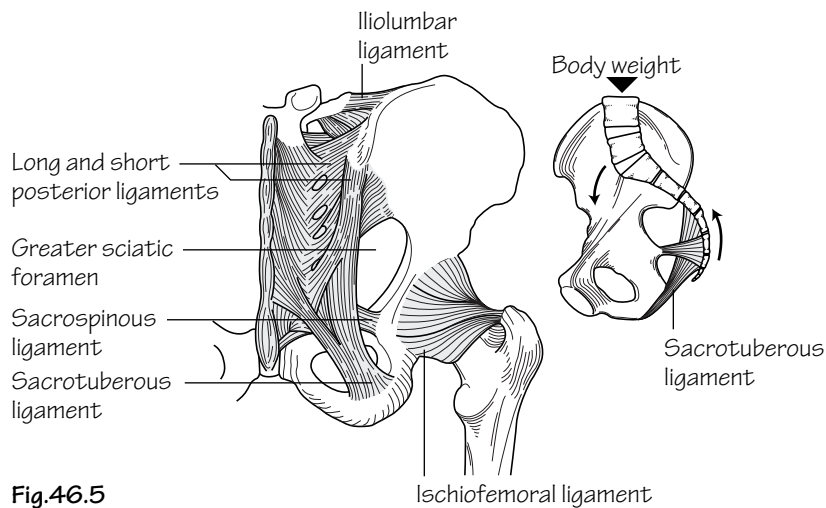
The deeper structures in the gluteal region after the removal of gluteus maximus and medius

### Hip movements

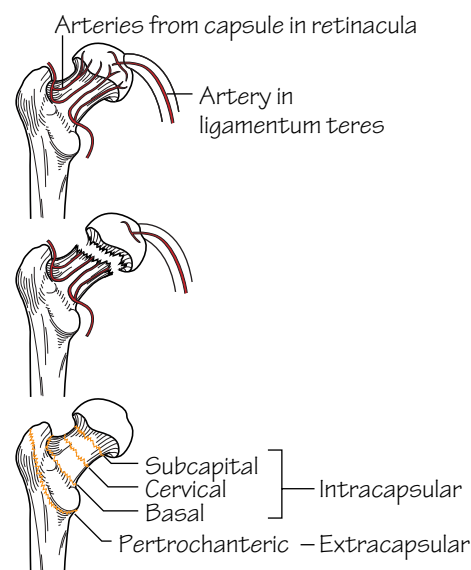
A wide range of movement is possible at the hip due to the ball and socket articulation.

- **Flexion (0–120°):** iliacus and psoas predominantly. Rectus femoris, sartorius and pectineus to a lesser degree.
- **Extension (0–20°):** gluteus maximus and the hamstrings.
- **Adduction (0–30°):** adductor magnus, longus and brevis predominantly. Gracilis and pectineus to a lesser degree.

- **Abduction (0–45°):** gluteus medius, gluteus minimis and tensor fasciae latae.
- **Lateral rotation (0–45°):** piriformis, obturators, the gemelli, quadratus femoris and gluteus maximus.
- **Medial rotation (0–45°):** tensor fasciae latae, gluteus medius and gluteus minimis.
- **Circumduction:** this is a combination of all movements utilizing all muscle groups mentioned.



**Fig.46.5**  
The ligaments of the back of the hip.  
The smaller diagram shows how the sacrotuberous and sacrospinous ligaments resist rotation of the sacrum



**Fig.46.6**  
The terminology of fractures of the neck of the femur.  
Fractures near the head can cause avascular necrosis because of the disruption of the arterial supply to the head

### The fractured neck of femur (Fig. 46.6)

Femoral neck fractures are common following falls among the elderly osteoporotic population. Fractures in this region present a considerable risk of avascular necrosis if the fracture line is intracapsular as the retinacula, which carry the main arterial supply, are torn. In contrast, extracapsular femoral neck fractures present no risk of avascular necrosis.

If the fracture components are not impacted the usual clinical presentation is that of shortening and external rotation of the affected limb. This occurs as the adductors, hamstrings and rectus femoris pull upwards on the distal fragment whilst piriformis, the gemelli, obturators, gluteus maximus and gravity produce lateral rotation.

### The gluteal region (Figs 46.3 and 46.4)

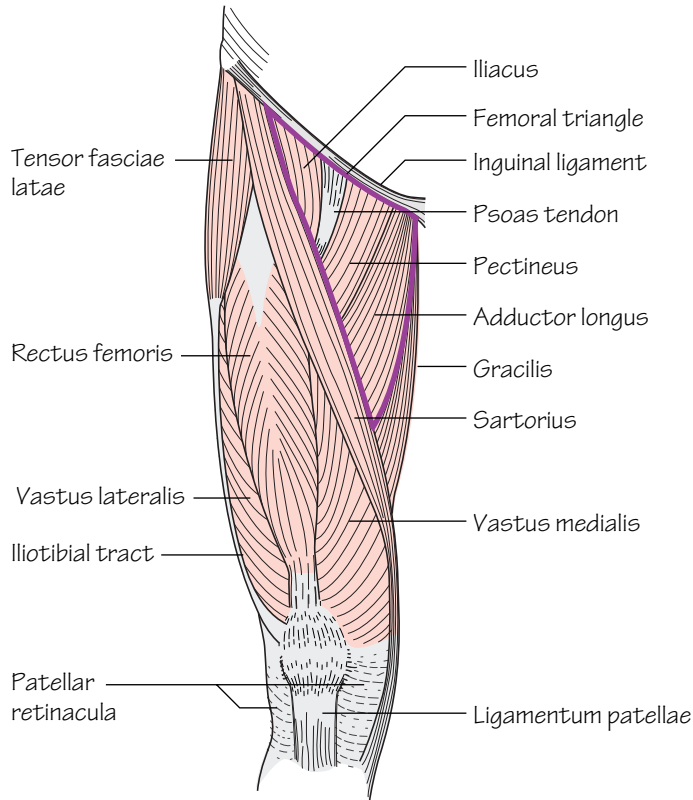
The gluteal region is limited above by the iliac crest and below by the transverse skin crease—the *gluteal fold*. The fold occurs as the overlying skin is bound to the underlying deep fascia and not, as is often thought, by the contour of gluteus maximus. The greater and lesser

sciatic foramina are formed by the pelvis and sacrotuberous and sacrospinous ligaments (Fig. 46.5). Through these, structures pass from the pelvis to the gluteal region.

### Contents of the gluteal region (Fig. 46.4)

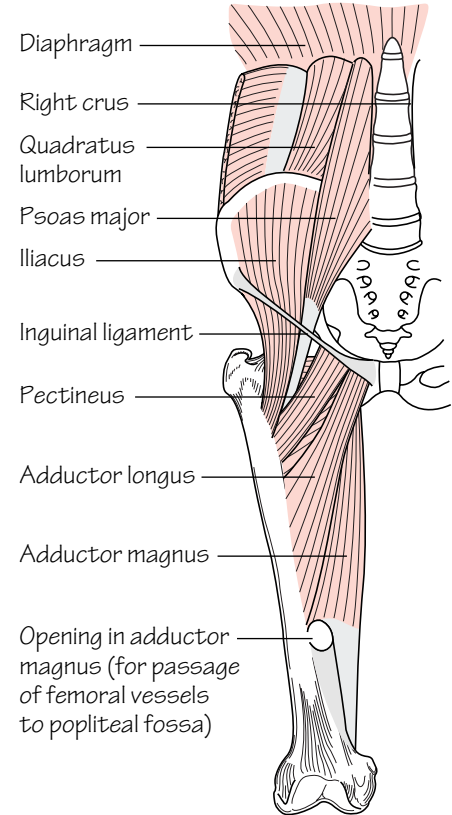
- **Muscles:** of the gluteal region include: *gluteus maximus*, *gluteus medius*, *gluteus minimus*, *tensor fasciae latae*, *piriformis*, *gemellus superior*, *gemellus inferior*, *obturator internus* and *quadratus femoris* (see Muscle index, p. 164).
- **Nerves:** of the gluteal region include the: *sciatic nerve* (L4,5,S1–3), *posterior cutaneous nerve of the thigh, superior* (L4,5,S1,2) and *inferior gluteal* (L5,S1,2) nerves, *nerve to quadratus femoris* (L4,5,S1) and the *pudendal nerve* (S2–4).
- **Arteries:** of the gluteal region include the: *superior* and *inferior gluteal arteries*. These anastomose with the medial and lateral femoral circumflex arteries, and the first perforating branch of the profunda, to form the trochanteric and cruciate anastomoses, respectively.

## 47 The thigh



**Fig.47.1**

The muscles of the front of the thigh.  
The femoral triangle is outlined



**Fig.47.2**

Psoas, iliacus and the adductor group of muscles

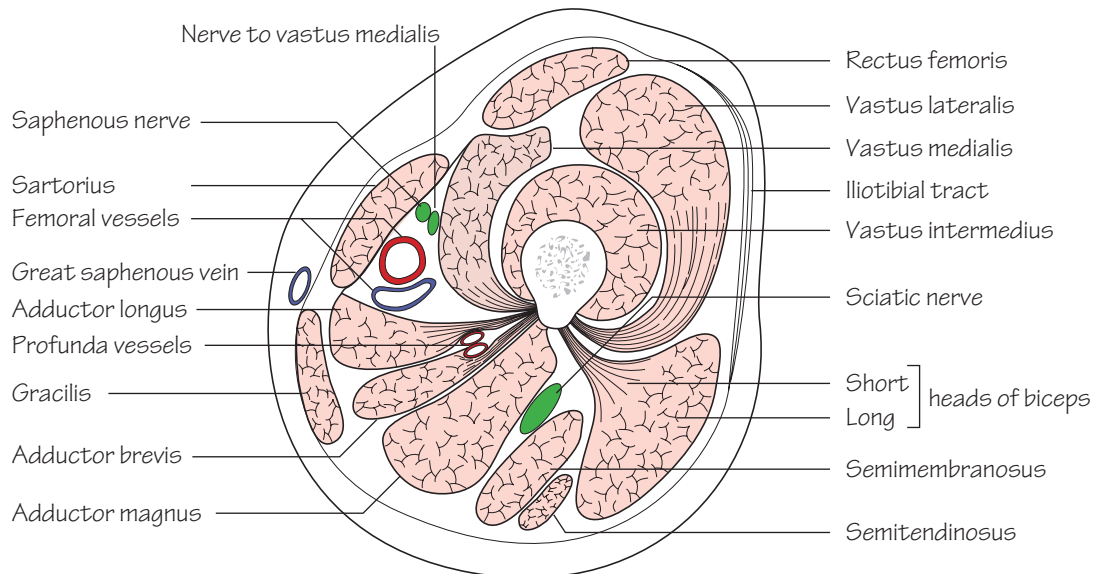
The thigh is divided into flexor, extensor and adductor compartments. The membranous superficial fascia of the abdominal wall fuses to the *fascia lata*, the deep fascia of the lower limb, at the skin crease of the hip joint just below the inguinal ligament.

### The deep fascia of the thigh (*fascia lata*)

This layer of strong fascia covers the thigh. It is attached above to the inguinal ligament and bony margins of the pelvis and below to the tibial condyles, head of the fibula and patella. Three fascial septa pass from the deep surface of the fascia lata to insert onto the linea aspera of the femur and consequently divide the thigh into three compartments.

On the lateral side the fascia lata is condensed to form the *iliotibial tract* (Fig. 47.4). The tract is attached above to the iliac crest and receives the insertions of tensor fasciae latae and three-quarters of gluteus maximus. These muscles are also enveloped in deep fascia. The iliotibial tract inserts into the lateral condyle of the tibia.

The *saphenous opening* is a gap in the deep fascia which is filled with loose connective tissue—the *cribriform fascia*. The lateral border of the opening, the *falciform margin*, curves in front of the femoral vessels whereas on the medial side it curves behind to attach to the iliopectineal line (Fig. 43.1). The great saphenous vein pierces the cribriform fascia to drain into the femoral vein. Superficial branches of the femoral artery and lymphatics are also transmitted through the saphenous opening.



**Fig.47.3**

A section through the thigh to show the adductor (subsartorial) canal

### The superficial fascia of the thigh

Contents of the subcutaneous tissue include:

- **Nerves:** the femoral branch of the genitofemoral nerve (p. 51), the medial, intermediate (branches of the femoral nerve, p. 99) and lateral femoral cutaneous nerves (L2,3, p. 99) and branches of the obturator nerve (p. 99) supply the skin of the anterior thigh. The back of the thigh receives its sensory supply from the posterior cutaneous nerve of the thigh.
- **Superficial arteries:** these include the four superficial branches of the femoral artery: the superficial circumflex iliac artery, superficial epigastric artery, superficial external pudendal artery and the deep external pudendal artery.
- **Superficial veins and lymphatics:** venous tributaries of the anterior thigh drain into the great saphenous vein whilst some in the lower posterior thigh drain into the popliteal vein. The great saphenous vein is also accompanied by large lymphatics which pass to the superficial inguinal nodes and, from there, through the cribriform fascia to the deep inguinal nodes.

### The femoral triangle (Figs 44.1 and 47.1)

The boundaries of the femoral triangle are: the inguinal ligament above, the *medial* border of sartorius and the *medial* border of adductor longus.

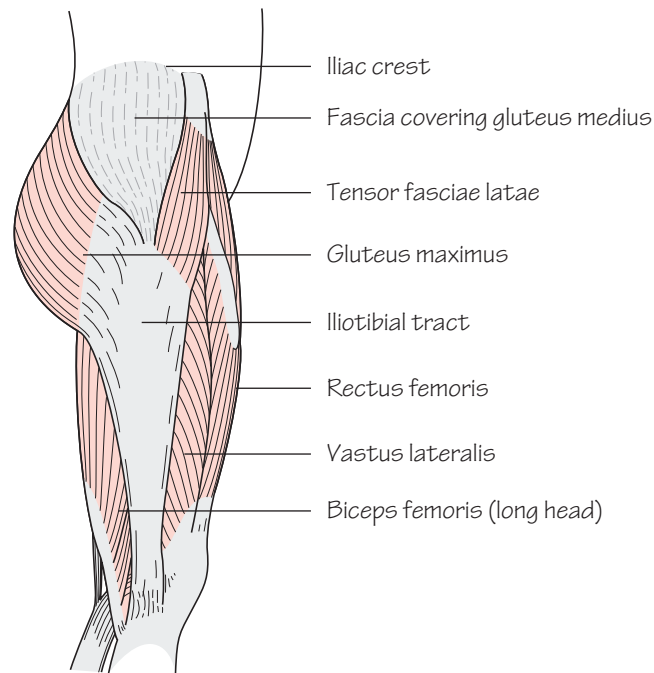
- **The floor consists of:** adductor longus, pectineus, psoas tendon and iliacus (see Muscle index, p. 165).

- **The roof consists of:** fascia lata. The saphenous opening is in the upper part of the triangle.
- **The contents include** (from lateral to medial) the: femoral nerve, artery, vein and their branches and tributaries. The *femoral canal* is situated medial to the femoral vein. Transversalis fascia and psoas fascia fuse and evaginate to form the *femoral sheath* below the inguinal ligament. The sheath encloses the femoral artery, vein and canal but the femoral nerve lies outside on its lateral aspect (see Fig. 44.1).

### The contents of the anterior compartment of the thigh (Fig. 47.3)

- **Muscles:** these constitute the hip flexors and knee extensors, i.e. *sartorius*, *iliacus*, *psoas*, *pectineus* and *quadriceps femoris* (see Muscle index, p. 165).
- **Arteries:** the femoral artery and its branches (p. 95).
- **Veins:** the femoral vein is a continuation of the popliteal vein as it passes through the hiatus in adductor magnus. It receives its main tributary—the *great saphenous* vein—through the saphenous opening.
- **Lymphatics:** from the anterior compartment pass to the deep inguinal lymph nodes which lie along the terminal part of the femoral vein.
- **Nerves:** the femoral nerve (L2,3,4, p. 99) divides a short distance below the inguinal ligament into anterior and posterior divisions. Only the saphenous branch passes beyond the knee.





**Fig.47.4**  
The lateral side of the thigh.  
Note the two muscles inserted  
into the iliotibial tract

### The contents of the medial compartment of the thigh

(Figs 47.2 and 47.3)

- **Muscles:** these comprise the hip adductors: *gracilis*, *adductor longus*, *adductor brevis*, *adductor magnus* and *obturator externus* (a lateral rotator of the thigh at the hip) (see Muscle index, p. 165).
- **Arteries:** profunda femoris (p. 95) as well as its medial circumflex femoral and perforating branches and the obturator artery.
- **Veins:** profunda femoris and obturator veins.
- **Nerves:** the anterior and posterior divisions of the obturator nerve (p. 99).

### The contents of the posterior compartment of the thigh

(Fig. 47.3)

- **Muscles:** these are the *hamstrings* and effect knee flexion and hip extension. They include: *biceps femoris*, *semitendinosus*, *semimembranosus* and the *hamstring part of adductor magnus* (see Muscle index, p. 165).
- **Arteries:** the perforating branches of profunda femoris.
- **Veins:** the venae comitantes of the small arteries.
- **Nerves:** the sciatic nerve (L4,5,S1–3, p. 101). The muscles of the posterior compartment are supplied by the tibial component of the sciatic nerve with the exception of the short head of biceps femoris which is supplied by the common peroneal component.

### The adductor (subsartorial or Hunter's) canal

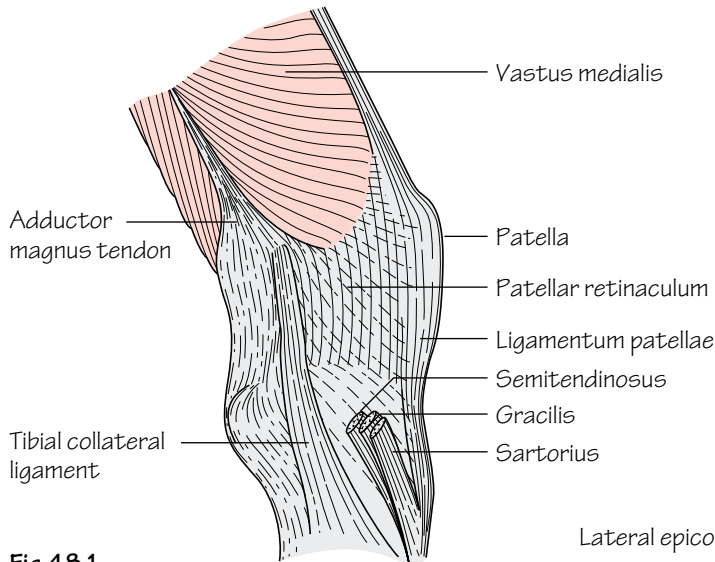
The adductor canal serves to transmit structures from the apex of the femoral triangle through the hiatus in adductor magnus into the popliteal fossa. It commences in the mid-portion of the thigh and is formed by the following walls:

- **The posterior wall:** adductor longus, with adductor magnus in the lower part of the thigh.
- **The lateral wall:** vastus medialis.
- **The roof:** thickened fascia underlying sartorius.

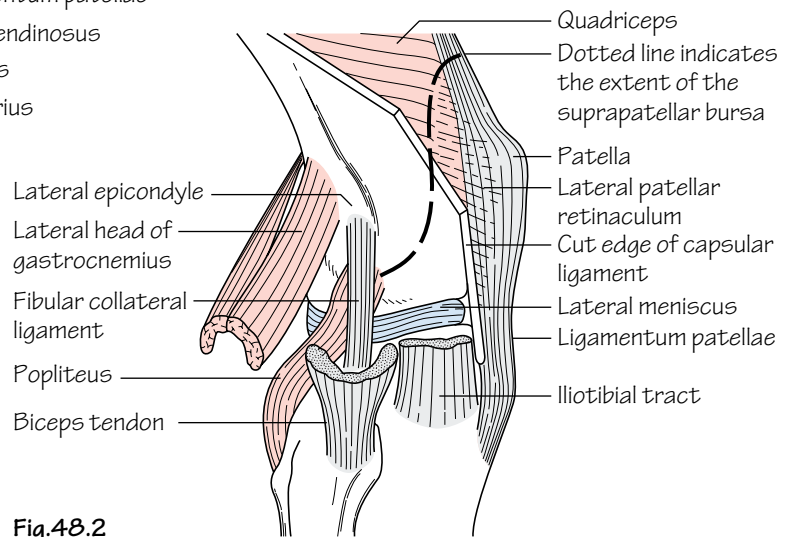
### The contents of the adductor canal

These include: the femoral artery, the femoral vein which lies deep to the femoral artery, lymphatics, the saphenous branch of the femoral nerve (which passes behind sartorius to leave the canal and descends the lower limb with the great saphenous vein), the nerve to vastus medialis (in the upper part) and the *subsartorial plexus*. This plexus is formed by branches from the saphenous nerve (terminal branch of the femoral nerve, p. 99), the anterior division of the obturator nerve and the intermediate cutaneous nerve of the thigh (branch of the femoral nerve, p. 99). It supplies the skin over the medial aspect of the knee.

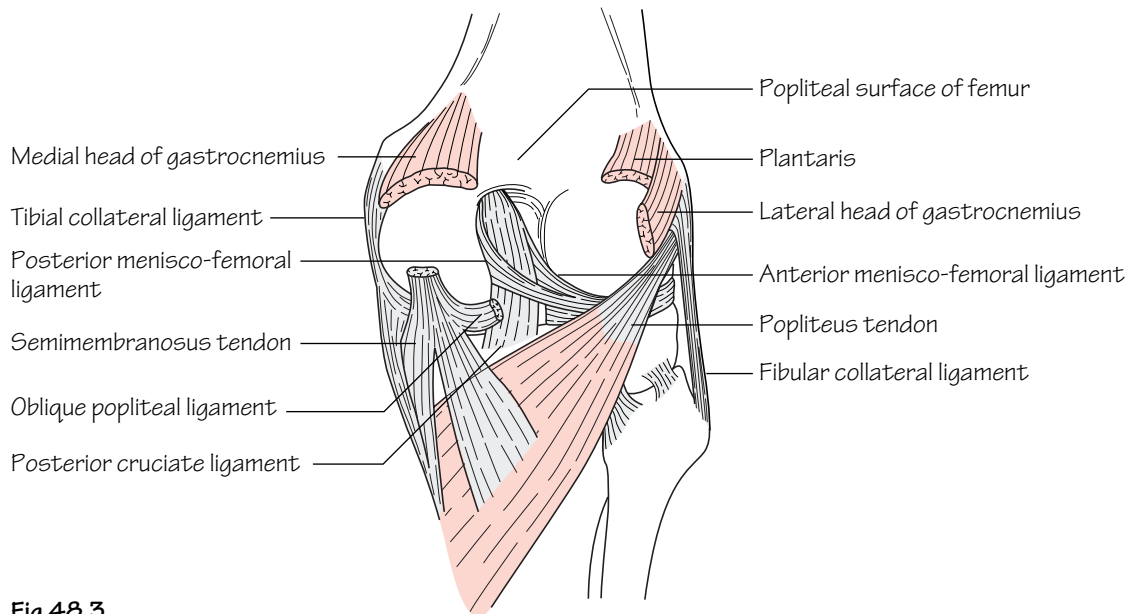
# 48 The knee joint and popliteal fossa



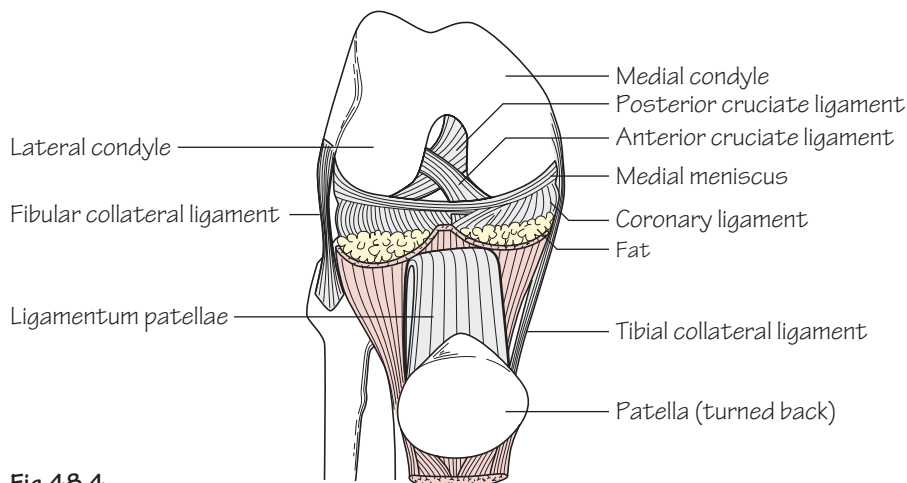
**Fig.48.1**  
Knee joint, medial aspect



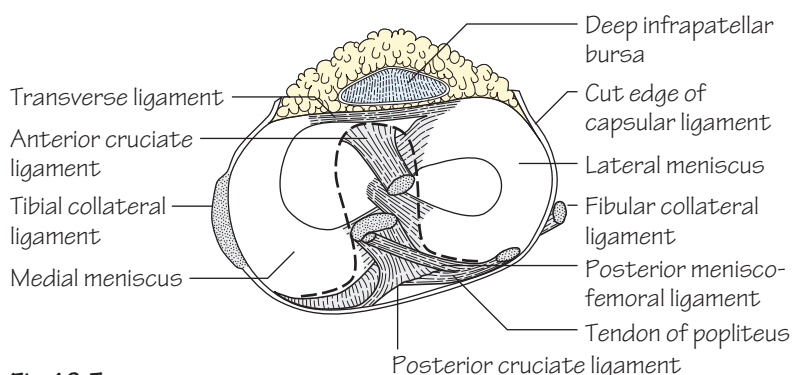
**Fig.48.2**  
Knee joint, lateral aspect after removal of part of the capsular ligament



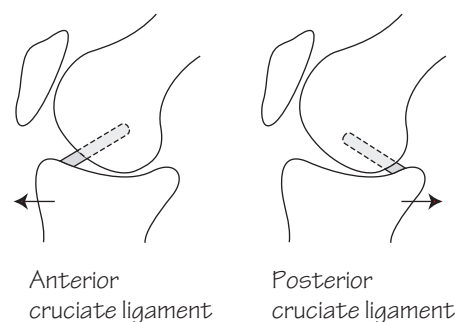
**Fig.48.3**  
Knee joint, posterior aspect after removal of the capsular ligament



**Fig.48.4**  
Anterior view of the flexed knee joint after division of the quadriceps and retraction of the patella



**Fig.48.5**  
The upper surface of the tibia and related structures.  
The dotted line indicates the synovial membrane in the vicinity of the cruciate ligaments.  
The small diagrams show how the cruciate ligaments resist forward and backward displacement of the femur



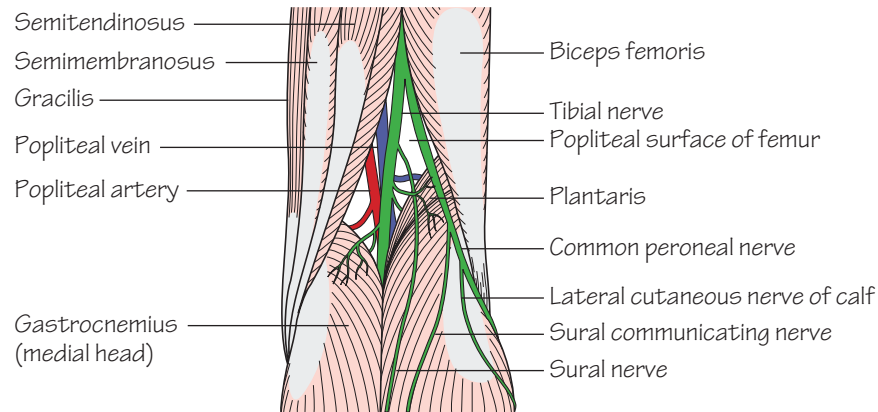
## The knee joint (Figs 48.1–48.5)

- **Type:** it is a *synovial modified hinge joint* which also permits a small degree of rotation. In the knee joint the femoral and tibial condyles articulate as does the patella and patellar surface of the femur. Note: the fibula does *not* contribute to the knee joint.
- **Capsule:** the articular surfaces are covered by articular cartilage. The capsule is attached to the margins of the articular surfaces except anteriorly where it dips downwards. In the anterior part of the capsule there is a large opening through which the synovial membrane is continuous with the *suprapatellar bursa* (Fig. 48.2). This bursa extends superiorly three fingerbreadths above the patella between the femur and quadriceps. When an effusion has collected fluctuation can be elicited. Posteriorly the capsule communicates with another *bursa* under the *medial head of gastrocnemius* and often, through it, with the *bursa of semimembranosus*. Posterolaterally another opening in the capsule permits the passage of the tendon of *popliteus*.
- **Extracapsular ligaments:** the capsule of the knee joint is reinforced by ligaments.

- The *medial (tibial) collateral ligament* (Figs 48.1 and 48.3)—consists of superficial and deep parts. The superficial component is attached above to the femoral epicondyle and below to the subcutaneous surface of the tibia. The deep component is firmly attached to the medial meniscus.
- The *lateral (fibular) collateral ligament* (Fig. 48.2)—is attached to the femoral epicondyle above and, along with biceps femoris, to the head of the fibula below. Unlike the medial collateral ligament it lies away from the capsule and meniscus.

The collateral ligaments are taut in full extension and it is in this position that they are liable to injury when subjected to extreme valgus/varus strain.

Behind the knee the *oblique popliteal ligament*, a reflected extension from the semimembranosus tendon, strengthens the capsule (Fig. 48.3). Anteriorly the capsule is reinforced by the *ligamentum patellae* and the *patellar retinacula*. The latter are reflected fibrous expansions arising from vastus lateralis and medialis muscles which blend with the capsule anteriorly (Fig. 48.1).



**Fig.48.6**  
The right popliteal fossa

• **Intracapsular ligaments:** the *cruciate ligaments* are enclosed within the knee joint (Figs 48.4 and 48.5).

- The *anterior cruciate ligament*—passes from the front of the intercondylar area of the tibia to the medial side of the lateral femoral condyle. This ligament prevents hyperextension and resists forward movement of the tibia on the femur.
- The *posterior cruciate ligament*—passes from the back of the intercondylar area of the tibia to the lateral side of the medial condyle. It becomes taut in hyperflexion and resists posterior displacement of the tibia on the femur.

• **The menisci (semilunar cartilages):** these are crescentic fibrocartilaginous ‘shock absorbers’ within the joint. They lie within deepened grooves on the articular surfaces of the tibial condyles (Fig. 48.5). The *medial meniscus* is C shaped and larger than the *lateral meniscus*. The menisci are attached to the tibial intercondylar area by their horns and around their periphery by small coronary ligaments. The lateral meniscus is loosely attached to the tibia and connected to the femur by two *menisiofemoral ligaments* (see Fig. 48.3).

*The menisci are especially prone to flexion/rotation injuries of the knee. The classic medial meniscus injury occurs when a footballer twists the knee during running. It is a combination of external rotation and abduction in flexion.*

- **Blood supply:** is from the rich anastomosis formed by the genicular branches of the popliteal artery.
- **Nerve supply:** is from branches of the femoral, tibial, common peroneal and obturator nerves.

### Knee movements

Flexion and extension are the principal movements at the knee. Some rotation is possible when the knee is flexed but is lost in extension.

During the terminal stages of extension the large medial tibial condyle screws forwards onto the femoral condyle to lock the joint. Conversely, the first stage of flexion is unlocking the joint by internal rotation of the medial tibial condyle—an action performed by popliteus.

The principal muscles acting on the knee are:

- **Extension:** quadriceps femoris.
- **Flexion:** predominantly the hamstrings but also gracilis, gastrocnemius and sartorius.
- **Rotation:** popliteus effects internal (medial) rotatory movement of the tibia.

### The popliteal fossa (Fig. 48.6)

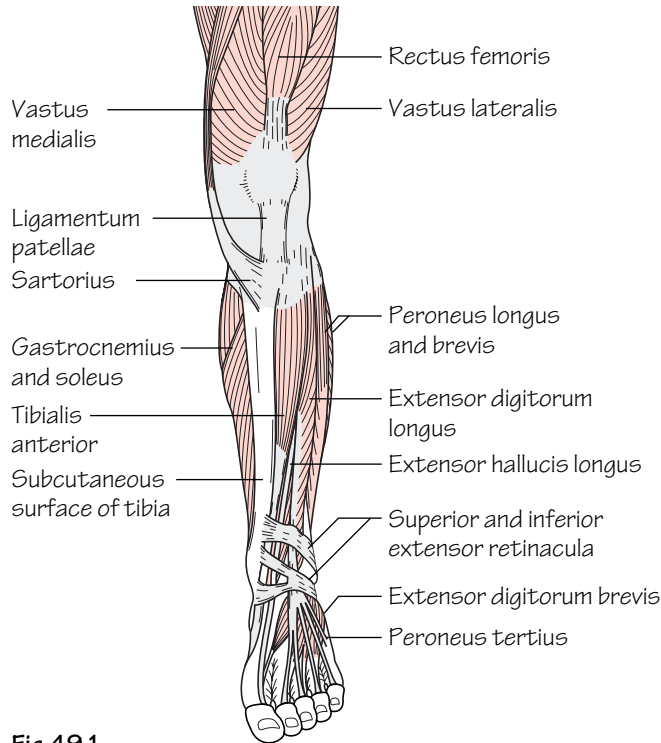
The femoral artery and vein pass through the hiatus in adductor magnus to enter the popliteal fossa and in so doing become the popliteal vessels.

The popliteal fossa is rhomboidal in shape. Its boundaries are: the biceps tendon (superolateral) and semimembranosus reinforced by semitendinosus (superomedial). The medial and lateral heads of gastrocnemius form the inferomedial and inferolateral boundaries, respectively.

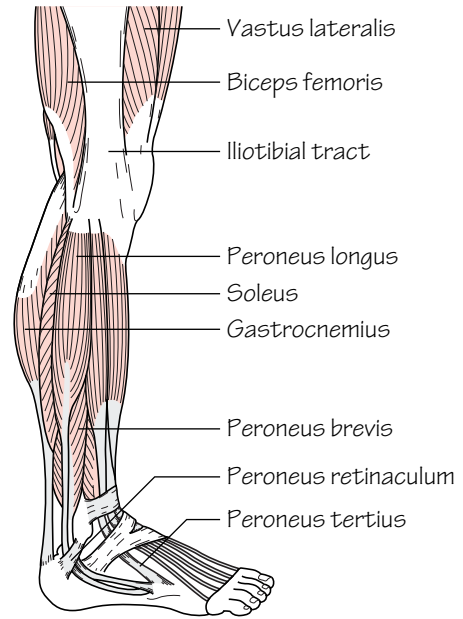
- **The roof consists of:** deep fascia which is penetrated at an inconstant position by the small saphenous vein as it drains into the popliteal vein.
- **The floor consists of** (from above downwards): the posterior lower femur, the posterior surface of the knee joint and popliteus.
- **The contents of the fossa include** (from deep to superficial): the *popliteal artery, vein and tibial nerve*. The *common peroneal nerve* runs along the medial border of biceps tendon and then out of the fossa. Other contents include fat and *popliteal lymph nodes*.

The popliteal pulse is notoriously difficult to feel because the artery lies deep to other structures. Whenever a popliteal pulse is easily palpable the possibility of aneurysmal change should be considered.

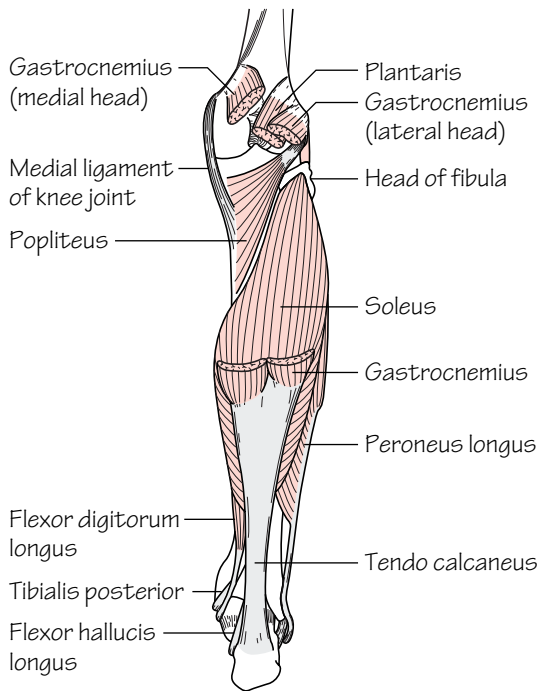
# 49 The leg



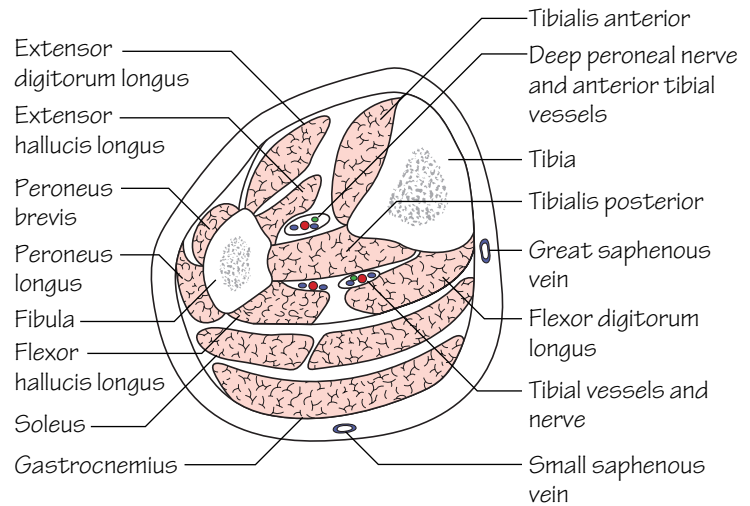
**Fig.49.1**  
The extensor (dorsiflexor) group of muscles



**Fig.49.2**  
The lateral side of the leg and foot



**Fig.49.3**  
The superficial muscles of the calf



**Fig.49.4**  
Cross-section through the leg, to be studied in conjunction with Fig.41.4

Within the leg there are three predominant muscle groups: extensor, peroneal and flexor. Each of these groups has an individual blood and nerve supply.

Students are often confused about the description of movements of the foot. Extension of the foot (dorsiflexion) refers to lifting the toes and the ball of the foot upwards. Conversely, foot flexion (plantarflexion) is the opposing action.

### The deep fascia of the leg

The deep fascia of the leg is continuous above with the deep fascia of the thigh. It envelops the leg and fuses with the periosteum of the tibia at the anterior and medial borders. Other fascial septa, and the interosseous membrane, divide the leg into four compartments: *extensor*, *peroneal*, *superficial* and *deep flexor*.

*Following fractures of the leg, oedema within one or more compartments can lead to obstruction to blood flow with consequent infarction of tissue—the ‘compartment syndrome’. When this occurs immediate decompression (fasciotomy) of all four compartments is necessary.*

### The superior and inferior tibiofibular joints

These are, respectively, synovial and fibrous joints between the tibia and fibula at their proximal and distal ends.

### The interosseous membrane (Fig. 49.4)

The interosseous borders of the tibia and fibula are connected by a strong sheet of connective tissue—the *interosseous membrane*. The fibres of the membrane run obliquely downwards from tibia to fibula. Its function is to bind together the bones of the leg as well as providing a surface for muscle attachment.

### The extensor aspects of the leg and dorsum of the foot (Figs 49.1 and 49.4)

The extensor group consists of four muscles in the leg (see below) and extensor digitorum brevis in the foot. These muscles dorsiflex the foot. The contents of the extensor compartment of the leg are as follows:

- **Muscles:** *tibialis anterior*, *extensor hallucis longus*, *extensor digitorum longus* and *peroneus tertius* (unimportant in function) (see Muscle index, p. 166).
- **Artery:** the *anterior tibial artery* (p. 95) and its *venae comitantes* form the vascular supply of the extensor compartment. The artery continues as the *dorsalis pedis artery* in the foot.
- **Nerves:** the *deep peroneal nerve* (p. 101) supplies all of the muscles of the extensor compartment. Injury to this nerve results in the inability to dorsiflex the foot—footdrop.

### The extensor retinacula (Fig. 49.1)

These are thickenings of the deep fascia of the leg. They serve to stabilize the underlying extensor tendons.

- The *superior extensor retinaculum*: is a transverse band attached to the anterior borders of the tibia and fibula.
- The *inferior extensor retinaculum*: is Y shaped. Medially the two limbs attach to the medial malleolus and the plantar aponeurosis and laterally the single limb is attached to the calcaneus.

### The peroneal compartment of the leg (Figs 49.2 and 49.4)

This compartment consists of two muscles—peroneus longus and brevis. These muscles are the predominant foot everters. The contents of the peroneal compartment include:

- **Muscles:** *peroneus longus* and *brevis* (see Muscle index, p. 166).
- **Artery:** the *peroneal artery* (p. 95).
- **Nerve:** the superficial peroneal nerve (p. 101).

### Peroneal retinacula (Fig. 49.2)

The *superior peroneal retinaculum* is a thickening of deep fascia attached from the lateral malleolus to the calcaneus. The *inferior peroneal retinaculum* is a similar band of fascia which is continuous with the inferior extensor retinaculum. The tendons of peroneus longus and brevis pass in their synovial sheaths beneath.

### The flexor aspect of the leg (Fig. 49.3)

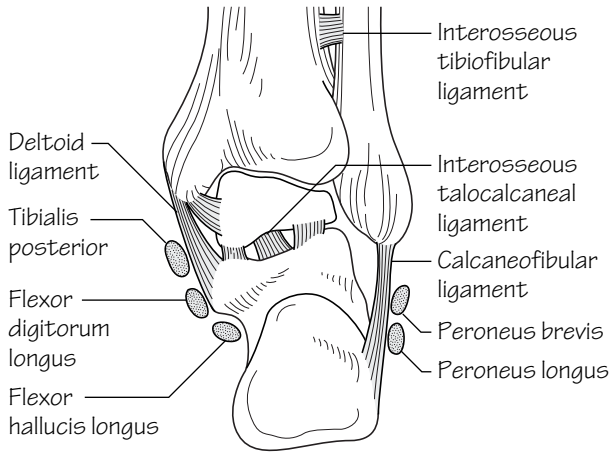
The flexor muscles of the calf are considered in two groups—superficial and deep flexor groups. All flexor muscles of the calf receive their nerve and arterial supplies from the tibial nerve and the posterior tibial artery, respectively.

The contents of the flexor compartment of the calf include:

- **Superficial flexor muscle group:** *gastrocnemius*, *soleus* and *plantaris* (the last is rudimentary in humans). Note that all of these muscles are inserted into the middle third of the posterior surface of the calcaneus via the *tendocalcaneus* (*Achilles tendon*). A small bursa (the *retrocalcaneal bursa*) occupies the space between the upper third of the posterior surface of the calcaneus and the Achilles tendon. Within soleus, and to a lesser extent gastrocnemius, there is an extensive venous plexus. These muscles act as a muscle pump squeezing venous blood upwards during their contraction. It is in these veins that deep venous thromboses readily occur post surgery in the immobile patient.
- **Deep flexor muscle group:** *tibialis posterior*, *flexor digitorum longus*, *flexor hallucis longus* (see Muscle index, p. 166).
- **Artery:** *posterior tibial artery* (p. 95).
- **Nerve:** *tibial nerve* (p. 101).



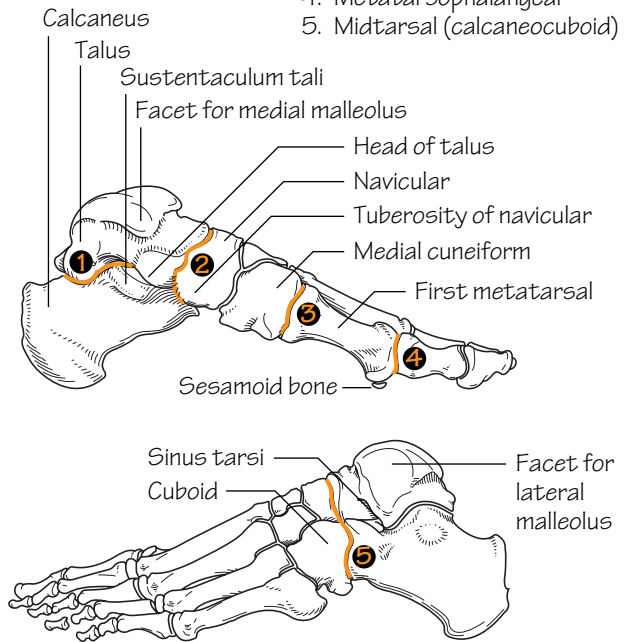
# 50 The ankle and foot I



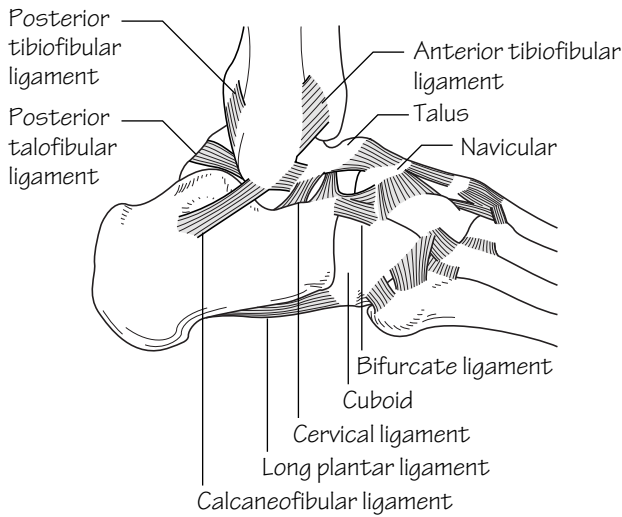
**Fig.50.1**  
The ankle joint from behind, to show how the talus is held in position by ligaments between the tibia and fibula above and the calcaneus below

### Joints

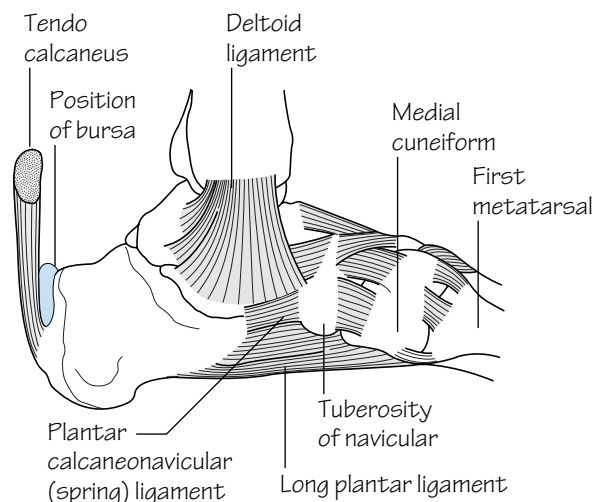
1. Subtalar joint
2. Midtarsal (talonavicular)
3. Tarsometatarsal
4. Metatarsophalangeal
5. Midtarsal (calcaneocuboid)



**Fig.50.2**  
The bones of the foot, medial and lateral aspects. The major joints are shown



**Fig.50.3**  
The ankle joint, lateral aspect after removal of the capsular ligament



**Fig.50.4**  
The ankle joint, medial aspect

## The ankle joint (Fig. 50.1)

- **Type:** the ankle is a *synovial hinge joint* involving the tibia, fibula and talus. The articular surfaces are covered with cartilage and synovial membrane lines the rest of the joint.
- **Capsule:** the capsule encloses the articular surfaces. The capsule is reinforced on either side by strong *collateral ligaments* but is lax anteriorly to permit uninhibited hinged movement.
- **Ligaments:** the *medial collateral (deltoid) ligament* consists of a deep component which is a vertical band passing from the medial malleolus to the talus. The superficial component of this ligament is fan shaped and extends from the medial malleolus to (from front to back): the tuberosity of the navicular, the spring ligament (see below), the sustentaculum tali and the posterior tubercle of the talus (Figs 50.1 and 50.4).

The *lateral collateral ligament* consists of three bands: the anterior and posterior talofibular ligaments and the calcaneofibular ligament (Fig. 50.3). *Abduction/adduction forces on the ankle can cause a sprain—an incomplete tear of one of the collateral ligaments. Complete tears of the ligaments also occur and lead to painful instability at the ankle joint on clinical examination. Severe forces on the ankle joint can result in fracture or fracture dislocation.*

## The movements at the ankle

It is important to note that the inversion and eversion movements of the foot do not occur at the ankle joint except in full plantarflexion. These occur at the *subtalar* and *midtarsal* joints (see below). Only dorsiflexion (extension) and plantarflexion (flexion) occur at the ankle. The principal muscles are:

- **Dorsiflexion:** *tibialis anterior* and to a lesser extent *extensor hallucis longus* and *extensor digitorum longus*.
- **Plantarflexion:** *gastrocnemius* and *soleus* and to a lesser extent *tibialis posterior*, *flexor hallucis longus* and *flexor digitorum longus*.

## The foot bones (Fig. 50.2)

With the exception of the metatarsals and phalanges the foot bones are termed collectively the *tarsal bones*.

- **Talus:** has a body with facets on the superior, medial and lateral surfaces for articulation with the tibia, medial malleolus and lateral malleolus, respectively. There is a groove on the posterior surface of the body for the tendon of flexor hallucis longus. To the groove's lateral side is the posterior (lateral) tubercle, sometimes known as the *os trigonum*, as it ossifies from a separate centre to the talus. A head projects distally which articulates with the navicular. The head is connected to the body by a neck.
- **Calcaneus:** has two facets on the superior surface which participate in the *subtalar* (talocalcaneal and talocalcaneonavicular) joint. The

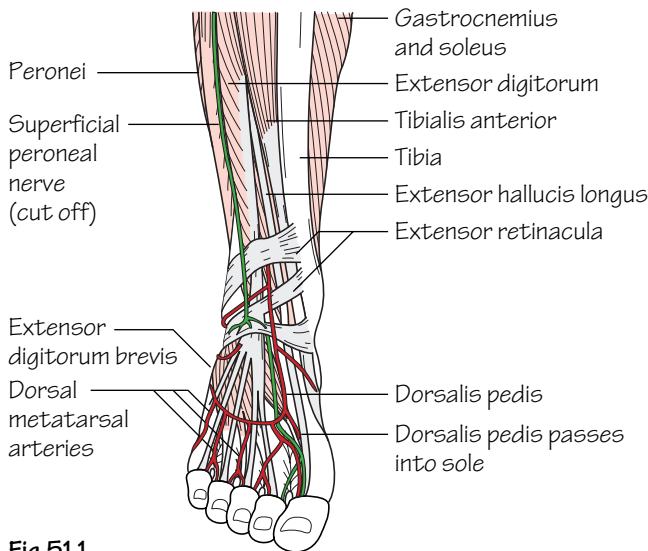
posterior surface has three areas: a roughened middle part where the tendocalcaneus inserts; a smooth upper part which is separated from the tendocalcaneus by a bursa (retrocalcaneal bursa) (Fig. 50.4); and a lower part which is covered by a fibro-fatty pad that forms the heel. Medial and lateral tubercles are present on the inferior surface to which the plantar aponeurosis is attached. The sustentaculum tali is a distinctive projection on the medial surface which forms a shelf for the support of the talus. The *peroneal tubercle*, a small projection on the lateral surface of the calcaneus, separates the tendons of peroneus longus and brevis. The anterior surface has a facet for articulation with the cuboid.

- **Cuboid:** has a grooved undersurface for the tendon of peroneus longus.
- **Navicular:** has facets for the articulations with the head of the talus posteriorly and the three cuneiforms anteriorly. It has a tuberosity on its medial aspect which provides attachment for tibialis posterior.
- **Cuneiforms:** there are three cuneiforms which articulate anteriorly with the metatarsals and posteriorly with the navicular. Their wedge-shape helps to maintain the *transverse arch* of the foot.
- **Metatarsals and phalanges:** these are similar to the metacarpals and phalanges of the hand. Note the articulations of the heads of the metatarsals. The 1st metatarsal is large and is important for balance. The head is grooved on its inferior surface for the two sesamoid bones within the tendon of flexor hallucis brevis.

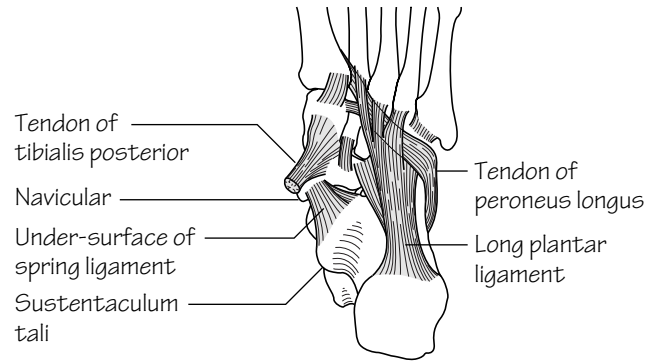
## The foot joints

- **Subtalar joint** (Fig. 50.2): this compound joint comprises the *talocalcaneal* and the *talocalcaneonavicular* joints. Inversion and eversion movements occur at the subtalar joint.
  - The *talocalcaneal joint*—is a synovial plane joint formed by the articulation of the upper surface of the calcaneus with the lower surface of the talus.
  - The *talocalcaneonavicular joint*—is a synovial ball and socket joint between the head of the talus and the sustentaculum tali, the spring ligament and the navicular.
- **Midtarsal joint** (Fig. 50.2): is also a compound joint which contributes towards foot inversion/eversion movements. This joint is composed of the *calcaneocuboid* joint and the *talonavicular* component of the *talocalcaneonavicular* joint.
  - The *calcaneocuboid joint*—is a synovial plane joint formed between the anterior surface of the calcaneus and the posterior surface of the cuboid.
- **Other foot joints** (Fig. 50.2): these include other tarsal joints, tarsometatarsal (synovial plane), intermetatarsal (synovial plane), metatarsophalangeal (synovial condyloid) and interphalangeal (synovial hinge) joints.

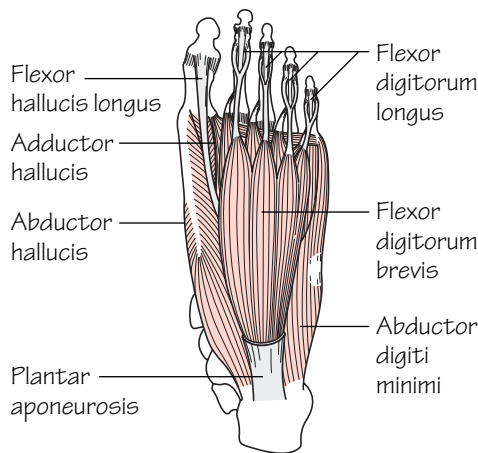
# 51 The ankle and foot II



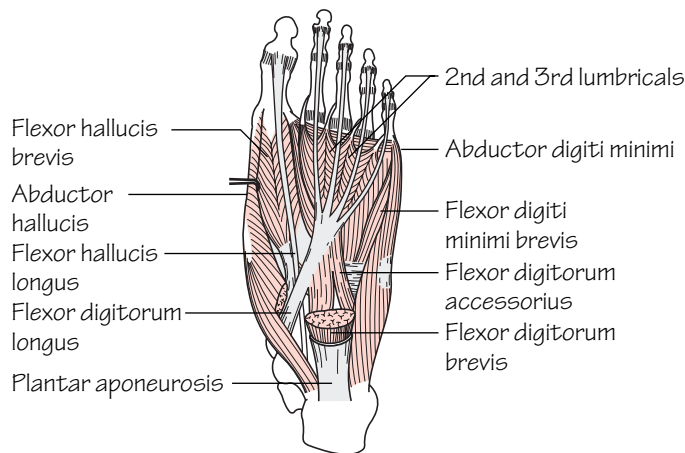
**Fig.51.1**  
The structures on the front of the ankle and the dorsum of the foot



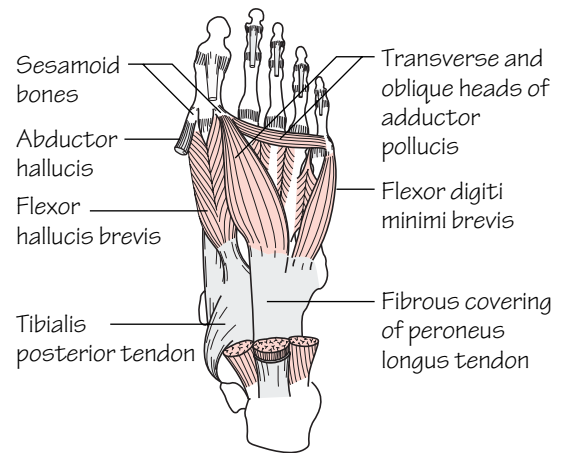
**Fig.51.2**  
The deep ligaments of the sole of the foot



**Fig.51.3**  
The first layer of muscles in the sole of the foot



**Fig.51.4**  
The second layer of muscles in the sole of the foot



**Fig.51.5**  
The third layer of muscles in the sole of the foot

## Ligaments of the foot

- **Spring (plantar calcaneonavicular) ligament** (Fig. 51.2): runs from the sustentaculum tali to the tuberosity of the navicular forming a support for the head of the talus.
- **Bifurcate ligament:** is Y shaped and runs from the anterior part of the calcaneus to the cuboid and navicular bones. It reinforces the capsule of the talocalcaneonavicular joint.
- **Long plantar ligament** (Figs 51.2 and 50.3): runs from the undersurface of the calcaneus to the cuboid and bases of the lateral metatarsals. The ligament runs over the tendon of peroneus longus.
- **Short plantar ligament:** runs from the undersurface of the calcaneus to the cuboid.
- **Medial and lateral (talocalcaneal) ligaments:** strengthen the capsule of the talocalcaneal joint.
- **Interosseous talocalcaneal ligament:** runs in the sinus tarsi, a tunnel formed by deep sulci on the talus and calcaneus.
- **Deep transverse metatarsal ligaments:** join the plantar ligaments of the metatarsophalangeal joints of the five toes.

## The arches of the foot

The integrity of the foot is maintained by two *longitudinal* (medial and lateral) arches and a single *transverse* arch. The arches are held together by a combination of bony, ligamentous and muscular factors so that standing weight is taken on the posterior part of the calcaneum and the metatarsal heads as a result of the integrity of the arches.

- **Medial longitudinal arch** (see Fig. 50.2): comprises calcaneus, talus (the apex of the arch), navicular, the three cuneiforms and three medial metatarsals. The arch is bound together by the spring ligament, muscles and supported from above by tibialis anterior and posterior.
- **Lateral longitudinal arch** (see Fig. 50.2): comprises calcaneus, cuboid and the two lateral metatarsals. The arch is bound together by the long and short plantar ligaments and supported from above by peroneus longus and brevis.
- **Transverse arch:** comprises the cuneiforms and bases of the metatarsals. The arch is bound together by the deep transverse ligament, plantar ligaments and the interossei. It is supported from above by peroneus longus and brevis.

## The dorsum of the foot (Fig. 51.1)

The skin of the dorsum of the foot is supplied by cutaneous branches of the superficial peroneal, deep peroneal, saphenous and sural nerves. The dorsal venous arch lies within the subcutaneous tissue overlying the metatarsal heads. It receives blood from most of the superficial tissues of the foot via digital and communicating branches. The great saphenous vein commences from the medial end of the arch and the small saphenous vein from the lateral end.

## Structures on the dorsum of the foot (Fig. 51.1)

- **Muscles:** extensor digitorum brevis arises from the calcaneus. Other muscles insert on the dorsum of the foot but arise from the leg. These include: tibialis anterior, extensor hallucis longus, extensor digitorum longus, peroneus tertius and peroneus brevis. Each tendon of extensor digitorum longus is joined on its lateral side by a tendon from extensor digitorum brevis. The tendons of extensor digitorum longus and peroneus tertius share a common synovial sheath whilst the other tendons have individual sheaths.
- **Arterial supply:** is from the dorsalis pedis artery—the continuation of the anterior tibial artery. The dorsalis pedis ends by passing to the sole where it completes the plantar arch (p. 95).
- **Nerve supply:** is from the deep peroneal nerve via its medial and lateral terminal branches. The latter supplies extensor digitorum brevis whereas the former receives cutaneous branches from the skin.

## The sole of the foot

The sole is described as consisting of an aponeurosis and four muscle layers. The skin of the sole is supplied by the medial and lateral plantar branches of the tibial nerve. The medial calcaneal branch of the tibial nerve innervates a small area on the medial aspect of the heel.

### The plantar aponeurosis

This aponeurosis lies deep to the superficial fascia of the sole and covers the 1st layer of muscles. It is attached to the calcaneus behind and sends a deep slip to each toe as well as blending superficially with the skin creases at the base of the toes. The slips that are sent to each toe split into two parts which pass on either side of the flexor tendons and fuse with the *deep transverse metatarsal ligaments*.

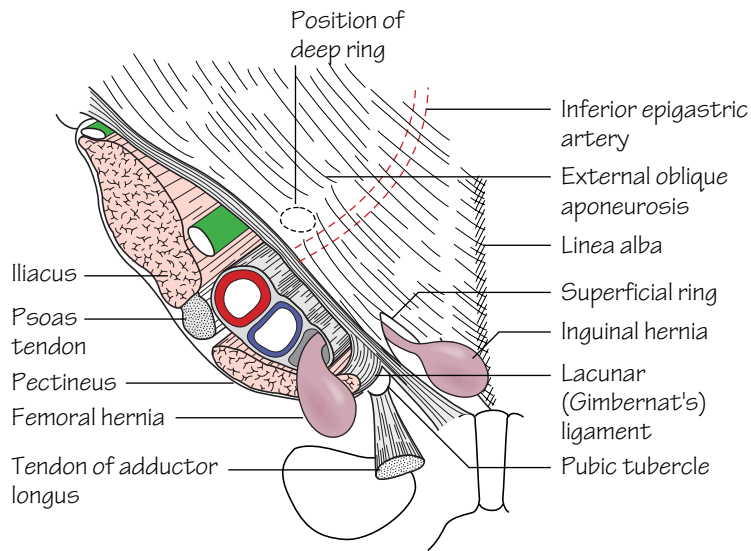
### The muscular layers of the sole

- **1st layer consists of:** abductor hallucis, flexor digitorum brevis and abductor digiti minimi (Fig. 51.3).
- **2nd layer consists of:** flexor digitorum accessorius, the lumbricals and the tendons of flexor digitorum longus and flexor hallucis longus (Fig. 51.4).
- **3rd layer consists of:** flexor hallucis brevis, adductor hallucis and flexor digiti minimi brevis (Fig. 51.5).
- **4th layer consists of:** the dorsal and plantar interossei and the tendons of peroneus longus and tibialis posterior.

### Neurovascular structures of the sole

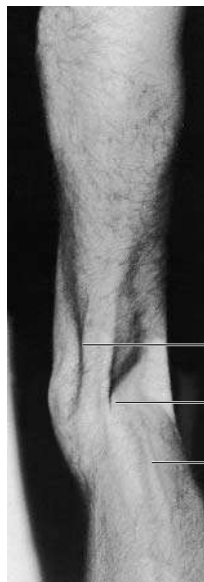- **Arterial supply:** is from the posterior tibial artery which divides into *medial* and *lateral plantar* branches. The latter branch contributes the major part of the *deep plantar arch* (p. 95).
- **Nerve supply:** is from the tibial nerve which also divides into *medial* and *lateral plantar* branches (p. 101).

## 52 Surface anatomy of the lower limb



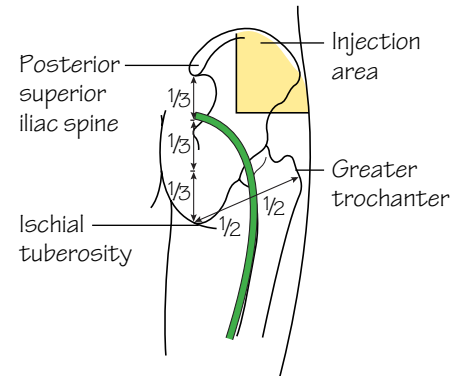
**Fig.52.1**

The anatomy of femoral and inguinal herniae. Note the relation of the deep inguinal ring to the inferior epigastric artery and the relation of the two types of hernia to the pubic tubercle



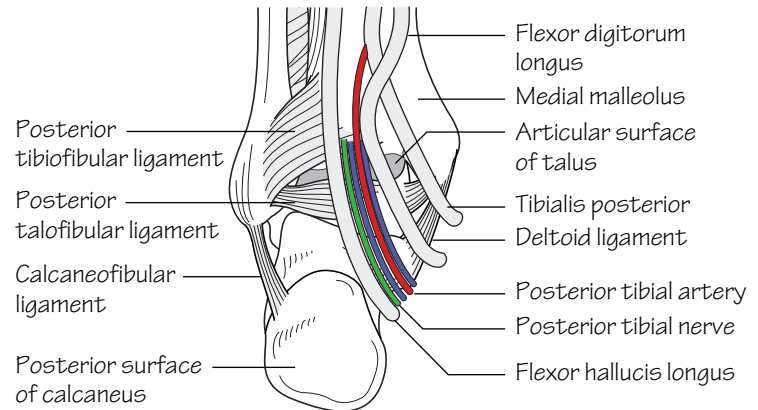
**Fig.52.4**

Visible structures on the medial side of the lower limb



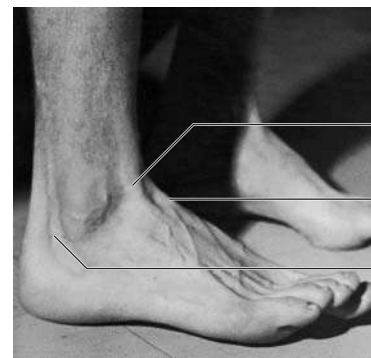
**Fig.52.2**

The surface markings of the sciatic nerve



**Fig.52.3**

The structures on the medial side of the ankle



**Fig.52.5**

The lateral aspect of the foot to show the tendons that can be recognised



## Surface landmarks around the hip and gluteal region

- **The anterior superior iliac spine** is a prominent landmark at the anterior end of the iliac crest.
- **The greater trochanter** of the femur lies approximately a handsbreadth below the iliac crest. It is made more prominent by adducting the hip.
- **The ischial tuberosity** is covered by gluteus maximus when the hip is extended. It can be palpated in the lower part of the buttock with the hip flexed.
- **The femoral pulse** (Fig. 52.1) is most easily felt halfway between the anterior superior iliac spine and the symphysis pubis (mid-inguinal point). The femoral head lies deep to the femoral artery at the mid-inguinal point. The femoral vein lies medial, and the femoral nerve lateral, to the artery at this point.
- **The femoral canal** (Fig. 52.1) lies medial to the femoral vein within the femoral sheath. The sac of a femoral hernia passes through the canal to expand below the deep fascia. The hernial sac always lies below and lateral to the pubic tubercle (cf. the neck of an inguinal hernia which is always situated above and medial to the tubercle). The risk of strangulation is high in femoral herniae as the femoral canal is narrow and blood flow to viscera within the hernial sac can easily be impaired.
- **The great saphenous vein** pierces the cribriform fascia in the saphenous opening of the deep fascia to drain into the femoral vein 4 cm below and lateral to the pubic tubercle (Fig. 43.2).
- In thin subjects the *horizontal chain of superficial inguinal lymph nodes* is palpable. It lies below and parallel to the inguinal ligament.
- **The sciatic nerve** has a curved course throughout the gluteal region. Consider two lines—one connects the posterior superior iliac spine and the ischial tuberosity and the other connects the greater trochanter and the ischial tuberosity (Fig. 52.2). The nerve descends the thigh in the midline posteriorly. The division of the sciatic nerve into tibial and common peroneal components occurs usually at a point a handsbreadth above the popliteal crease but is highly variable. *Sciatic nerve damage is occasionally caused by badly placed intramuscular injections. The safest site for intramuscular injection is consequently the upper outer quadrant of the buttock.*
- **The common peroneal nerve** winds superficially around the neck of the fibula. In thin subjects it can be palpated at this point. Footdrop can result from fibular neck fractures where damage to this nerve has occurred.

## Surface landmarks around the knee

- **The patella and ligamentum patellae** are easily palpable with the limb extended and relaxed. The ligamentum patellae can be traced to its attachment at the *tibial tuberosity*.
- **The adductor tubercle** can be felt on the medial aspect of the femur above the medial condyle.
- **The femoral and tibial condyles** are prominent landmarks. With the knee in flexion the joint line, and outer edges of the *menisci* within, are palpable. The *medial* and *lateral collateral ligaments* are palpable on either side of the knee and can be followed to their bony attachments.

- **The subcutaneous border of the tibia** is palpable throughout its length.
- **The fibular head** is palpable laterally (Fig. 52.4). The shaft of the fibula is mostly covered but is subcutaneous for the terminal 10 cm.
- **The popliteal pulse** is difficult to feel as it lies deep to the tibial nerve and popliteal vein. It is best felt by palpating in the popliteal fossa with the patient prone and the knee flexed.

## Surface landmarks around the ankle

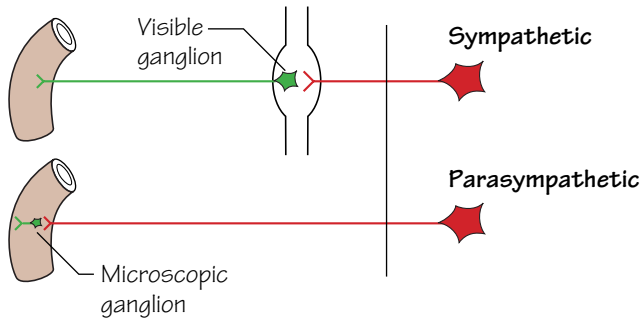
- The medial and lateral malleoli are prominent at the ankle. The lateral is more elongated and descends a little further than the medial.
- When the foot is dorsiflexed the tendons of *tibialis anterior*, *extensor hallucis longus* and *extensor digitorum* are visible on the anterior aspect of the ankle and the dorsum of the foot.
- The tendons of *peroneus longus* and *brevis* pass behind the lateral malleolus.
- Passing behind the medial malleolus lie: the tendons of *tibialis posterior* and *flexor digitorum longus*, the *posterior tibial artery* and its *venae comitantes*, the *tibial nerve* and *flexor hallucis longus* (Fig. 52.3).

## Surface landmarks around the foot (Fig. 52.5)

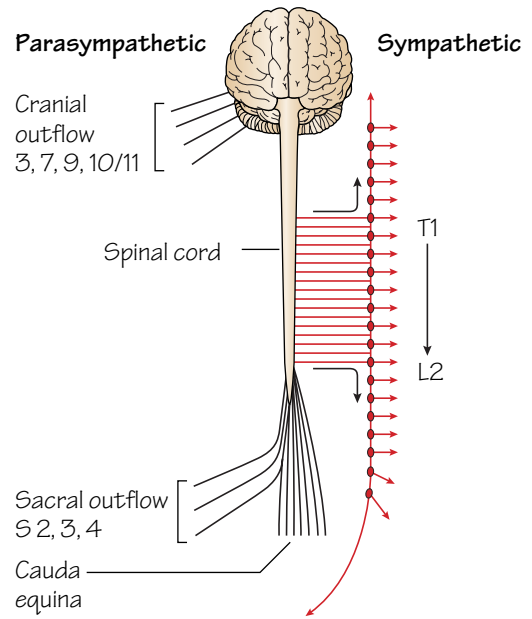
- **The head of the talus** is palpable immediately anterior to the distal tibia.
- **The base of the 5th metatarsal** is palpable on the lateral border of the foot. The tendon of peroneus brevis inserts onto the tuberosity on the base.
- **The heel** is formed by the calcaneus. The *tendocalcaneus* (*Achilles*) is palpable above the heel. Sudden stretch of this can lead to rupture. When this occurs a gap in the tendon is often palpable.
- **The tuberosity of the navicular** can be palpated 2.5 cm anterior to the medial malleolus. It receives most of the tendon of tibialis posterior.
- **The peroneal tubercle** of the calcaneum can be felt 2.5 cm below the tip of the lateral malleolus.
- **The sustentaculum tali** can be felt 2.5 cm below the medial malleolus. The tendon of tibialis posterior lies above the sustentaculum tali and the tendon of flexor hallucis longus winds beneath it.
- **The dorsalis pedis pulse** is located on the dorsum of the foot between the tendons of extensor hallucis longus and extensor digitorum.
- **The posterior tibial pulse** is best felt halfway between the medial malleolus and the heel.
- **The dorsal venous arch** is visible on the dorsum of the foot. The small saphenous vein drains the lateral end of the arch and passes posterior to the lateral malleolus to ascend the calf and drain into the popliteal vein. The great saphenous vein passes anterior to the medial malleolus to ascend the length of the lower limb and drain into the femoral vein. *This vein can be accessed consistently by 'cutting down' anterior to, and above, the medial malleolus following local anaesthesia. This is used in emergency situations when intravenous access is difficult but required urgently.*



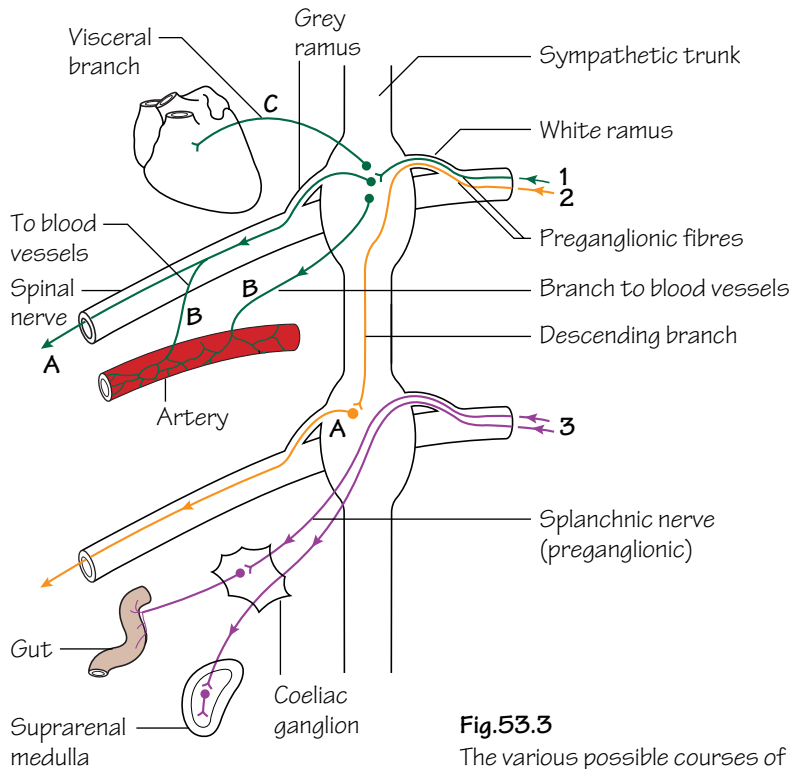
# 53 The autonomic nervous system



**Fig.53.1**  
The different lengths of the pre- and postganglionic fibres of the autonomic nervous system.  
Preganglionic fibres: red  
Postganglionic fibres: green



**Fig.53.2**  
The sympathetic (right) and parasympathetic (left) outflows



**Fig.53.3**  
The various possible courses of the preganglionic fibres (1, 2 & 3) and postganglionic fibres (A, B and C) of the sympathetic nervous system

The autonomic nervous system comprises two parts—the *sympathetic* and the *parasympathetic*. The former initiates the ‘fight or flight’ reaction while the latter controls the body under more relaxed conditions. Both systems have synapses in peripheral ganglia but those of the sympathetic system are, for the most part, close to the spinal cord in the ganglia of the *sympathetic trunk* whereas those of the parasympathetic system are mostly in the walls of the viscera themselves and are microscopic (except for the four macroscopic ganglia in the head and neck described below). Thus the sympathetic preganglionic fibres are relatively short compared to the parasympathetic fibres (Fig. 53.1).

- **Sympathetic outflow** (Fig. 53.2): the anterior rami of spinal nerves T1 to L2 or 3. The fibres leave these spinal nerves as the *white rami communicantes* and synapse in the ganglia of the sympathetic trunk.
- **Parasympathetic outflow:** this comprises:
  - *Cranial outflow*—fibres travel as ‘passengers’ in the cranial nerves 3, 7, 9 and 10/11 and synapse in one of the four macroscopic peripheral ganglia of the head and neck.
  - *Sacral outflow*—travel in sacral nerves S2, 3 and 4.

### The sympathetic system

- **The sympathetic trunk:** from the base of the skull to the tip of the coccyx where the two trunks join to form the *ganglion impar*. The trunk continues upwards into the carotid canal as the *internal carotid nerve*.
- **Superior cervical ganglion:** represents the fused ganglia of C1, 2, 3 and 4.
- **Middle cervical ganglion:** represents the fused ganglia of C5 and 6.
- **Inferior cervical ganglion:** represents the fused ganglia of C7 and 8. It may be fused with the ganglion of T1 to form the *stellate ganglion*. For courses of the pre- and postganglionic fibres see Fig. 53.3.
- **Preganglionic fibres:** when the white (myelinated) rami reach the sympathetic trunk they may follow one of three different routes:
  - 1 They may synapse with a nerve cell in the corresponding ganglion.
  - 2 They may pass straight through the corresponding ganglion and travel up or down the sympathetic trunk, to synapse in another ganglion.
  - 3 They may pass straight through their own ganglion, maintaining their preganglionic status until they synapse in one of the outlying ganglia such as the coeliac ganglion. *One exceptional group of fibres even pass through the coeliac ganglion and do not synapse until they reach the suprarenal medulla.*
- **Postganglionic fibres:** after synapsing, the postganglionic fibres may follow one of three different routes:

- A They may pass back to the spinal nerve as a grey (unmyelinated) ramus and are then distributed with the branches of that nerve.
- B They may pass to adjacent arteries to form a plexus around them and are then distributed with the branches of the arteries. Other fibres leave branches of the spinal nerves later to pass to the arteries more distally.
- C They may pass directly to the viscera in distinct and sometimes named branches such as the *cervical cardiac branches* of the cervical ganglia.

If the sympathetic trunk is divided above T1 or below L2, the head and neck or the lower limb will lose all sympathetic supply.

*Loss of the supply to the head and neck will produce Horner’s syndrome. There will be loss of sweating (anhidrosis), drooping of the upper eyelid (ptosis) and constriction of the pupil (myosis) on that side.*

Details of the sympathetic system in the various regions are given in the appropriate chapters, but Table 53.1 summarizes the autonomic supply to the most important regions and viscera.

### The parasympathetic system

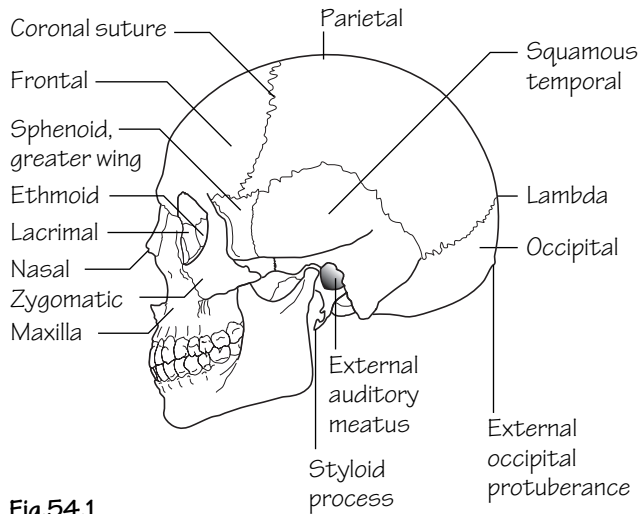
- **The cranial outflow:**
  - III The *oculomotor nerve* carries parasympathetic fibres to the *constrictor pupillae* and the *ciliary muscle*, synapsing in the ciliary ganglion.
  - VII The *facial nerve* carries fibres for the *submandibular* and *sublingual* glands (which synapse in the *submandibular ganglion*) and for the *lacrimal gland* (which synapse in the *sphenopalatine ganglion*).
  - IX The *glossopharyngeal nerve* carries fibres for the *parotid gland* which synapse in the *otic ganglion*.
  - X/XI The *vagus and cranial root of the accessory* carry fibres for the thoracic and abdominal viscera down as far as the proximal two-thirds of the transverse colon, where supply is taken over by the sacral outflow. Synapses occur in minute ganglia in the cardiac and pulmonary plexuses and in the walls of the viscera.
- **The sacral outflow:**

From the sacral nerves S2, 3 and 4, fibres join the inferior *hypogastric plexuses* by means of the *pelvic splanchnic nerves*. They go on to supply the pelvic viscera, synapsing in minute ganglia in the walls of the viscera themselves. Some fibres climb out of the pelvis around the inferior mesenteric artery and supply the sigmoid and descending colon and the distal one third of the transverse colon.

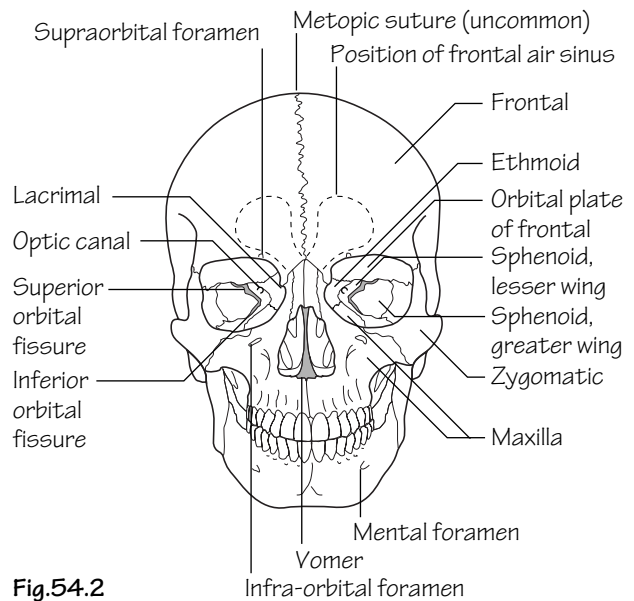
**Table 53.1** The autonomic system.

| Region                       | Origin of connector fibres | Site of synapse  |
|------------------------------|----------------------------|--|
| <i>Sympathetic</i>           |                            |  |
| Head and neck                | T1–T5                      | Cervical ganglia   |
| Upper limb                   | T2–T6                      | Inferior cervical and 1st thoracic ganglia                         |
| Lower limb                   | T10–L2                     | Lumbar and sacral ganglia  |
| Heart                        | T1–T5                      | Cervical and upper thoracic ganglia                                |
| Lungs                        | T2–T4                      | Upper thoracic ganglia   |
| Abdominal and pelvic viscera | T6–L2                      | Coeliac and subsidiary ganglia                                     |
| <i>Parasympathetic</i>       |                            |  |
| Head and neck                | Cranial nerves 3, 7, 9, 10 | Various parasympathetic macroscopic ganglia                        |
| Heart                        | Cranial nerve 10           | Ganglia in vicinity of heart                                       |
| Lungs                        | Cranial nerve 10           | Ganglia in hila of lungs   |
| Abdominal and pelvic viscera | Cranial nerve 10           | Microscopic ganglia in walls of viscera (down to transverse colon) |
|                              | S2, 3, 4                   | Microscopic ganglia in walls of viscera                            |

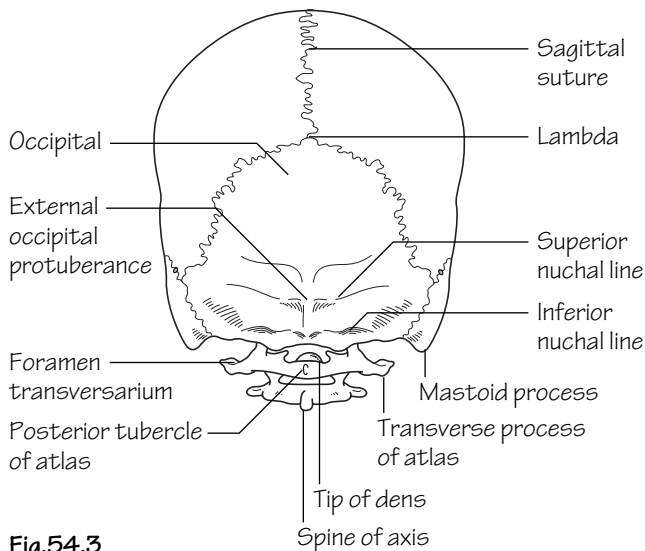
## 54 The skull I



**Fig. 54.1**  
Skull, side view



**Fig. 54.2**  
Skull, anterior view



**Fig. 54.3**  
Skull, posterior view

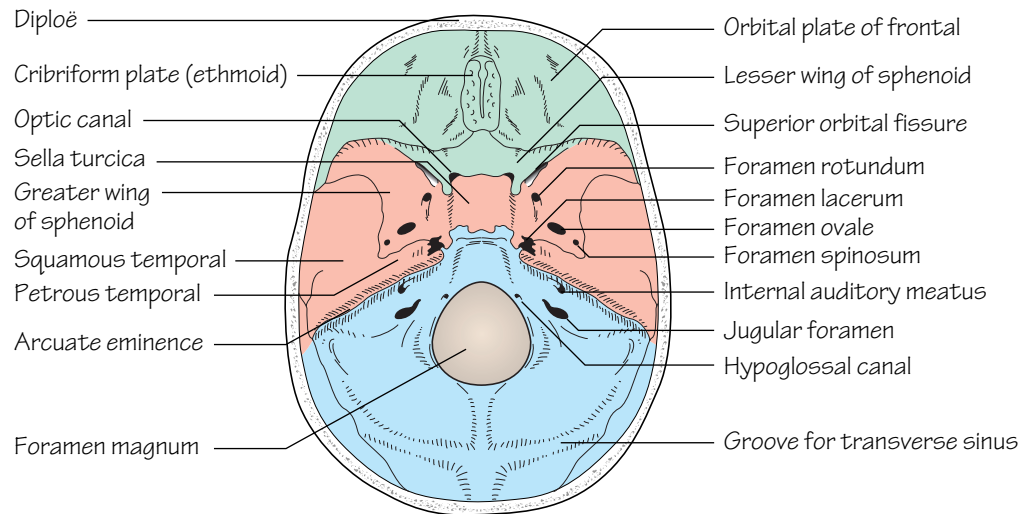
The skull consists of the bones of the *cranium* (making up the *vault* and the *base*) and the bones of the *face*, including the mandible.

### The bones of the cranium

#### The vault of the skull

- The vault of the skull comprises a number of flat bones, each of which consists of two layers of compact bone separated by a layer of

cancellous bone (the *diploë*) which contains red bone marrow and a number of *diploic veins*. The bones are the *frontal*, *parietal*, *occipital*, *squamous temporal* and the *greater wing of the sphenoid*. The *frontal air sinuses* are in the frontal bone just above the orbit. The bones are separated by *sutures* which hold the bones firmly together in the mature skull (Figs 54.1–3). Occasionally the frontal bone may be separated into two halves by a midline *metopic suture*.



**Fig.54.4**

The interior of the skull base.

The anterior, middle and posterior cranial fossae are coloured green, red and blue respectively

- There are a number of *emissary foramina* which transmit *emissary veins*. These establish a communication between the intra- and extra-cranial veins.

*On an X-ray of the skull there are markings which may be mistaken for a fracture. These are caused by (1) the middle meningeal artery, (2) diploic veins, or (3) the sutures, including the infrequent metopic suture.*

### The interior of the base of the skull

The interior of the base of the skull comprises the *anterior, middle* and *posterior cranial fossae* (Fig. 54.4).

#### The anterior cranial fossa

- **Bones:**
  - Orbital plate of the frontal bone
  - Lesser wing of the sphenoid
  - Cribriform plate of the ethmoid
- **Foramina:**
  - In the cribriform plate (Olfactory nerves)
  - Optic canal (Optic nerve and ophthalmic artery)
- **Other features:**
  - The orbital plate of the frontal forms the roof of the orbit.
  - Lateral to the optic canals are the *anterior clinoid processes*.
  - The boundary between the anterior and middle cranial fossae is the sharp posterior edge of the lesser wing of the sphenoid.

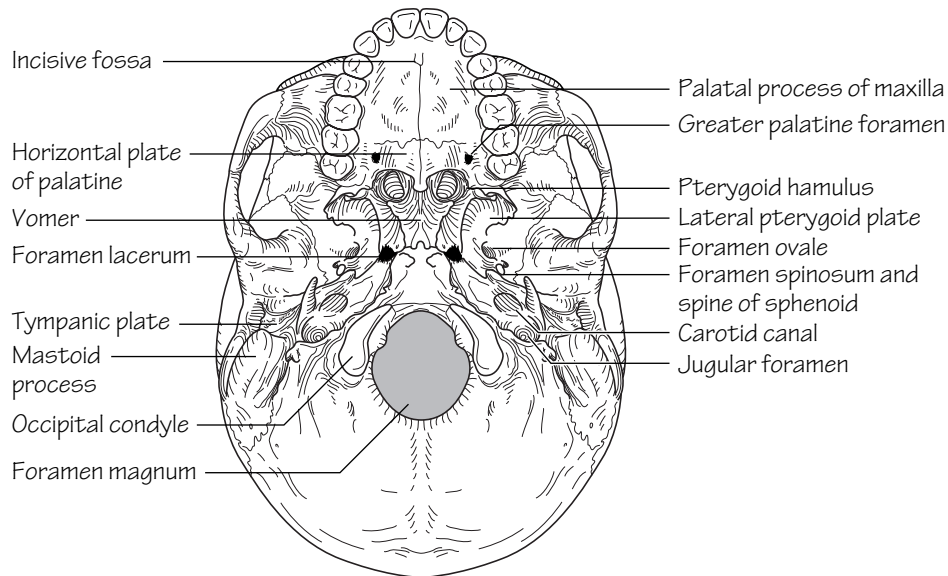
#### The middle cranial fossa

- **Bones:**
  - Greater wing of the sphenoid
  - Temporal bone
- **Foramina:**
  - Superior orbital fissure (Frontal, lacrimal and nasociliary branches of trigeminal nerve; oculomotor, trochlear and abducent nerves; ophthalmic veins)

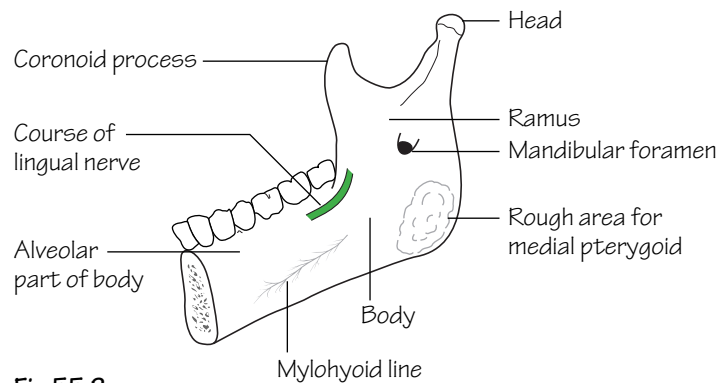
- Foramen rotundum (Maxillary branch of trigeminal nerve)
- Foramen ovale (Mandibular branch of trigeminal nerve)
- Foramen spinosum (Middle meningeal artery)
- Foramen lacerum (Internal carotid artery through upper opening (p. 133))
- **Other features:**
  - The superior orbital fissure is between the greater and lesser wings of the sphenoid.
  - In the midline is the *body of the sphenoid* with the *sella turcica* on its upper aspect. It contains the *sphenoidal air sinus*.
  - The foramen lacerum is the gap between the apex of the petrous temporal and the body of the sphenoid.
  - The boundary between the middle and posterior cranial fossae is the sharp upper border of the petrous temporal bone.

#### The posterior cranial fossa

- **Bones:**
  - Petrous temporal (posterior surface)
  - Occipital
- **Foramina:**
  - Foramen magnum (lower part of medulla, vertebral arteries, spinal accessory nerve)
  - Internal auditory meatus (facial and vestibulocochlear nerves, internal auditory artery)
  - Jugular foramen (glossopharyngeal, vagus and accessory nerves, internal jugular vein)
  - Hypoglossal canal (hypoglossal nerve)
- **Other features:**
  - The jugular foramen is the gap between the occipital and petrous temporal bones.
  - The inner surface of the occipital is marked by deep grooves for the transverse and sigmoid venous sinuses. They lead down to the jugular foramen.



**Fig.55.1**  
The base of the skull from below



**Fig.55.2**  
The internal surface of the mandible

**The outside of the base of the skull** (Fig. 55.1)

The anterior part of the cranial base is hidden by the bones of the face (p. 125). The remainder consists of the bones that were seen in the middle and posterior cranial fossae but many of the foramina seen on the exterior are not visible inside the cranium.

- *Bones:*
  - Temporal (Squamous, petrous and tympanic parts and the styloid process)
  - Sphenoid (body) which carries the medial and lateral pterygoid plates
- *Foramina:*
  - Foramen magnum (already described)
  - Hypoglossal canal (already described)
  - Stylomastoid foramen (facial nerve)
  - Jugular foramen (already described)
  - Foramen lacerum (the internal carotid through its internal opening)

- Carotid canal (internal carotid artery and sympathetic nerves)
- Foramen spinosum (already described)
- Foramen ovale (already described)
- *Other features:*
  - The area between and below the nuchal lines is for the attachment of the extensor muscles of the neck.
  - The *occipital condyles*, for articulation with the atlas, lie on either side of the foramen magnum.
  - The *mastoid process* is part of the petrous temporal and contains the *mastoid air cells* (p. 157).
  - The floor of the *external auditory meatus* is formed by the *tympanic plate of the temporal bone*.
  - The carotid canal (see Fig. 59.2) turns inside the temporal bone to run horizontally forwards. It then opens into the posterior wall of the foramen lacerum before turning upwards again to enter the cranial cavity through the internal opening of the foramen.

- Behind the foramen spinosum is the spine of the sphenoid which lies medial to the mandibular fossa for articulation with the head of the mandible.
- In front of this is the articular eminence, onto which the head of the mandible moves when the mouth is open.

### The bones of the face (Figs 54.2 and 55.2)

The bones of the face are suspended below the front of the cranium and comprise the bones of the upper jaw, the bones around the orbit and nasal cavities and the mandible.

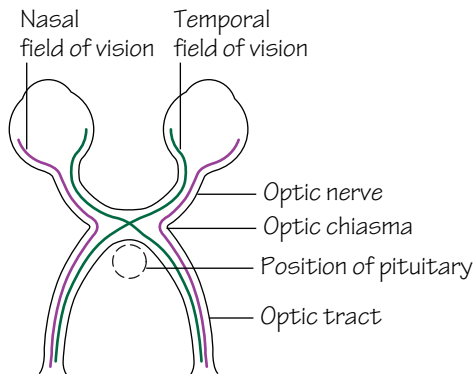
- *Bones:*
  - Maxilla
  - Pterygoid plates of the sphenoid
  - Palatine
  - Zygomatic
  - Nasal
  - Frontal
  - Lacrimal
  - Bones of the orbit and nasal cavities (see below)
- *Foramina:*
  - Supraorbital (Supraorbital nerve)
  - Infraorbital (Infraorbital nerve)
  - Mental (Mental nerve)
  - Greater and lesser palatine foramina (Greater and lesser palatine nerves)

- Foramina of the incisive fossa (Nasopalatine nerves and vessels)
- *Other features:*
  - The pterygoid plates of the sphenoid support the back of the maxilla.
  - Between these two bones is the *pterygomaxillary fissure* which leads into the *pterygopalatine fossa*.
  - The hard palate is formed by the *palatine process of the maxilla* and the *horizontal plate of the palatine*.
  - The teeth are borne in the maxilla.
  - The maxilla contains the large *maxillary air sinus*.
  - The bones of the orbit: the orbital margins are formed by the frontal, zygomatic and maxillary bones.
  - The ethmoid lies between the two orbits and contains the ethmoidal air cells.
  - The lacrimal has a fossa for the lacrimal sac.
  - At the back of the orbit are the greater and lesser wings of the sphenoid with the superior orbital fissure between them. Also the optic canal and the infraorbital fissure.
  - The bones of the nasal cavity are the maxilla, the inferior concha, the ethmoid, the vomer, the nasal septum and the perpendicular plate of the palatine.

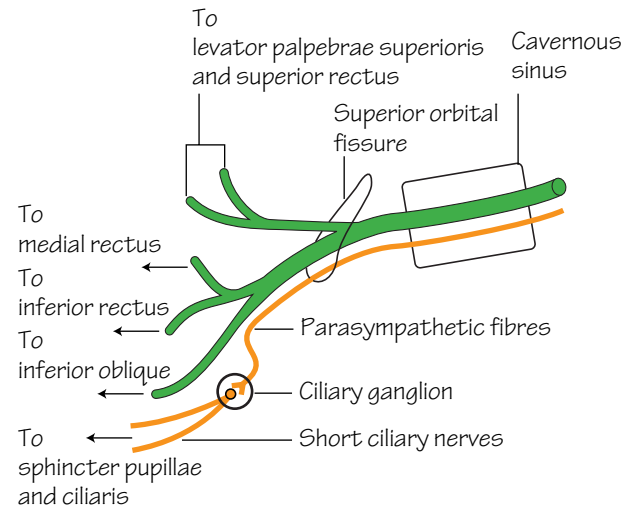
The **mandible** (Fig. 55.2) consists of the body and two rami. Each ramus divides into a coronoid process and the head, for articulation with the mandibular fossa. The mandibular foramen transmits the inferior alveolar nerve and vessels.



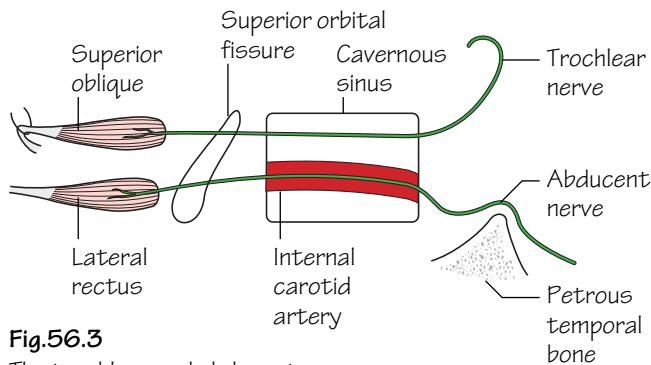
## 56 Spinal nerves and cranial nerves I–IV



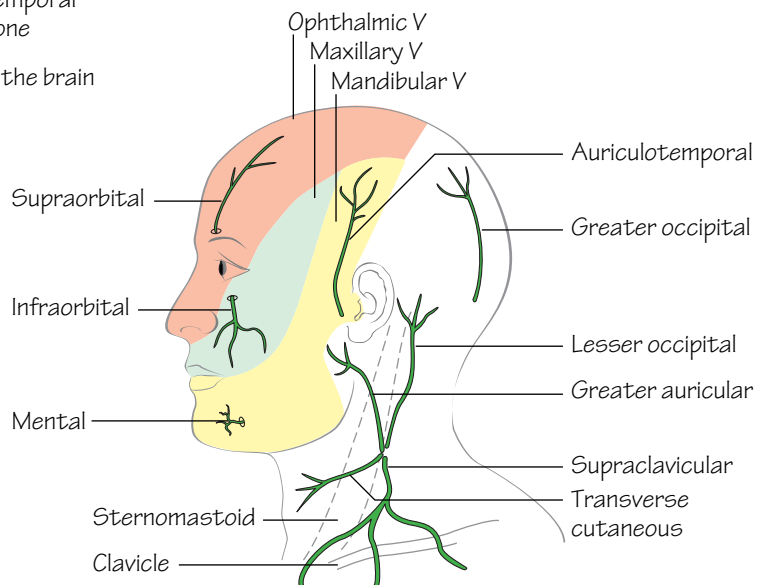
**Fig.56.1**  
The optic chiasma.  
Only the fibres from the nasal side of the retina (i.e., the temporal fields of vision) cross in the chiasma



**Fig.56.2**  
The oculomotor nerve.  
Parasympathetic fibres are shown in orange



**Fig.56.3**  
The trochlear and abducent nerves.  
The trochlear nerve arises from the dorsal surface of the brain



**Fig.56.4**  
The main sensory nerves of the face and neck

The head and neck are supplied by the first four spinal and the 12 cranial nerves.

### The spinal nerves

- **C1:** supplies the small suboccipital muscles. Its anterior ramus joins the hypoglossal nerve but leaves it later to form the *descendens hypoglossi*.
- **C2:** The posterior ramus forms the *greater occipital nerve* which is sensory to the scalp.
- **The posterior rami of C2, 3 and 4** provide muscular and sensory branches to the back. Their anterior rami provide muscular branches, including the *descendens cervicalis* (see hypoglossal nerve). They also supply sensory branches: the *greater auricular*, *lesser occipital*, *anterior cutaneous* and the *three supraclavicular nerves* (Fig. 56.4). The greater auricular supplies the skin in the parotid region, the only sensory supply to the face which is not derived from the trigeminal. The others supply the skin of the neck and the upper part of the thorax.
- **The remaining cervical nerves (C5–8)** join the brachial plexus.

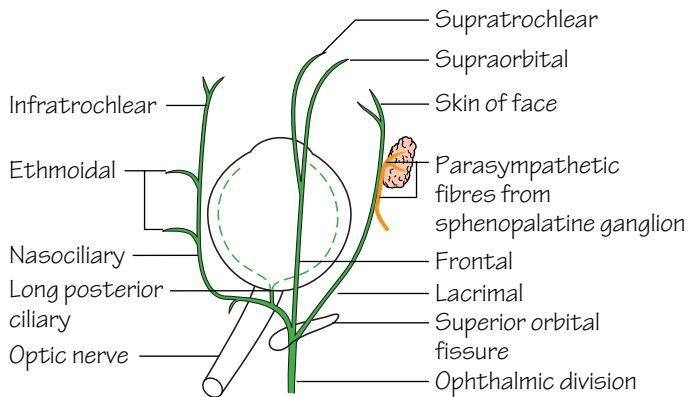
### The cranial nerves (Figs 56.1–3)

- **I. The olfactory nerve:** the cell bodies of the olfactory nerve are in

the nasal mucosa. Their axons form the olfactory nerves which ascend through the cribriform plate to synapse in the olfactory bulb of the brain.

- **II. The optic nerve** (Fig. 56.1): the eye and optic nerve develop as an outgrowth of the embryonic brain and the nerve is therefore enveloped in meninges. The cell bodies are in the retina and the axons pass back in the optic nerve to the *optic chiasma* where the axons from the nasal halves of the retina cross over but those from the temporal side continue on the same side. They then form the *optic tract* on each side.
- **III. The oculomotor nerve** (Fig. 56.2): arises from the brain just in front of the pons, traverses the cavernous sinus and enters the orbit through the *superior orbital fissure*. Supplies the levator palpebrae superioris, superior, inferior and medial rectus muscles and the inferior oblique. It also carries parasympathetic fibres to the *ciliary ganglion* where the fibres synapse and then pass in the short ciliary nerves to the sphincter pupillae and the ciliary muscles (see Chapter 69).
- **IV. The trochlear nerve** (Fig. 56.3): arises from the dorsal surface of the brain just behind the *inferior colliculus*, winds round the mid-brain and enters the *cavernous sinus*. It enters the orbit through the *superior orbital fissure* and supplies the superior oblique.

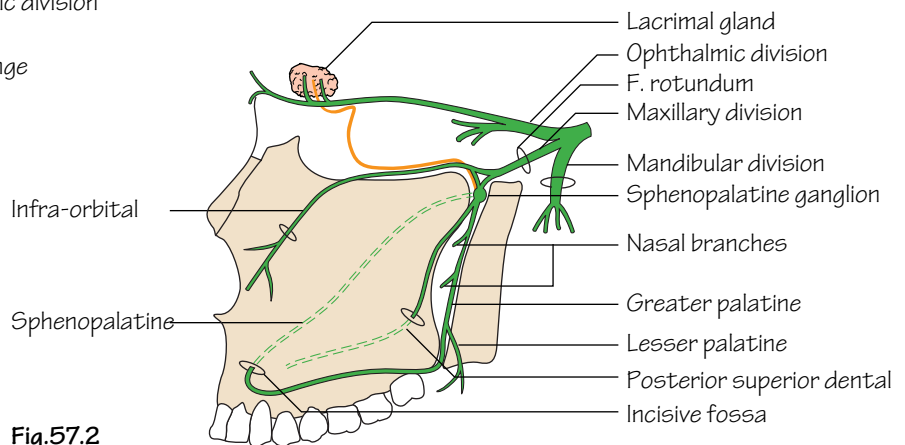
## 57 The trigeminal nerve (V)



**Fig.57.1**

The course and branches of the ophthalmic division of the trigeminal nerve.

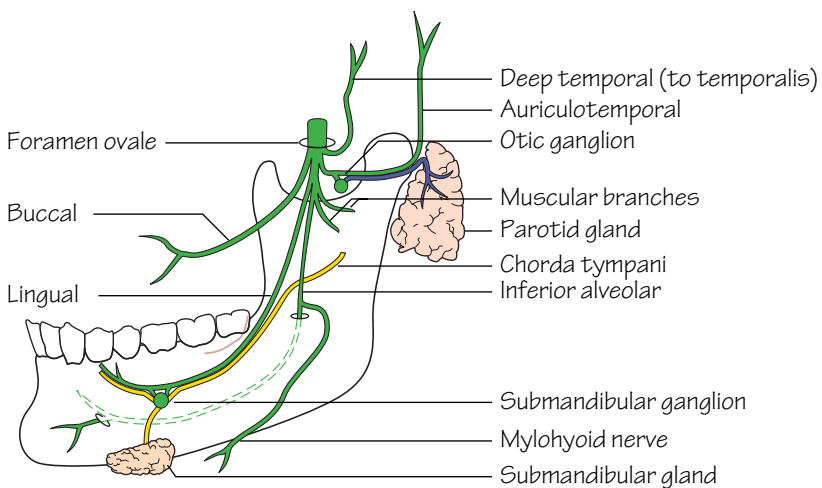
Parasympathetic fibres are shown in orange



**Fig.57.2**

The course and branches of the maxillary division of the trigeminal nerve.

Parasympathetic fibres are shown in orange



**Fig.57.3**

The course and main branches of the mandibular division of the trigeminal nerve.

The fibres of the chorda tympani are shown in yellow

The trigeminal nerve (Figs 56.4 and 57.1–3) arises from the brain at the side of the pons by a motor and a sensory root. The sensory root carries the *trigeminal ganglion* which consists of the cell bodies of the sensory axons and lies in a depression on the petrous temporal bone. It then divides into *ophthalmic*, *maxillary* and *mandibular* divisions. The motor root forms part of the mandibular division.

**(a) The ophthalmic division** (Fig. 57.1)

This traverses the cavernous sinus and enters the orbit via the *superior orbital fissure* where it divides into *frontal*, *lacrimal* and *nasociliary* branches. The *frontal nerve* lies just under the roof of the orbit and divides into *supraorbital* and *supratrochlear nerves* which emerge from the orbit and supply the front of the scalp. The *lacrimal nerve* lies laterally and supplies the skin of the eyelids and face. It also carries parasympathetic secretomotor fibres from the *sphenopalatine ganglion* to the *lacrimal gland*. The *nasociliary nerve* crosses the optic nerve and runs along the medial wall of the orbit to emerge onto the face as the *infratrochlear nerve*. It gives off the *ethmoidal nerves* to the ethmoidal sinuses and the *long ciliary nerves* to the eye which carry sensory fibres from the cornea and sympathetic fibres to the dilator pupillae. *All branches of the ophthalmic division are sensory.*

**(b) The maxillary division** (Fig. 57.2)

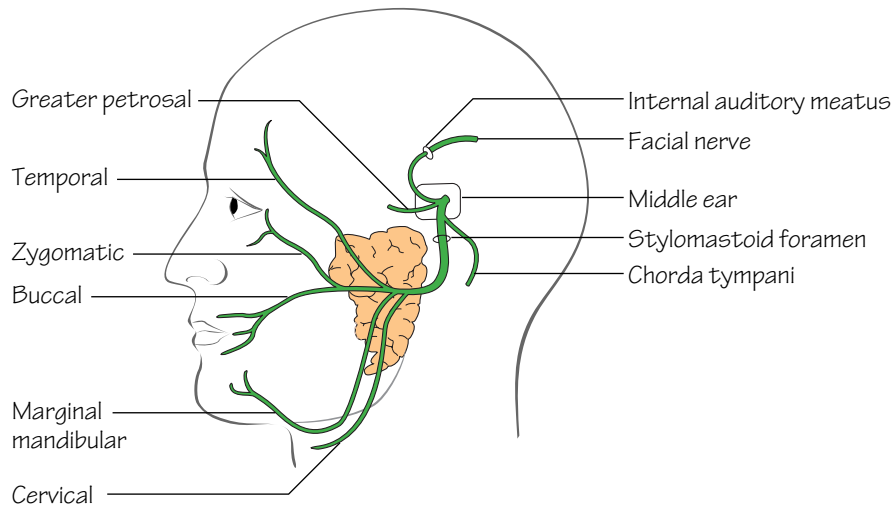
This leaves the cranial cavity through the foramen rotundum and enters the *pterygopalatine fossa*. It has the *sphenopalatine ganglion* attached to it which transmits parasympathetic fibres to the lacrimal gland via communications with the lacrimal nerve. The branches of the maxillary nerve are the *greater* and *lesser palatine nerves* to the hard and soft

palates, the *sphenopalatine nerve* to the nasal cavity and thence via the nasal septum, to the incisive fossa to supply the hard palate. The *posterior superior dental nerve* enters the back of the maxilla and supplies the teeth. The maxillary nerve leaves the sphenopalatine fossa via the inferior orbital fissure, travels in the floor of the orbit where it gives the *middle* and *anterior superior dental nerves*, and emerges onto the face through the infraorbital foramen as the *infraorbital nerve*. *All branches of the maxillary division are sensory.*

**(c) The mandibular division** (Fig. 57.3)

This leaves the cranial cavity through the foramen ovale and immediately breaks up into branches. These are: the mainly sensory *inferior alveolar nerve*, which enters the mandibular foramen to supply the teeth before emerging onto the face as the *mental nerve*. This nerve does have one motor branch, the *mylohyoid nerve*, which supplies the mylohyoid and the anterior belly of the digastric. The *lingual nerve* lies close to the mandible just behind the third molar and then passes forwards to supply the tongue. It is joined by the *chorda tympani* which carries taste fibres from the anterior two-thirds of the tongue and parasympathetic secretomotor fibres to the submandibular and sublingual salivary glands. These synapse in the submandibular ganglion which is attached to the lingual nerve. The *auriculotemporal nerve* supplies sensory fibres to the side of the scalp. It also carries parasympathetic secretomotor fibres, which have synapsed in the otic ganglion, to the parotid gland. The *buccal nerve* carries sensory fibres from the face. There are *muscular branches* to the muscles of mastication, including the *deep temporal nerves* which supply temporalis. *The mandibular division thus contains both motor and sensory branches.*

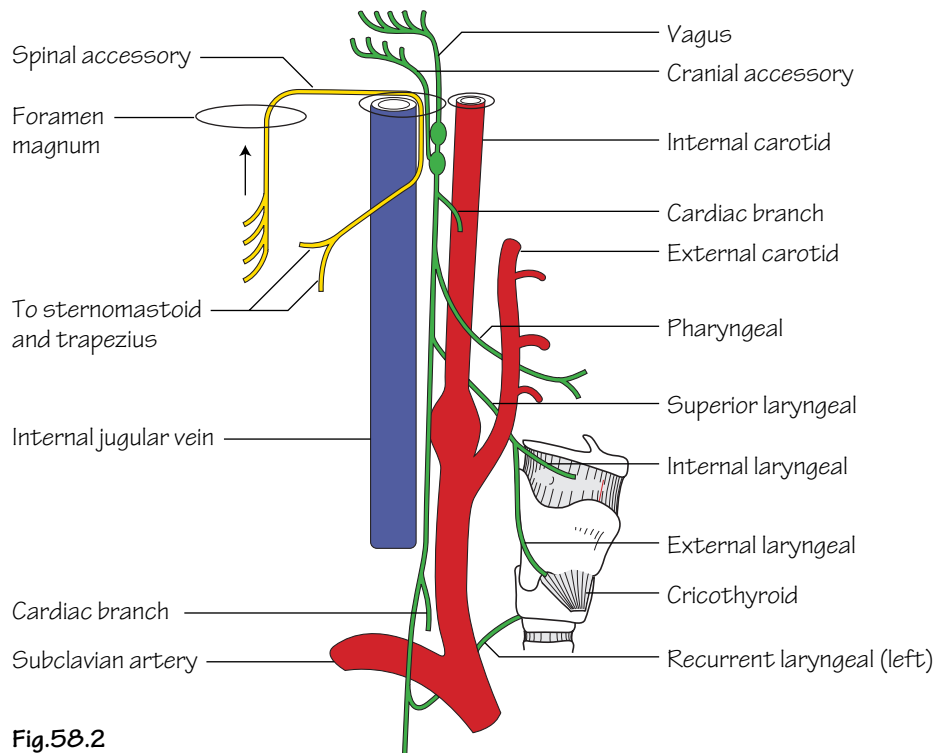
## 58 Cranial nerves VI–XII



**Fig.58.1**

The course of the facial nerve.

The nerve passes through the middle ear and the parotid gland



**Fig.58.2**

The vagus and accessory nerves.

The spinal root of the accessory is shown in yellow

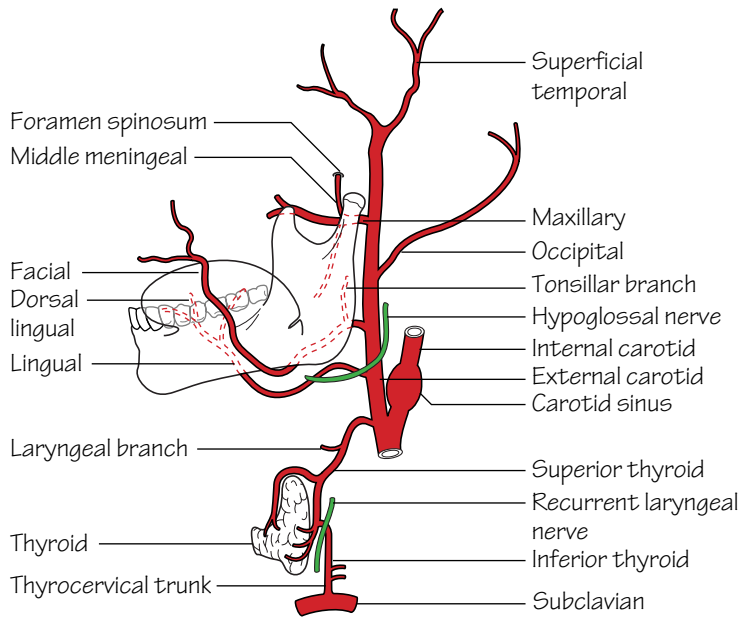
- **VI. The abducent nerve** (see Fig. 56.3): leaves the brain at the posterior border of the pons and has a long intracranial course (*so is often the first nerve to be affected in raised intracranial pressure*) to the cavernous sinus, where it is closely applied to the internal carotid artery, and thence to the orbit via the superior orbital fissure. It supplies the lateral rectus.
- **VII. The facial nerve** (Fig. 58.1): this leaves the brain near the cerebellum and passes laterally into the internal auditory meatus. It reaches the medial wall of the middle ear and turns backwards and downwards to leave the skull via the stylomastoid foramen. It then traverses the parotid gland, in which it divides into five branches (*temporal, zygomatic, buccal, marginal mandibular and cervical*) which are distributed to the muscles of facial expression, the platysma and the posterior belly of the digastric. In the middle ear it gives off the *greater petrosal branch* which carries parasympathetic fibres to the sphenopalatine ganglion and thence to the lacrimal gland. In the middle ear it also gives off the *chorda tympani* which joins the lingual nerve and is distributed with it. Sensory fibres in the chorda tympani have their cell bodies in the *geniculate ganglion* which lies on the facial nerve where it turns downwards.
- **VIII. The vestibulocochlear (auditory) nerve**: this leaves the brain next to the facial nerve and enters the internal auditory meatus. It divides into *vestibular* and *cochlear* nerves.
- **IX. The glossopharyngeal nerve** (see Fig. 65.1): leaves the brain at the side of the medulla and passes through the jugular foramen. It then curves forwards between the internal and external carotid arteries to enter the pharynx between the superior and middle constrictors. It supplies sensory fibres to the posterior one third of the tongue (including taste) and the pharynx. It also gives a branch to the carotid body and sinus.
- **X. The vagus nerve** (Fig. 58.2): arises from the side of the medulla and passes through the jugular foramen. It is joined by the accessory nerve but the spinal root of the accessory leaves it again almost immediately. The cranial root is distributed with the vagus (hence the name—it is accessory to the vagus). The vagus carries two ganglia for the cell bodies of its sensory fibres. It descends between the internal carotid artery and the jugular vein, within the carotid sheath, and enters

the thorax where its further course is described in Chapters 2 and 3. In the neck the vagus (and cranial root of the accessory) gives the following branches:

- The *pharyngeal branch* which runs below and parallel to the glossopharyngeal nerve and supplies the striated muscle of the palate and pharynx.
- *Superior and inferior cardiac branches* which descend into the thorax to take part in the cardiac plexuses.
- The *superior laryngeal nerve* which divides into *internal* and *external laryngeal nerves*. The former enters the larynx by piercing the thyrohyoid membrane and is sensory to the larynx above the level of the vocal cords, and the latter is motor to the cricothyroid muscle.
- The *recurrent laryngeal nerve*. On the right side it loops under the subclavian artery before ascending to the larynx behind the common carotid artery. On the left side it arises from the vagus just below the arch of the aorta and ascends to the larynx in the groove between the trachea and oesophagus. The recurrent laryngeal nerves supply all the muscles of the larynx except for cricopharyngeus and are sensory to the larynx below the vocal cords.
- **XI. The accessory nerve** (Fig. 58.2): the *cranial root* arises from the side of the medulla with the vagus and is distributed with it. The *spinal root* arises from the side of the upper five segments of the spinal cord, enters the cranial cavity through the foramen magnum and joins the vagus. It leaves the vagus below the jugular foramen and passes backwards to enter sternomastoid, which it supplies. It then crosses the posterior triangle to supply trapezius (see Fig. 61.3).
- **XII. The hypoglossal nerve** (Figs 59.1 and 65.1): arises from the side of the medulla ventral to the vagus and cranial accessory and passes through the hypoglossal canal. Below the skull it is joined by the anterior ramus of C1 and it then runs downwards and forward, across the carotid sheath and the upward loop of the lingual artery to enter the tongue. It supplies the intrinsic and extrinsic muscles of the tongue. It gives off the *descendens hypoglossi* but this is actually composed of fibres from C1. This joins the *descendens cervicalis*, derived from C2 and 3, to form the *ansa cervicalis*. From this, branches arise to supply the '*strap muscles*', i.e. sternothyroid, sternohyoid, thyrohyoid and omohyoid.

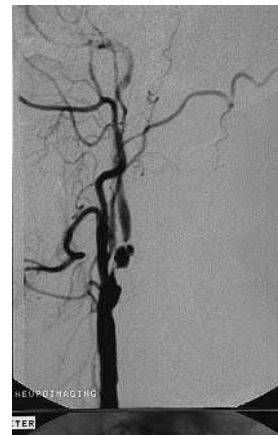

# 59 The arteries I



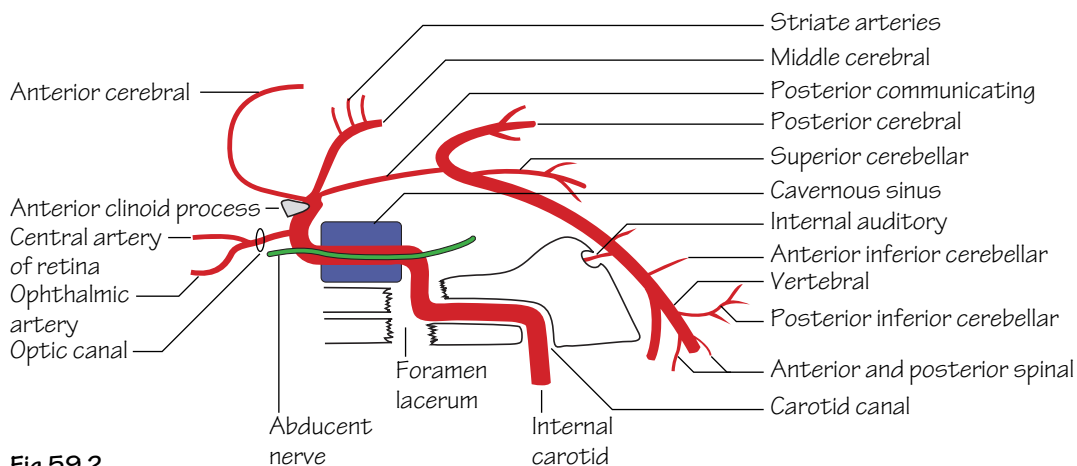
**Fig.59.1**

The course and main branches of the external carotid artery. The inferior thyroid artery is also shown



**Fig.59.3**

Carotid angiogram showing internal carotid stenosis



**Fig.59.2**

The intracranial course of the internal carotid artery. The intracranial parts of the two vertebral arteries are also shown diagrammatically although they are in a different plane

## The common carotid artery

Arises from the brachiocephalic artery on the right and from the arch of the aorta on the left (Chapter 4). Each common carotid passes up the neck in the carotid sheath (Fig. 61.1), along with the internal jugular vein and the vagus nerve. At the level of the upper border of the thyroid cartilage it divides into internal and external carotid arteries. There are no branches.

## The external carotid artery (Fig. 59.1)

Ascends in the neck a little in front of the internal carotid to divide into its two terminal branches, the *maxillary* and *superficial temporal arteries*, in the substance of the parotid gland.

### Branches:

- **The superior thyroid artery:** runs downwards on the side of the pharynx before passing forwards to the upper pole of the thyroid gland where it divides into two branches. The upper branch follows the upper border of the gland towards the isthmus and the lower passes down the posterior border to anastomose with the inferior thyroid artery. There are a number of branches to the larynx.
- **The lingual artery:** arises at the level of the tip of the greater horn of the hyoid and loops upwards for a short distance before running forward deep to hyoglossus to enter and supply the tongue. It gives a number of *dorsal lingual arteries*. The upward loop of the lingual is crossed by the hypoglossal nerve.
- **The facial artery:** travels forwards, deep to the mandible where it is embedded in the back of the submandibular gland. It then curls round the lower border of the mandible to reach the face. Here it follows a tortuous course at the side of the mouth and lateral to the nose to reach the medial angle of the eye where it anastomoses with branches of the ophthalmic artery. It gives off a *tonsillar branch* in the neck, *superior* and *inferior labial branches* and *nasal branches*. The facial arteries anastomose very freely across the midline and with other arteries on the face.
- **The occipital artery:** passes backwards, medial to the mastoid process, and supplies the back of the scalp.
- **The superficial temporal artery:** emerges from the parotid gland and runs up in front of the ear where its pulsations may be felt. It is distributed to the side of the scalp and the forehead.
- **The maxillary artery:** emerges from the parotid gland and passes deep to the neck of the mandible. It ends by entering the pterygopalatine fossa through the pterygomaxillary fissure. Its principal branches are to the local muscles including the *deep temporal arteries* to temporalis and:
  - The *inferior alveolar artery*—enters the mandibular canal to supply the teeth.

- The *middle meningeal artery*—runs upwards to pass through the foramen spinosum. Inside the skull it passes laterally and then ascends on the squamous temporal bone in a deep groove, which it shares with the corresponding vein. The *anterior* branch passes upwards and backwards towards the vertex and the *posterior* branch passes backwards. It supplies the dura mater and the bones of the cranium. *After head injuries it may bleed to produce a subdural haemorrhage, the symptoms of which may be delayed for some time after the injury.*
- *Branches which accompany the branches of the maxillary nerve in the pterygopalatine fossa and have the same names.*

## The internal carotid artery (Figs 59.2 and 59.3)

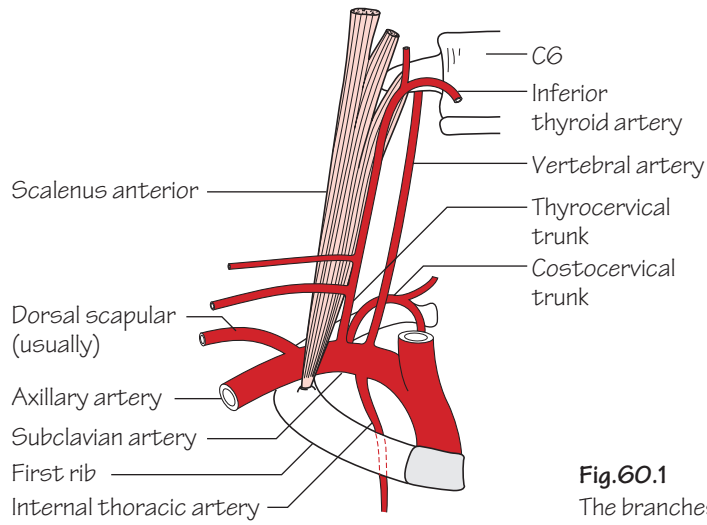
At its origin from the common carotid artery it is enlarged to form the *carotid sinus*, a slight dilatation which has baroreceptors supplied by the glossopharyngeal nerve in its wall. Associated with this is the *carotid body*, a *chemoreceptor* supplied by the same nerve. The internal carotid has no branches in the neck. It enters the cranial cavity via the carotid canal in the petrous temporal bone, accompanied by a sympathetic plexus. Within the skull it passes forwards in the cavernous sinus and then turns backwards behind the anterior clinoid process to break up into its three terminal branches.

### Branches:

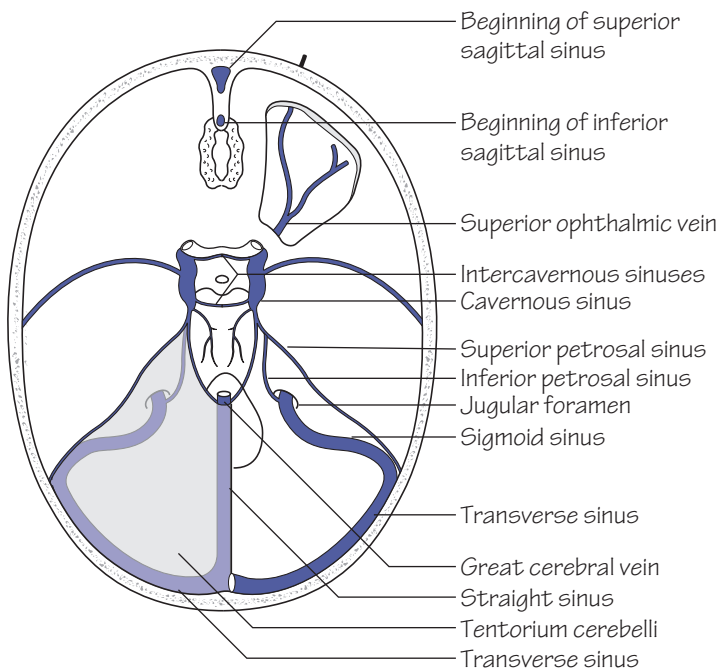
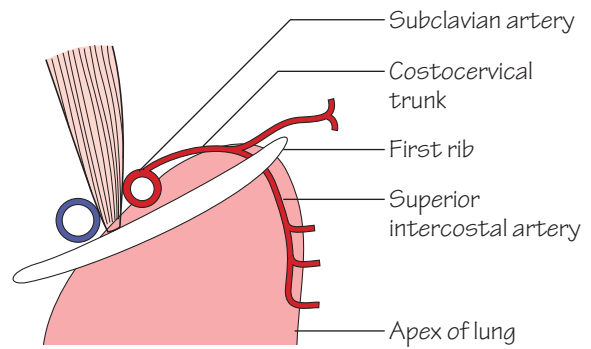
- **The ophthalmic artery:** enters the orbit through the superior orbital fissure and follows the nasociliary nerve. It gives the important *central retinal artery* which enters the optic nerve and supplies the retina. *This is an end-artery so that occlusion causes immediate blindness.* Other branches are described on p. 155.
- **The anterior cerebral artery:** winds round the *genu of the corpus callosum* and supplies the front and medial surfaces of the cerebral hemisphere. It anastomoses with its fellow of the opposite side.
- **The middle cerebral artery:** traverses the *lateral sulcus* on the lateral surface of the hemisphere and supplies the hemisphere (including the main motor and sensory areas) as well as giving the *striate arteries* which supply deep structures including the *internal capsule*.
- **The posterior communicating artery:** a small artery which passes backwards to join the *posterior cerebral artery*, a terminal branch of the vertebral artery.

These arteries and the communications between them form the *Circle of Willis* so that there is (usually) free communication between the branches of the two internal carotid arteries across the midline. There is, however, considerable variation in the arrangement of the circle.

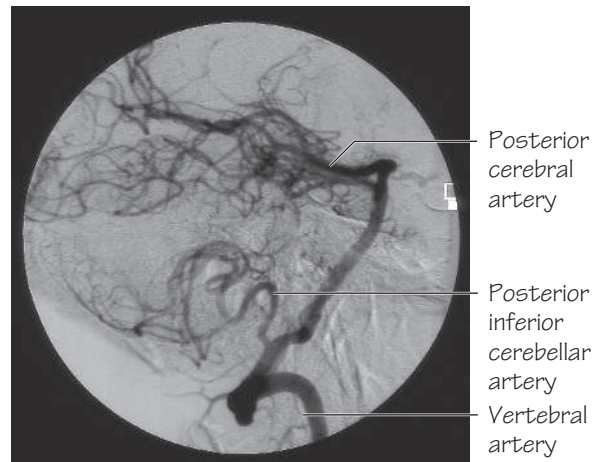
## 60 The arteries II and the veins



**Fig.60.1**  
The branches of the subclavian artery



**Fig.60.2**  
The intracranial venous sinuses



**Fig.60.3**  
Vertebral angiogram

## The subclavian artery (Figs 60.1 and 63.1)

Arises from the *brachiocephalic artery* on the right and the *arch of the aorta* on the left. It arches across the upper surface of the 1st rib to become the *axillary artery*. It is in close contact with the apex of the lung and lies behind scalenus anterior at the root of the neck.

### Branches:

- **The internal thoracic artery:** see p. 13.
- **The vertebral artery:** runs upwards to enter the foramen transversarium of the 6th cervical vertebra. It passes through corresponding foramina in the other cervical vertebra to reach the upper surface of the atlas. Here it turns medially in a groove and then enters the cranial cavity through the *foramen magnum*. Here it joins its fellow of the opposite side to form the *basilar artery*. It gives off the *anterior* and *posterior spinal arteries* which descend to supply the spinal cord, and the *posterior inferior cerebellar artery* which supplies not only the cerebellum but also the medulla. The basilar artery passes forwards on the under-surface of the medulla and pons and gives the *anterior inferior cerebellar artery*, branches to the brainstem and to the inner ear (the *internal auditory artery*) and ends by dividing into the *superior cerebellar* and *posterior cerebellar arteries*. The latter is joined by the *posterior communicating artery* (p. 133).
- **The costocervical trunk:** a small artery that passes backwards to supply muscles of the back. It also supplies the *superior thoracic artery* (see Chapter 3).
- **The thyrocervical trunk:** gives off the *superficial cervical* and *suprascapular arteries* and then passes medially as the *inferior thyroid artery* across the vertebral artery to reach the middle of the posterior border of the thyroid. It has a variable relation to the recurrent laryngeal nerve, lying in front or behind them, but may branch early with the nerve passing between the branches.
- **The dorsal scapular artery:** usually given off from the third part (Fig. 63.1). It descends along the medial border of the scapula but may arise in common with the superficial cervical artery.

## The veins

The veins of the brain drain into *dural venous sinuses* (Fig. 60.2). The most important of these are:

- **The superior sagittal sinus:** passes backwards in the midline in the attached border of the falx cerebri from just above the cribriform plate to the occipital region, where it communicates with the *straight sinus*, and then turns to the right to form the *right transverse sinus*. It then winds down on the back of the petrous temporal as the *sigmoid sinus*

which passes through the right jugular foramen to form the *right internal jugular vein*.

- **The inferior sagittal sinus:** begins near the origin of the superior sagittal sinus and runs in the free border of the falx cerebri. It is joined by the great cerebral vein to form the *straight sinus* which lies in the attachment of the falx to the tentorium cerebelli. The straight sinus turns to the left to form the left transverse sinus and then the sigmoid sinus. The latter leaves the skull through the left jugular foramen.
- **The cavernous sinus:** this lies at the side of the pituitary fossa and contains the internal carotid artery. It receives the superior and inferior ophthalmic veins and is connected to some smaller sinuses—the *superior* and *inferior petrosal sinuses* and the *sphenoidal sinus*. The two cavernous sinuses are joined in front and behind the pituitary by the *intercavernous sinuses*.

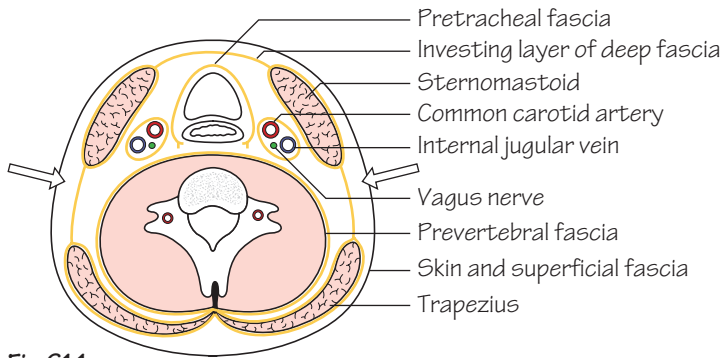
- **The emissary veins:** see p. 123.

- **The internal jugular vein:** passes down the neck from the jugular foramen, in the carotid sheath along with the internal and common carotid arteries and the vagus nerve. It ends by joining the subclavian vein to form the *brachiocephalic vein*. It receives veins corresponding to the branches of the external carotid artery (*facial, lingual, pharyngeal*, and the *superior* and *middle thyroid veins*). The *inferior thyroid veins* pass downwards in front of the trachea to open into the left brachiocephalic vein.

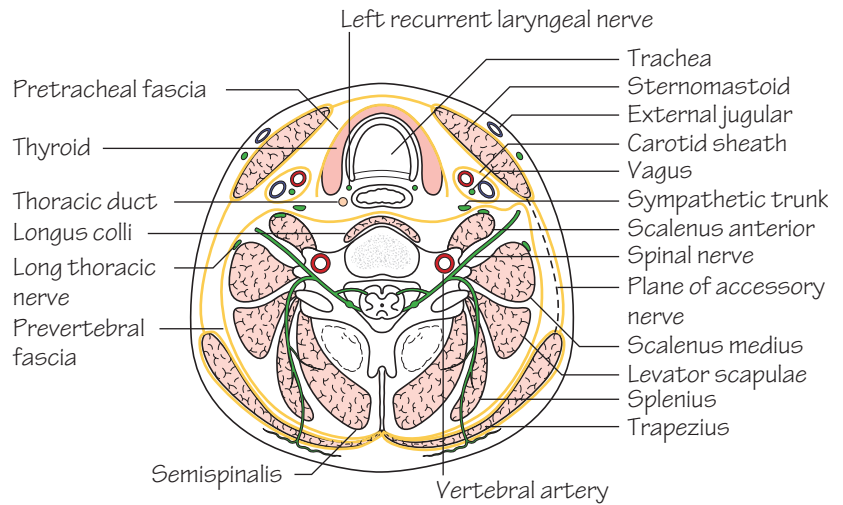
*The facial vein communicates around the orbit with tributaries of the ophthalmic veins so that infections of the face may spread to the cavernous sinus if not properly treated.*

- **The external jugular vein:** begins in the parotid gland by the joining of the *retromandibular vein* with other small veins. It passes obliquely across sternomastoid to open into the subclavian vein. It receives the *transverse cervical, suprascapular* and *anterior jugular veins* near its lower end.
- **The anterior jugular vein:** begins below the chin and runs down the neck near the midline. It then passes deep to sternomastoid to join the external jugular vein.
- **The subclavian vein:** lies in a groove on the 1st rib but is separated from the subclavian artery by the scalenus anterior. It receives the external jugular vein, veins corresponding to the branches of the subclavian artery and, at its junction with the internal jugular vein, the *thoracic duct* on the left and the *right lymph duct* on the right.
- **The vertebral vein:** this is formed at the level of the 6th foramen transversarium from the vertebral plexus of veins that accompany the vertebral artery.

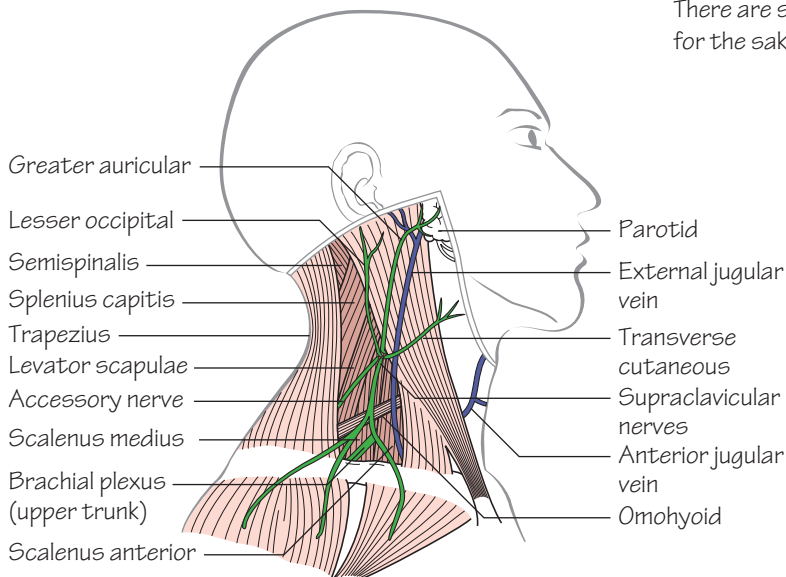
# 61 Anterior and posterior triangles



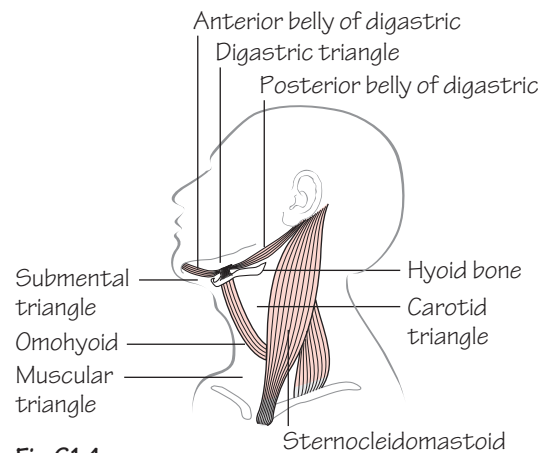
**Fig. 61.1**  
The basic plan of the neck in cross-section.  
The arrows indicate the posterior triangle



**Fig. 61.2**  
A more detailed plan of the neck, based on Fig. 61.1.  
There are still some structures omitted from the diagram for the sake of simplicity, for example the strap muscles



**Fig. 61.3**  
The main structures in the posterior triangle



**Fig. 61.4**  
Subdivisions of the anterior triangle

The neck consists essentially of five blocks of tissue running longitudinally (Figs 61.1 and 61.2). These are as follows:

**1 The cervical vertebrae** surrounded by a number of muscles and enclosed in a dense layer of *prevertebral fascia*.

**2 The pharynx and larynx**, partially enclosed in a thin layer of *pretracheal fascia*. Below the level of C6 these give way to the oesophagus and trachea.

**3 & 4 Two vascular packets** consisting of the common and internal carotid arteries, the internal jugular vein and the vagus nerve, all enclosed in the fascial *carotid sheath*.

**5 An outer enclosing sheath** consisting of the sternomastoid and trapezius and the *investing layer of deep fascia of the neck*.

### The anterior triangle

The *anterior triangle* (Fig. 61.4) is bounded by:

- The lower border of the mandible and its backward continuation.
- The anterior border of sternomastoid.
- The midline of the neck.

The anterior triangle is subdivided into:

- (a) The *digastric triangle*, bounded by:
  - The lower border of the mandible.
  - The two bellies of the digastric.
- (b) The *carotid triangle*, bounded by:
  - The superior belly of the omohyoid.
  - The posterior belly of the digastric.
  - The anterior border of sternomastoid.
- (c) The *muscular triangle*, bounded by:
  - The superior belly of the omohyoid.
  - The anterior border of sternomastoid.
  - The midline of the neck.

The contents of these triangles are mostly structures that are continuous, without interruption, from one triangle to another so that it is more convenient to describe them individually in other chapters.

### The posterior triangle (Fig. 61.3)

The *posterior triangle* is bounded by:

- The posterior border of *sternomastoid*.
- The anterior border of *trapezius*.
- The middle part of the clavicle.

Stretching between the two muscles is the *investing layer of deep fascia* which splits to enclose them and continues to the anterior triangle. Embedded in the deep fascia is the *spinal part of the accessory nerve* which leaves the sternomastoid about halfway down its posterior border and passes into trapezius two fingerbreadths above the clavicle. It supplies both muscles. Four cutaneous nerves (*transverse cervical, supraclavicular, greater auricular and lesser occipital*) also emerge near the accessory nerve and supply the skin of the neck and the upper part of the chest. The external jugular vein begins near the upper end of sternomastoid and runs down obliquely across this muscle to enter the subclavian vein. It is joined by the anterior jugular and other small veins at its lower end. The inferior belly of the omohyoid muscle crosses the lower part of the triangle.

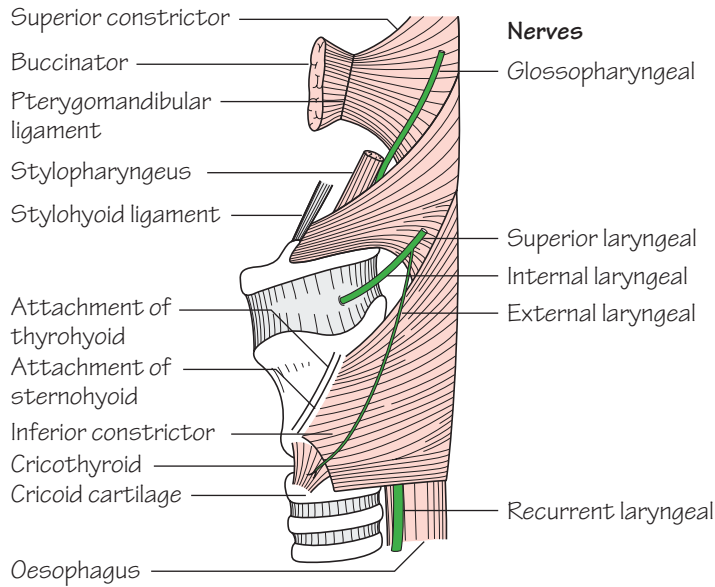
**The floor of the posterior triangle** is the *prevertebral fascia*, deep to which lie, from below upwards: scalenus anterior, scalenus medius and posterior, levator scapulae, and splenius capitis.

### Structures deep to the prevertebral fascia

- **The upper, middle and lower trunks of the brachial plexus** which emerge between the scalenus anterior and the scalenus medius, the lower trunk resting on the 1st rib.
- **The supraclavicular branches** of the brachial plexus (p. 73).

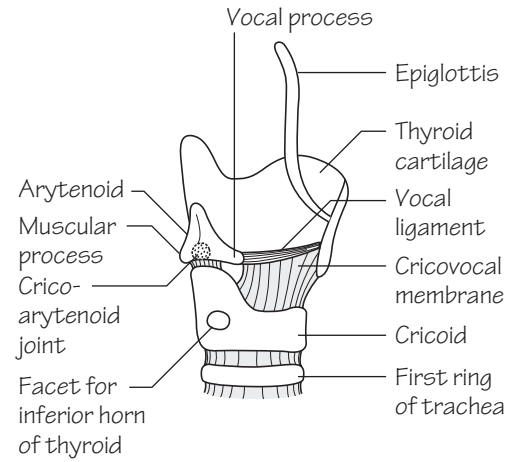


## 62 The pharynx and larynx



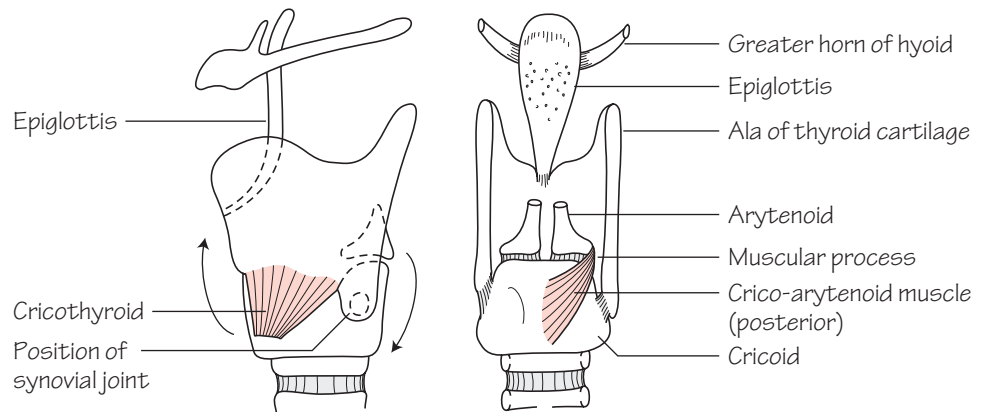
**Fig.62.1**

The pharynx and larynx, and some of the related nerves



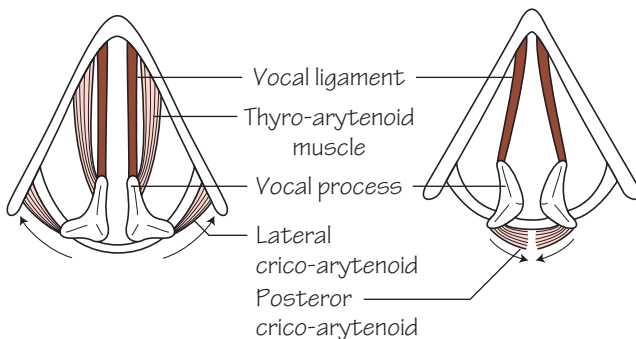
**Fig.62.2**

A midline section of the larynx to show the cricovocal membrane and vocal ligaments



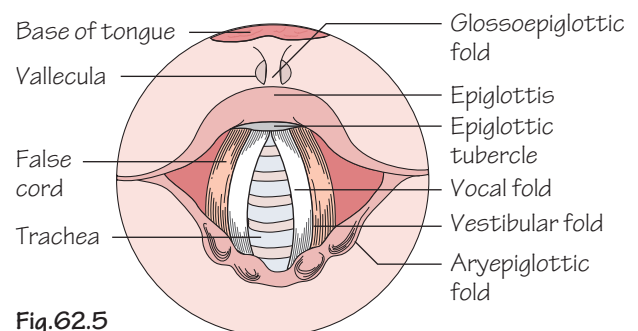
**Fig.62.3**

Left, the cricothyroid muscle and right, the posterior crico-arytenoid



**Fig.62.4**

The muscles causing abduction, adduction and relaxation of the vocal cords. Tightening of the cords is shown in Fig.62.3



**Fig.62.5**

The larynx as seen through a laryngoscope

## The pharynx

This is an incomplete striated muscular tube, opening in front into the nasal cavity, the mouth and the larynx, thus being made up of the *nasopharynx*, the *oropharynx* and the *laryngopharynx*. The muscular coat (Fig. 62.1) is formed by:

- **The superior constrictor:** arises from the *pterygomandibular ligament* (which spans between the pterygoid hamulus and the mandible just behind the third molar tooth).
- **The middle constrictor:** arises from the *stylohyoid ligament* and the lesser and greater horns of the hyoid bone.
- **The inferior constrictor:** arises from the *thyroid* and *cricoid cartilages*.

The constrictors encircle the pharynx and interdigitate posteriorly. The gaps between the constrictors are filled in by fascia. There is also an inner longitudinal layer of muscle. The *nasopharynx* is lined by ciliated columnar epithelium and on its posterior wall is situated a mass of lymphatic tissue, the *pharyngeal tonsil* or *adenoid*. The *pharyngotympanic (Eustachian) tube* opens into the nasopharynx at the level of the floor of the nose, the cartilage of the tube producing a distinct bulge behind the opening.

- **Nerve supply:**
  - *Motor*—pharyngeal branch of the vagus (p. 131).
  - *Sensory*—glossopharyngeal (p. 131).

## The larynx

### Palpable components

- **Hyoid bone**, level of C3.
- **Thyroid cartilage**, level of C4 and 5.
- **Cricoid cartilage**, level of C6.

### Other components

- **Arytenoid cartilages:** attached to upper border of the cricoid by synovial joints so that they can slide and rotate. Each has an anterior *vocal process* and a lateral *muscular process* (Figs 62.2 and 62.3).
- **Epiglottis:** a leaf-shaped piece of elastic cartilage attached to the back of the thyroid cartilage (Fig. 62.2) and projecting upwards behind the hyoid.
- **Thyrohyoid ligament:** joins the hyoid and the thyroid (Fig. 62.1).
- **Cricovocal membrane (cricothyroid ligament):** attached to the upper border of the cricoid and passes inside the thyroid to be attached to the back of the thyroid and to the vocal processes of the arytenoids (Fig. 62.2). The upper border is thickened to form the *vocal ligament* which, with the mucous membrane that covers it, forms the *vocal cords*.
- **Cricothyroid joint:** a small synovial joint between the inferior horn of the thyroid cartilage and the cricoid, permitting a hinge-like movement (Fig. 62.3).

- **Pyriform fossa:** the fossa between the posterior border of the thyroid cartilage and the cricoid and arytenoid cartilages. *It is important because a carcinoma in this region can remain 'silent' until it has spread to the cervical lymph nodes whereas a tumour of the vocal cords produces early voice changes.*

- **Mucous membrane:** mostly respiratory epithelium (ciliated columnar) but over the vocal cords it changes to stratified squamous so that the cords have a pearly appearance (Fig. 62.5).

- **Vestibular folds:** a pair of additional folds above the vocal folds (*false cords*). The space between the vocal and vestibular folds is the *sinus of the larynx*.

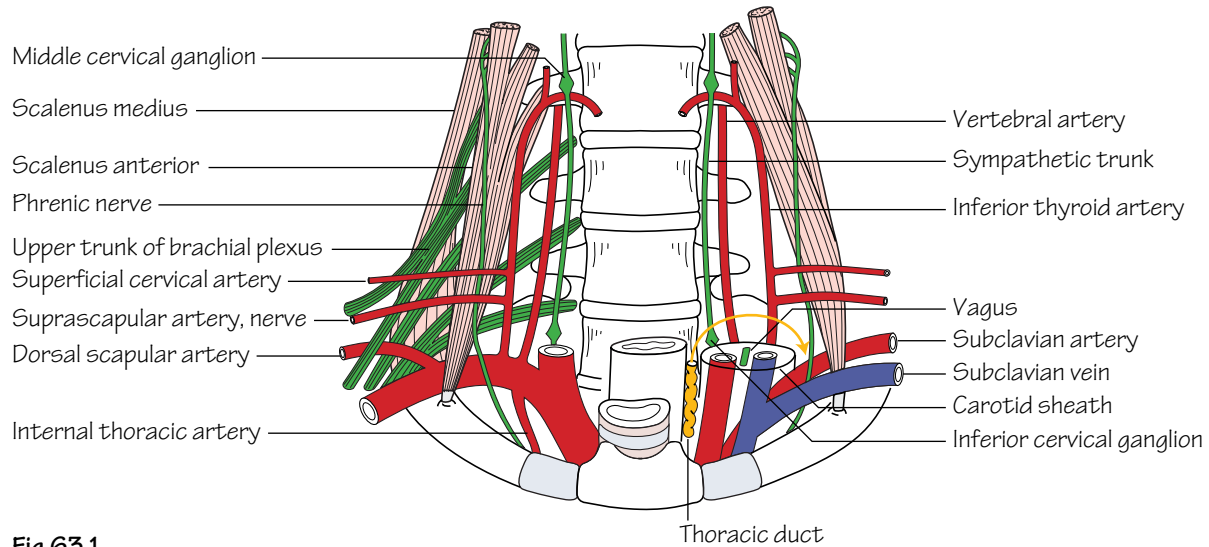
### The intrinsic muscles of the larynx

- **Cricothyroid** (Figs 62.1 and 62.3): situated on the *outside* of the larynx. Tenses the vocal cords.
- **Thyroarytenoid** (Fig. 62.4): from the back of the thyroid cartilage to the vocal process of the arytenoid. Relaxes the vocal cords.
- **Posterior cricoarytenoid** (Figs 62.3 and 62.4): from the back of the cricoid to the muscular process of the arytenoid. Abducts the vocal cords.
- **Lateral cricoarytenoid** (Fig. 62.4): adducts the vocal cords.
- **Interarytenoids and aryepiglottic muscle:** form a 'sphincter', together with the epiglottis, in order to close off the entrance to the larynx (*glottis*) during swallowing.
- **Nerve supply:**
  - *Motor*—*recurrent laryngeal nerve*, except for the cricothyroid which is supplied by the *external laryngeal nerve*.
  - *Sensory*—above the vocal cords, the *internal laryngeal nerve* which enters the larynx through the thyrohyoid membrane. Below the vocal cords, the *recurrent laryngeal nerve* (which is therefore a mixed nerve) which enters the larynx just behind the cricothyroid joint.

### Laryngoscopy (Fig. 62.5)

*The vocal cords may be seen by means of a warmed, angled mirror passed to the back of the throat. Only the edges of the cords can be seen because of the shadow of the false cords. Adduction of the cords may be observed by asking the patient to say a high-pitched 'eeee' while abduction occurs when saying 'Ahhh'. If one of the recurrent laryngeal nerves is divided, the cord lies in a position midway between adduction and abduction but this does not produce very severe voice changes because the uninjured cord can cross the midline to reach the paralysed cord. However, if both nerves are cut the cords lie in the cadaveric position, i.e. in the mid-position. If both nerves are damaged but not completely divided the cords are adducted since the abductors are more affected than the adductors (Semon's law). This may cause breathing difficulties.*

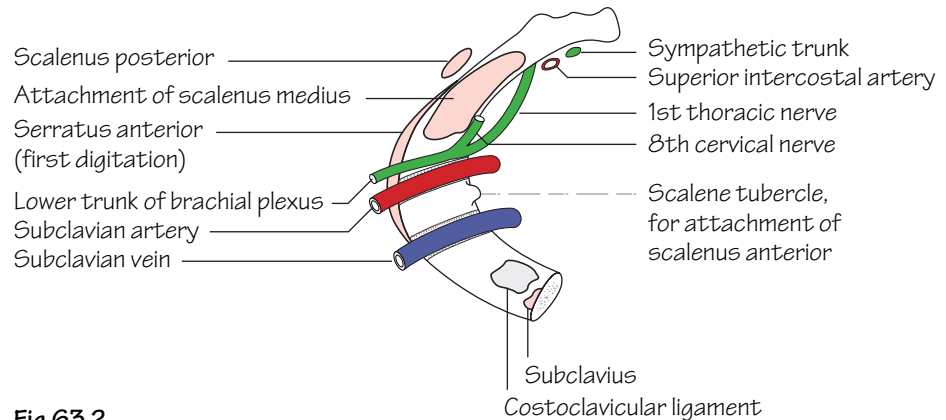
## 63 The root of the neck



**Fig.63.1**

The deep structures at the root of the neck and in the thoracic outlet.

The curved arrow on the right side of the diagram indicates the course of the thoracic duct



**Fig.63.2**

The structures related to the upper surface of the first rib

The area defined by the first thoracic vertebra, the first ribs and the manubrium sterni is called the *thoracic inlet (or outlet)* (Fig. 63.1). Through this relatively confined space pass the trachea and oesophagus, the carotid and subclavian arteries and the corresponding large veins as well as the apices of the lungs and important nerves.

### The scalene muscles

- **Scalenus anterior:** passes down from the transverse processes of some of the cervical vertebrae and is inserted by means of a narrow tendon into the scalene tubercle on the medial border of the 1st rib.

- **Scalenus medius:** is behind scalenus anterior and is inserted by muscular fibres into a large area of the 1st rib. The subclavian artery and the trunks of the brachial plexus are between the two muscles and the subclavian vein is in front of scalenus anterior. *The gap between the two muscles may be narrow and the tough tendon of scalenus anterior may compress the lower trunk of the brachial plexus and/or the subclavian artery, giving rise to one form of the thoracic outlet syndrome (see also cervical rib, p. 7).*

## The arteries

• **The subclavian artery** (p. 135): on the right side, from the *brachiocephalic artery* and, on the left, directly from the *arch of the aorta*. It arches over the apex of the lung and crosses the 1st rib in a shallow groove, which it shares with the lower trunk of the brachial plexus (Fig. 63.2). At the outer border of the 1st rib it becomes the axillary artery. It has five branches (p. 135):

- The *vertebral artery*.
- The *internal thoracic artery*.
- The *thyrocervical trunk*.
- The *costocervical trunk*.
- The *dorsal scapular artery*.

## The veins

• **The subclavian vein:** begins at the outer border of the 1st rib and lies in a shallow groove on the upper surface of the rib in front of scalenus anterior. At the medial border of this muscle it is joined by the *internal jugular vein* to form the *brachiocephalic vein*. The internal jugular vein is enclosed in the carotid sheath, along with the common carotid artery and the vagus nerve. Other veins entering it accompany the small arteries but the inferior thyroid veins are solitary and run down from the lower border of the thyroid gland, in front of the trachea, to reach the left brachiocephalic vein in the thorax.

## The nerves

• **The upper, middle and lower trunks of the brachial plexus:** emerge from between the scalenus anterior and medius and pass down

into the axilla. The suprascapular nerve arises from the upper trunk and joins the corresponding artery before passing back to the suprascapular notch. For further details, see Chapter 30.

• **The phrenic nerve:** is formed by branches from the 3rd, 4th and 5th (mainly the 4th) cervical nerves and descends on the anterior surface of scalenus anterior before crossing the subclavian artery and entering the thorax.

• **The vagus nerve:** this crosses the subclavian artery and descends into the thorax. On the right side it gives off the right recurrent laryngeal nerve which hooks under the artery and ascends, deep to the common carotid, to reach the larynx. The left recurrent laryngeal, having arisen in the thorax, runs upwards between the trachea and oesophagus.

• **The sympathetic trunk:** descends close to the vertebral artery. The *middle cervical ganglion* is close to the entry of the artery into the foramen transversarium of C6 and the *inferior cervical ganglion* is near the neck of the 1st rib behind the origin of the vertebral artery. It may be fused with the 1st thoracic ganglion to form the *stellate ganglion*.

## The thoracic duct (Fig. 63.1)

On the left side only. The duct ascends out of the thorax between the trachea and oesophagus and arches laterally between the carotid sheath in front and the vertebral artery behind. It ends by joining the junction between the internal jugular and subclavian veins.

## 64 The oesophagus and trachea and the thyroid gland

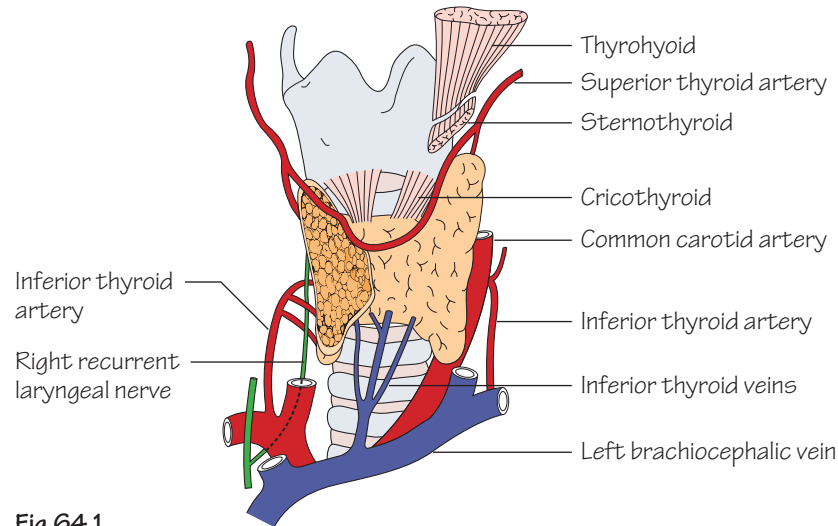


Fig.64.1

The thyroid and its blood supply. A large part of the right lobe has been removed

### The oesophagus

The oesophagus begins at the level of the cricoid cartilage and runs down behind and slightly to the left of the trachea. The *left recurrent laryngeal nerve* is in the groove between the oesophagus and trachea and the *thoracic duct* is to the left of the oesophagus.

### The trachea

The trachea begins at the level of the cricoid cartilage and ends by dividing into left and right bronchi at the level of the manubriosternal joint. The trachea can be palpated in the midline just above the suprasternal notch and can be seen in an X-ray as a dark shadow. The upper part of the trachea is crossed by the isthmus of the thyroid. *The trachea, bronchi and lungs develop from a groove in the floor of the embryonic pharynx which normally separates off except at the upper end. Anomalies of the separation process are not uncommon (tracheo-oesophageal fistula), the commonest variety (85%) being that in which the upper segment of the oesophagus ends blindly while the upper end of the lower segment communicates with the trachea.*

### The infrahyoid ('strap') muscles

- **Sternothyroid:** arises from the back of the manubrium and ascends to be attached to the outer surface of the thyroid cartilage.
- **Thyrohyoid:** is a continuation of the latter and is attached to the hyoid bone.
- **Sternohyoid:** is superficial to the other two and runs from the manubrium to the lower border of the hyoid.
- **Omothyoid:** the superior belly is attached to the hyoid and runs down to its intermediate tendon and then continues as the inferior belly across the posterior triangle to be attached to the scapula.

These infrahyoid muscles are all supplied by the ansa cervicalis (C1, 2 and 3). Their function is to fix the hyoid bone so that the suprahyoid muscles have a fixed base. Their main importance lies in their close relation to the thyroid gland.

### The thyroid gland

The thyroid is an endocrine gland with an extremely rich blood supply (Fig. 64.1). Its isthmus lies across the 3rd, 4th and 5th rings of the trachea and the lobes lie on either side, reaching up as far as the 'pocket' under the attachment of sternothyroid to the thyroid cartilage. It is enclosed in the thin *pretracheal fascia* and also has its own fibrous capsule. *When the gland is enlarged, the strap muscles are stretched tightly over it and the carotid sheath is displaced laterally. An important diagnostic feature is that swellings of the thyroid move on swallowing.*

#### • Blood supply:

- The *superior thyroid artery*—comes from the external carotid and runs down to enter the 'pocket' between the sternothyroid and the thyroid cartilage where it is close to the external laryngeal nerve. It divides into two branches which run down the posterior border and along the upper border.
- The *inferior thyroid artery*—has been described above (p. 135) and there is a very free anastomosis between the two arteries and between their branches and the small arteries of the trachea and oesophagus. It is thus possible to tie all four arteries during subtotal thyroidectomy and still leave an adequate blood supply to the remaining thyroid tissue and the parathyroids.
- **Venous drainage:** there are three veins on each side: the *superior* and *middle thyroid veins* drain into the internal jugular and the *inferior* into the left brachiocephalic.

### **Developmental anomalies**

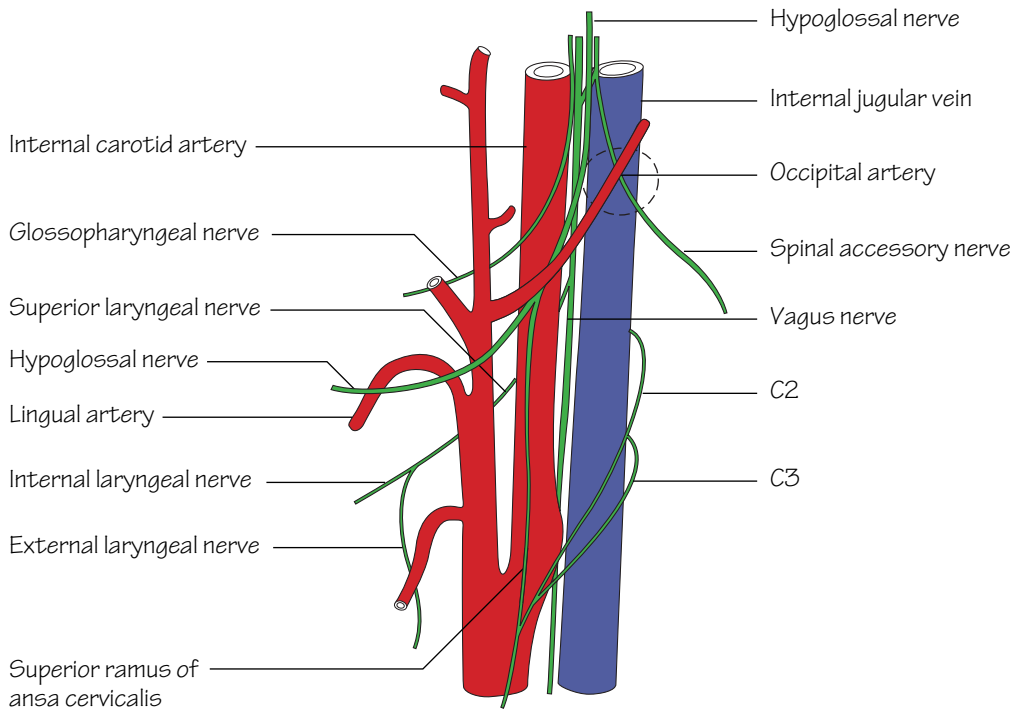
*The thyroid develops as an outgrowth from the floor of the pharynx (thyroglossal duct) in the position of the future foramen caecum of the tongue. It descends ventral to the larynx before dividing into two lobes. The stem of the outgrowth, the thyroglossal duct, normally disappears although it may remain in part. Aberrant thyroid tissue may occur anywhere along the course of the duct or thyroglossal cysts may appear. Such thyroid remnants move upwards when the tongue is protruded. Infection of a persistent thyroglossal duct may occur, when the duct must be excised.*

### **The parathyroid glands**

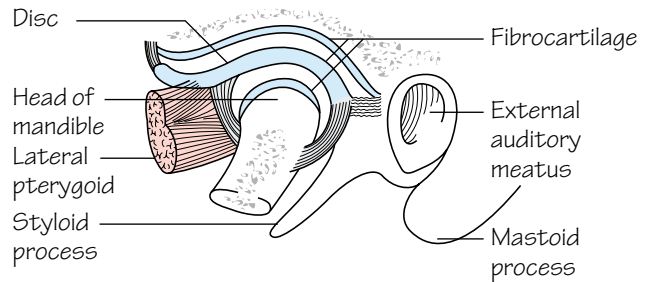
There are two parathyroids, superior and inferior, on each side. They are about the size of a pea and are embedded in the back of the thyroid (but outside its capsule). *They develop from the third (inferior parathyroid) and fourth (superior parathyroid) pharyngeal pouches of the embryo. The thymus also develops from the third pouch and may drag the inferior gland down with it so that the adult gland may lie in the thorax.*



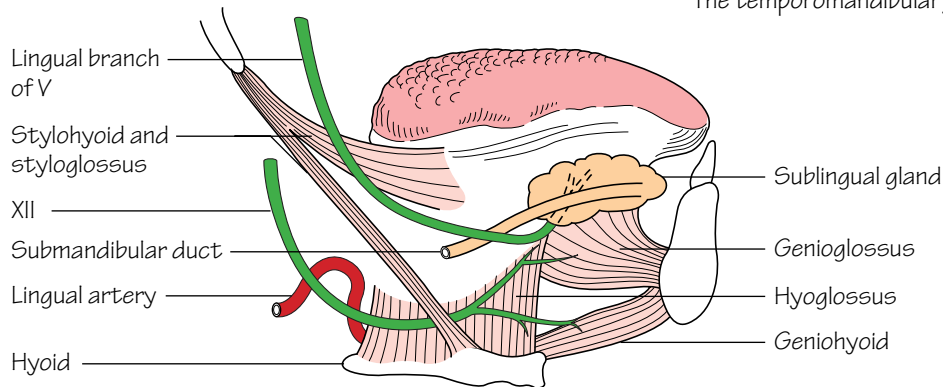
# 65 The upper part of the neck and the submandibular region



**Fig.65.1**  
The last four cranial nerves and their relation to the large vessels



**Fig.65.2**  
The temporomandibular joint



**Fig.65.3**  
The extrinsic muscle of the tongue and the related nerves

The 'foundation' for the upper part of the neck consists of the *superior* and *middle constrictors* of the pharynx and on these lie the *internal* and *external carotid arteries*, the *internal jugular vein* and the *last four cranial nerves* (Fig. 65.1).

- **The glossopharyngeal** runs forwards, across the internal carotid artery but deep to the external carotid (p. 131).
- **The vagus**, which is joined by the *cranial root of the accessory*, runs straight down, between the internal carotid and the internal jugular and within the carotid sheath (p. 131).
- **The spinal root of the accessory** runs backwards, crossing the internal jugular vein and the transverse process of the atlas to supply sternomastoid and trapezius (p. 131).
- **The hypoglossal**, having left the cranial cavity by means of the hypoglossal canal, is joined by the anterior ramus of the 1st cervical nerve, winds round the vagus and then runs downwards and forwards, superficial to both carotids, giving off the *descendens hypoglossi* in the process. The branches and distribution of these nerves have already been described (p. 131).

### The infratemporal region

This is the region deep to the ramus of the mandible.

#### Contents

- **The stem of the mandibular division of the trigeminal nerve** which enters through the foramen ovale and immediately breaks up into branches (Chapter 57).
- **The otic ganglion**, which lies medial to the nerve (Chapter 57).
- **The medial and lateral pterygoid muscles:** the *medial pterygoid* is inserted into the inner surface of the ramus and thus separates the region from the structures lying on the superior constrictor, described above. The *lateral pterygoid* runs backwards from the lateral pterygoid plate to the neck of the mandible and the intra-articular disc.
- **The maxillary artery:** enters the region by passing forwards deep to the neck of the mandible, and its branches correspond to those of the nerve with the addition of the **middle meningeal artery** which ascends to pass through the *foramen spinosum*. The maxillary artery leaves by entering the *pterygopalatine fossa*.
- **The temporomandibular joint** (Fig. 65.2): this is a synovial joint with an intra-articular disc but, unlike most other synovial joints, the articular cartilage and the disc are composed of fibrocartilage or even fibrous tissue. The lateral pterygoid muscle can pull the disc and the head of the mandible forwards onto the articular eminence. This occurs when the mouth is opened so that the joint is not a simple hinge joint. The axis of rotation is through the mandibular foramen so that the inferior alveolar nerve and vessels are not stretched when the mouth is opened. The mouth is opened by gravity and the suprahyoid muscles such as *mylohyoid* and *geniohyoid* and closed by the *masseter*, *temporalis* and *medial pterygoid*. *When the mouth is open and the head of the mandible is on the articular eminence the joint is unstable so that a blow on the chin may cause dislocation.*

### The submandibular region

This is the region below the mandible and extending upwards deep to the mandible as far as the attachment of the *mylohyoid muscle* to the mylohyoid line of the mandible. The contents of the submandibular region include:

#### Muscles

- **Mylohyoid:** from the hyoid to the mylohyoid line on the mandible (Fig. 55.2). On its surface lies the **anterior belly of the digastric muscle**, and the two have the same nerve supply (the *mylohyoid nerve*).
- The **posterior belly of the digastric** runs back to a groove medial to the mastoid process and the intermediate tendon is attached to the hyoid bone.
- **Hyoglossus:** from the greater horn of the hyoid up to the side of the tongue. Is partly deep to mylohyoid.
- **The middle constrictor of the pharynx:** behind and partly deep to the hyoglossus.

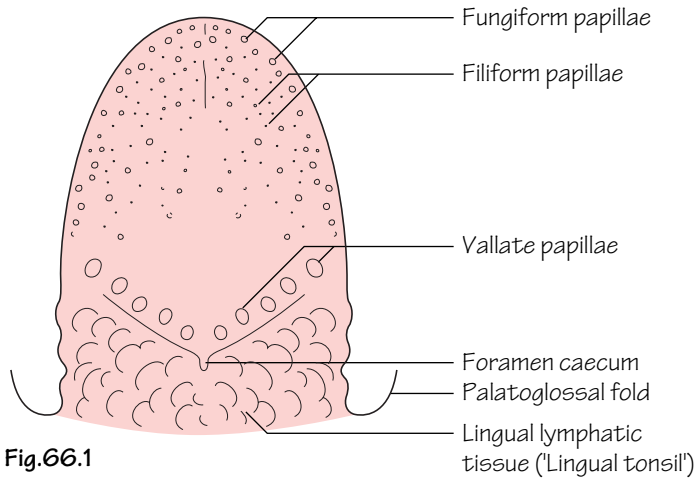
#### Nerves and vessels (Fig. 65.3)

- **The lingual artery:** leaves the external carotid with an upward loop and then runs forwards deep to the hyoglossus. It supplies the tongue.
- **The lingual nerve:** enters the region by passing just behind the third molar tooth, directly in contact with the mandible, and then loops forwards on the hyoglossus to enter the tongue. Suspended from it is the *submandibular ganglion*, in which parasympathetic fibres from the *chorda tympani* synapse before supplying the submandibular and sublingual glands. The lingual nerve carries *sensory fibres* from the anterior two-thirds of the tongue as well as *taste fibres* which are carried in the chorda tympani.
- **The hypoglossal nerve:** crosses the loop of the lingual artery and then runs forwards on the hyoglossus, below the lingual nerve, to enter the tongue and supply its intrinsic and extrinsic muscles.

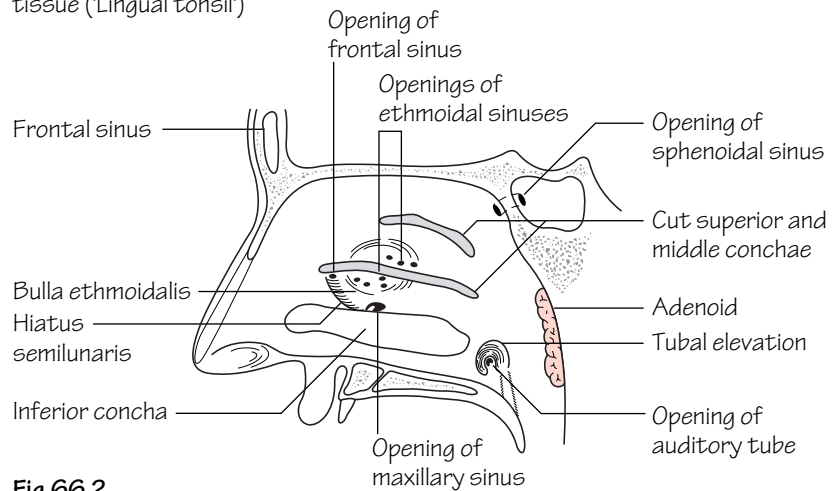
#### Salivary glands

- **The submandibular gland:** lies on the mylohyoid and the anterior belly of the digastric, extending up as far as the mylohyoid line. It also extends back onto the hyoglossus and has a deep process which passes forwards, deep to the mylohyoid. From this the *submandibular (Wharton's) duct* travels forwards to enter the mouth at the *sublingual papilla* near the midline. The duct is crossed by the lingual nerve which then passes deep to the nerve to enter the tongue. The *facial artery* is embedded in the posterior part of the gland before turning down, between the gland and the mandible, and then passing over the lower border of the mandible to supply the face.
- **The sublingual gland:** lies deep to the mylohyoid near to the midline. Its upper surface is covered by the mucous membrane of the mouth and its numerous ducts open onto a ridge in the floor of the mouth extending back from the sublingual papilla.

## 66 The mouth, palate and nose



**Fig.66.1**  
The upper surface of the tongue



**Fig.66.2**  
The lateral wall of the nasal cavity

The *hard palate* is formed by the *palatal process of the maxilla* and the *horizontal plate of the palatine bone*. The *soft palate* hangs like a curtain behind the mouth cavity.

### Muscles

- **Levator palati:** elevates the palate.
- **Tensor palati:** tenses the palate. These two muscles move the soft palate so that it moves towards the back wall of the oropharynx where it meets a part of the *superior constrictor* which contracts strongly to form a ridge—the *ridge of Passavant*. The mouth and nasal cavities are thus separated so that food does not regurgitate into the nose and so as to be able to pronounce the palatal consonants such as ‘g’ and ‘k’.
- **Palatoglossus and palatopharyngeus:** these pass downwards from the palate to the side of the tongue and the inside of the pharynx, respectively. They raise two ridges, the *palatoglossal* and *palatopharyngeal arches*, that are also called the *anterior* and *posterior pillars of the*

*fauces*. They separate the mouth from the oropharynx and between them is the *tonsillar fossa*.

### The nerve supply of the pharynx

The *pharyngeal plexus* is a plexus of nerves formed by:

- **The pharyngeal branch of the vagus**, which includes the cranial root of the accessory. This provides the motor supply to the muscles except for the tensor palati which is supplied by the mandibular division of the trigeminal.
- **The glossopharyngeal nerve**, which provides the sensory supply to the pharynx.
- **Branches from the sympathetic trunk.**

### The nerve supply of the palate

The palate is supplied by the greater and lesser palatine and the nasopalatine nerves from the maxillary division of the trigeminal (Fig. 57.2). These nerves also supply the inner surface of the gums.

### Other features

• **The tonsil:** a mass of lymphatic tissue lying in the tonsillar fossa which, like the rest of the lymphatic system, reaches its maximum size at puberty. Lateral to the tonsil is its fibrous capsule and the superior constrictor. It is supplied by the *tonsillar branch of the facial artery* but the bleeding that occurs after tonsillectomy is usually from the *paratonsillar vein*. The *pharyngeal tonsil (adenoid)* has already been mentioned and there is also a *lingual tonsil* lying in the back of the tongue.

• **The teeth:** the *deciduous (milk) teeth* comprise two *incisors*, a *canine* and two *molars*; the last occupy the position of the two premolars of the permanent teeth. The *permanent teeth* comprise two *incisors*, a *canine*, two *premolars* and three *molars*. The first milk teeth to erupt are usually the lower central incisors at about *6 months* and the first permanent teeth are the first molars at about *6 years*.

### The tongue

The tongue is divided developmentally and anatomically into an anterior two-thirds and a posterior one third, separated by the *sulcus terminalis*, a V-shaped groove with the foramen caecum at the apex (Fig. 66.1). The latter is the site of outgrowth of the *thyroglossal duct*. In front of the sulcus is a row of *vallate papillae*. *Filiform papillae* and red, flat-topped *fungiform papillae* can be seen on the more anterior parts of the tongue.

### Muscles (Fig. 65.3)

- **Intrinsic muscles:** run in three directions, longitudinally, transversely and vertically.
- **Hyoglossus:** from the greater horn of the hyoid bone.
- **Genioglossus:** from the genial tubercle on the back of the mandible.
- **Styloglossus:** from the styloid process.

The latter three muscles blend in with the intrinsic muscles. Genioglossus is especially important as it is inserted along the whole length of the tongue so that it is used to protrude the tongue.

### Nerve supply

- **Motor:** hypoglossal nerve.
- **Sensory:** anterior two-thirds by the *lingual nerve*; taste fibres travel

in the *chorda tympani*. Posterior one third by the *glossopharyngeal nerve*. A small part of the tongue near the epiglottis is supplied by the *internal laryngeal branch* of the vagus nerve.

*Since the anterior part of the tongue develops from a pair of lingual swellings, the nerves and blood vessels of each side of the tongue do not cross the midline (although some lymphatics do) so that a midline incision will not do any serious damage. If the motor supply is cut off on one side, the tongue will diverge to the affected side when protruded owing to the action of genioglossus on the sound side.*

### The nasal cavity

The boundaries of the nasal cavity include the:

- **Nasal septum:** perpendicular plate of the ethmoid, vomer and a large plate of cartilage.
- **Lateral wall** (Fig. 66.2): maxilla, lacrimal, ethmoid with its superior and middle conchae, perpendicular plate of the palatine, inferior concha (a separate bone).
- **Roof:** nasal bones, cribriform plate of the ethmoid, body of the sphenoid.
- **Floor:** palatal processes of the maxilla and palatine bones.

The spaces beneath the conchae are the *meatuses* and the region above the superior meatus is the *spheno-ethmoidal recess*.

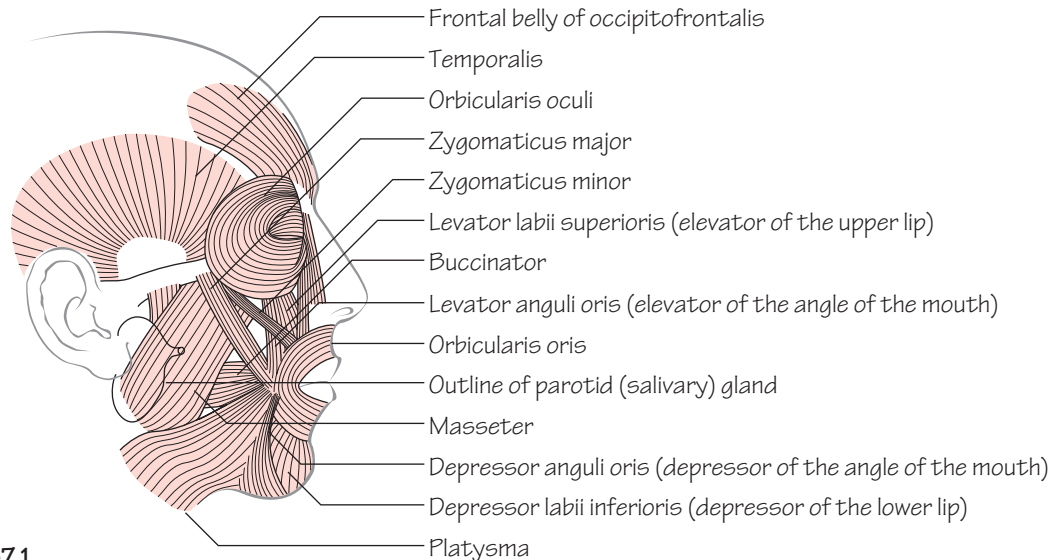
### The paranasal sinuses

- **The maxillary sinus:** inside the body of the maxilla, it opens into the middle meatus. Since the opening is in the upper part of the sinus it does not drain easily.
- **The frontal sinuses:** on each side of the midline, just above the medial part of the orbit. They drain into the middle meatus.
- **The ethmoidal sinuses:** in the body of the ethmoid bone and therefore deep to the medial wall of the orbit. Drain into the middle and superior meatuses.
- **The sphenoidal sinus:** inside the body of the sphenoid. Drains into the spheno-ethmoidal recess.

### The nasolacrimal duct

Drains tears from the medial angle of the eye. Drains into the inferior meatus.

## 67 The face and scalp



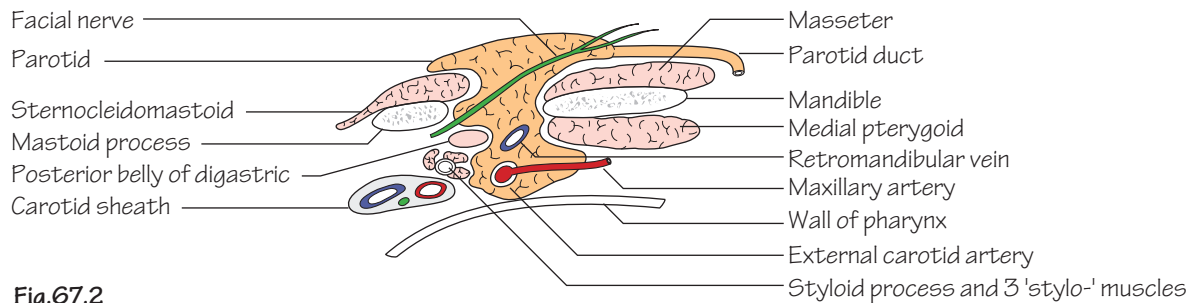
**Fig.67.1**

The principal muscles of facial expression and two of the muscles of mastication, temporalis and masseter

### The facial muscles

- **Muscles of mastication:** see Muscle index, p. 167. They are all supplied by the mandibular division of the trigeminal (p. 129).
- **Muscles of facial expression:** they are all supplied by the facial nerve. They have only one attachment to bone, or sometimes no attachment at all, the other end of the muscle being inserted into skin or blending with other muscles. The most important are shown in Fig.

67.1, from which their actions can be deduced. The *orbicularis oculi* has an *orbital* part which surrounds the eye as a sphincter and closes the eye tightly, while the *palpebral* part, which is in the eyelid, closes the eye gently as in sleep. The most important function of the *buccinator* is to keep the cheeks in contact with the gums so that food does not collect in this region. The *platysma* extends down the neck and over the clavicle and upper part of the chest.



**Fig.67.2**

A horizontal section through the parotid to show its relations

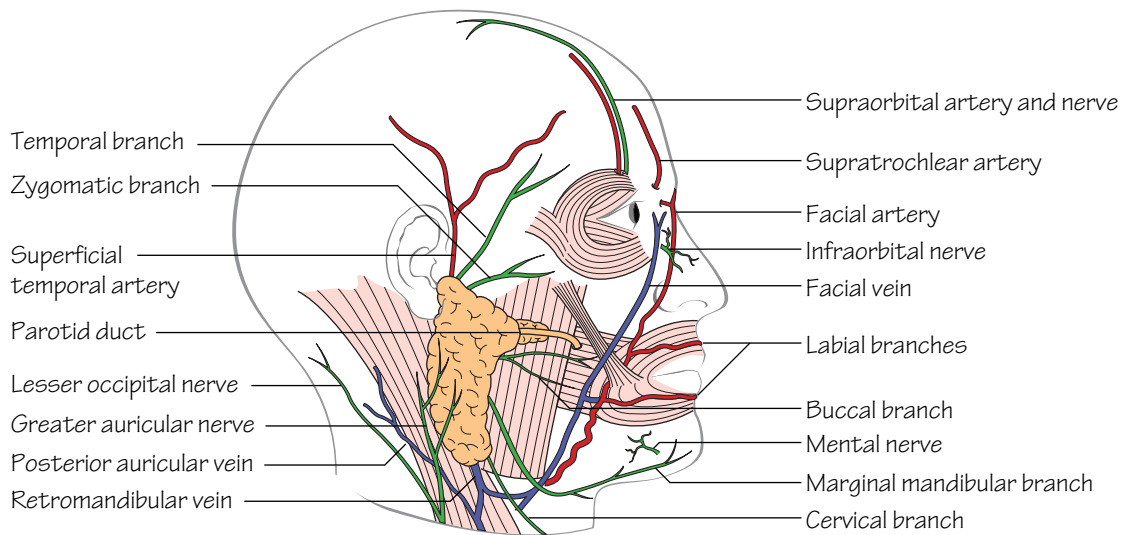
### The parotid gland

Situated mainly behind the mandible but spills over it onto the face. It extends deeply to come into contact with the pharynx and posteriorly it is moulded around the mastoid process and sternomastoid. The *parotid duct* extends forwards across masseter to enter the mouth opposite the second upper molar. The whole gland is enclosed in dense fascia so that swelling of the gland, as in mumps for instance, is very painful. Three structures pass through the gland (Fig. 67.2). These are, from superficial to deep: the *facial nerve*, the *retromandibular vein* (the beginning of the external jugular) and the *external carotid artery*, with its *maxillary* and *superficial temporal* branches.

### Nerves of the face

- **The facial nerve:** having left the stylomastoid foramen, the facial nerve enters the parotid and divides into *frontal*, *zygomatic*, *buccal*, *marginal mandibular* and *cervical* branches (Fig. 67.3), with some intercommunicating branches between them. Note that the marginal mandibular branch lies below the mandible for part of its course so that submandibular incisions are made well below the mandible. The cervical branch supplies platysma. *Lesions of the facial nerve, for example by tumours of the parotid, cause unilateral drooping of the face with loss of the normal skin creases, and it can be shown up by asking the patient to whistle or close up his eyes tightly.*
- **The trigeminal nerve:** sensory to the whole face (Fig. 67.3) except for the area over the parotid (see Chapter 57).





**Fig.67.3**  
The principal nerves and blood vessels of the face

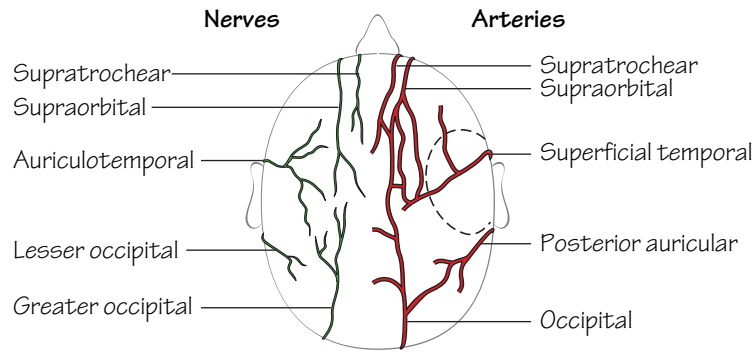
### Blood vessels of the face (Fig. 67.3)

- **The facial artery** (see p. 133): enters the face by passing over the lower border of the mandible at the anterior border of masseter. It has a tortuous course, passes close to the corner of the mouth and then alongside the nose to end near the medial angle of the eye. It anastomoses freely across the midline and with other arteries on the face.
- **The facial vein:** follows a straighter path than the artery and anastomoses at the medial angle of the eye with the ophthalmic veins and thus with the cavernous sinus. *This is a possible route for infection to travel from the face to the sinus.*

### The eye

- **The conjunctiva:** covers the surface of the eye and is reflected onto the inner surface of the eyelids, the angle of reflection forming the *fornix* of the conjunctival sac. *The conjunctiva over the surface of the eye is thin so that a conjunctival haemorrhage is bright red as the blood remains fully oxygenated.*

- **The tarsal plates:** are composed of dense fibrous tissue, more compact in the upper than the lower eyelid. Outside these are the muscle fibres of the palpebral part of the orbicularis oculi, some loose areolar tissue and skin. Partly embedded in the deep surface of the tarsal plates are the *tarsal (Meibomian) glands* which open onto the edge of the eyelids and produce a modified form of sebum.
- **The lacrimal gland:** is in the upper lateral part of the orbit, lying in a shallow hollow in the bone. Its secretions pass through 9–12 ducts into the superior fornix of the conjunctiva and thence across the eye to the medial angle (*canthus*). From here the tears pass into the *lacrimal puncta*, two minute openings in the upper and lower eyelids, and thence into the *lacrimal sac* lying in a groove in the lacrimal bone. This drains the tears into the *nasolacrimal duct* which opens into the inferior meatus of the nose.



**Fig.67.4**  
The nerves and blood vessels of the scalp.  
The dotted line shows a temporal 'flap'

### The scalp

The scalp is made up of five layers which form a useful mnemonic:

- Skin.
- Cutaneous fat and connective tissue.
- Aponeurosis (epicranial): this is a tough sheet of dense connective tissue into which are inserted the occipital and frontal bellies of the *occipitofrontalis* muscle.
- Loose areolar tissue: this forms a plane of cleavage in head injuries so that, in some cases, 'scalping' can occur. It also forms a plane in which blood can spread for a long distance.
- Pericranium: the periosteum of the outside of the skull.

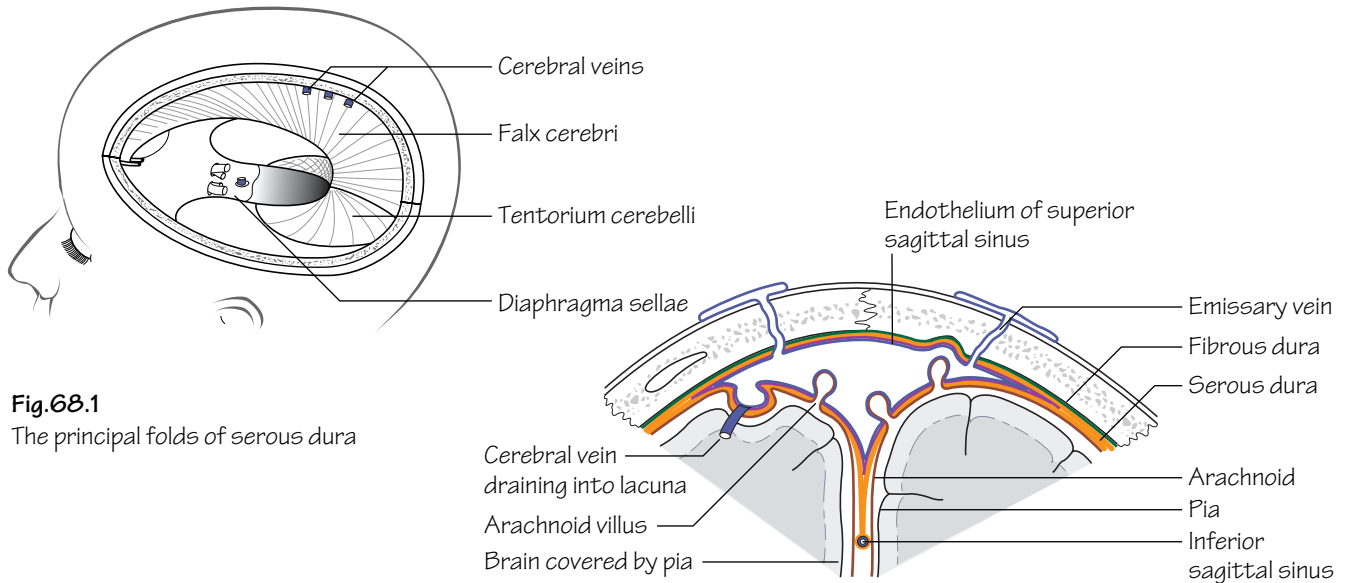
### Blood vessels and nerves

All enter from the periphery and are shown in Fig. 67.4. The vessels anastomose freely. Incisions can be centred on one artery which can keep a large flap of skin viable.

### Emissary veins

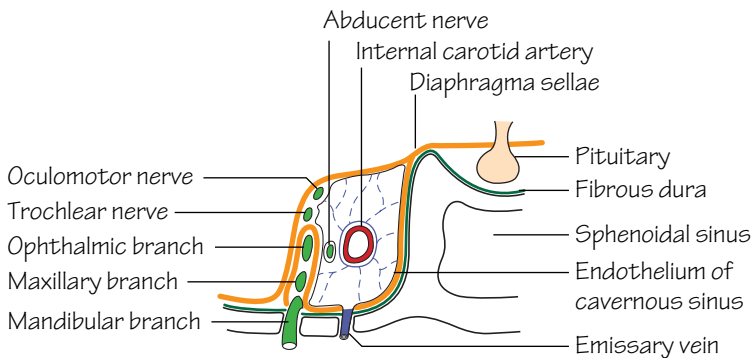
Small veins that pass through the skull and unite the veins of the scalp with the intracranial veins. They form a possible route for infection to reach the cranial cavity.

## 68 The cranial cavity



**Fig. 68.1**  
The principal folds of serous dura

**Fig. 68.2**  
A cross-section through the superior sagittal sinus to show the arachnoid villi projecting into the sinus



**Fig. 68.3**  
A cross-section through the cavernous sinus

### The meninges

The meninges comprise the dura, pia and arachnoid mater. The *cerebrospinal fluid* is produced in the choroid plexuses of the lateral, 3rd and 4th ventricles of the brain and leaves through the three foramina in the roof of the 3rd ventricle. It passes into the *subarachnoid space* between the arachnoid and pia and serves to protect the brain and spinal cord.

- **The dura mater** (Fig. 68.1): the *fibrous layer* is closely adherent to the bone but the *serous layer* separates from the fibrous layer in places

to form the *dural venous sinuses* which are lined by endothelium. It also forms two large sheets—the *falx cerebri* and the *tentorium cerebelli* (see below).

- **The arachnoid mater:** deep to the dura. Bridges over the sulci and fissures of the brain. The subarachnoid space contains the cerebrospinal fluid.
- **The pia mater:** follows the contours of the brain, dipping into the sulci.

### **The falx cerebri**

The *falx cerebri* projects down in the sagittal plane to separate partially the two cerebral hemispheres. It tapers to a point anteriorly but posteriorly it is attached to the tentorium. The *superior sagittal sinus* (Fig. 68.2) is in its attached border and the *inferior sagittal sinus* is in its free border. Veins from the cerebral hemispheres drain into the superior sagittal sinus or into diverticula from it, the *lacunae laterales*. In places the underlying arachnoid sends small outgrowths through the serous dura to project into the sinus. These are the *arachnoid villi* and they are the site of absorption of cerebrospinal fluid into the bloodstream. In later life they clump together to form *arachnoid villi* which make indentations in the skull.

### **The tentorium cerebelli**

The *tentorium cerebelli* forms a roof over the posterior cranial fossa and the cerebellum. Its free border is attached to the posterior clinoid processes and through the opening passes the brainstem. The *transverse sinuses* are in the attached border of the tentorium.

There are two smaller projections of serous dura—the *falx cerebelli* between the two cerebellar hemispheres and the *diaphragma sellae* which forms a roof over the pituitary fossa and the pituitary gland.

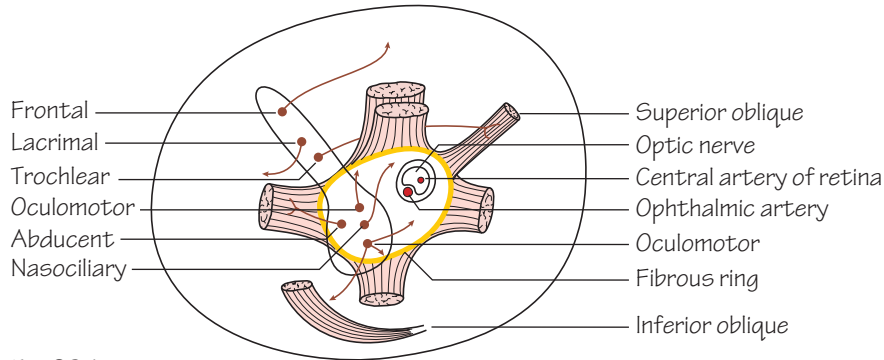
### **The cavernous sinus** (Fig. 68.3)

The cavernous sinus lies on either side of the pituitary fossa and the body of the sphenoid. Like the other venous sinuses, it is formed by a layer of serous dura lined by endothelium. In addition, a layer of serous dura from the posterior cranial fossa projects forwards into the side of the cavernous sinus to form the *cavum trigeminale*.

### **Contents**

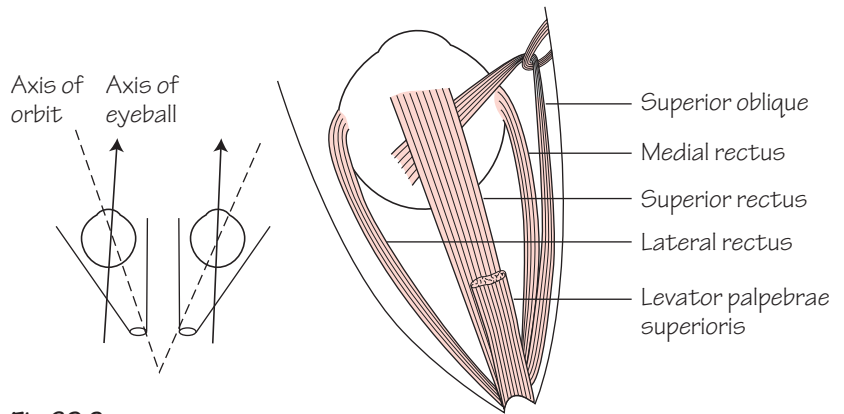
- **Internal carotid artery:** see p. 133.
- **Oculomotor nerve:** see p. 127.
- **Trochlear nerve:** see p. 127.
- **Abducent nerve:** see p. 131.
- **Three divisions of the trigeminal nerve:** see p. 129.

# 69 The orbit and eyeball



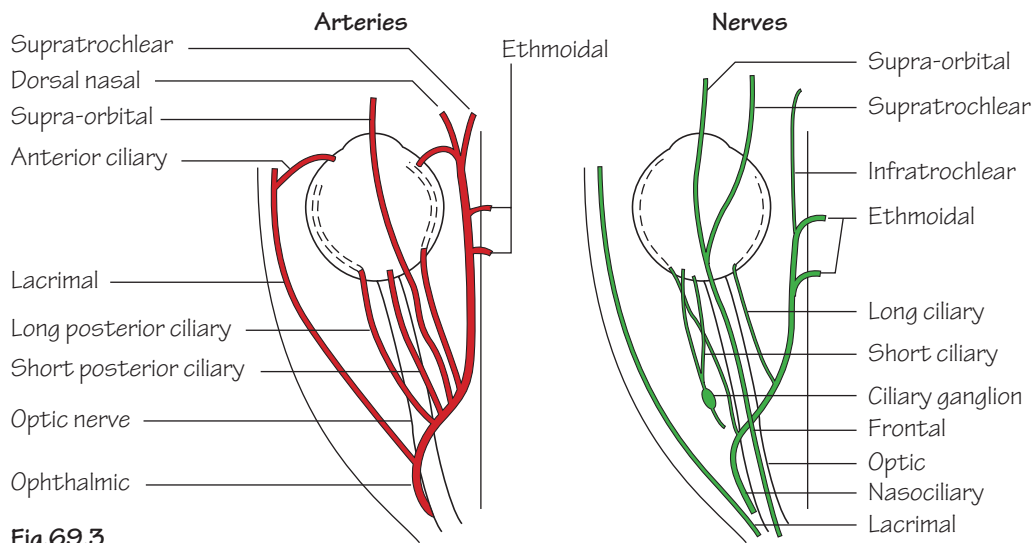
**Fig.69.1**

The back of the orbit to show the origins of the muscles that move the eyeball and the nerves that enter through the superior orbital fissure and the optic canal



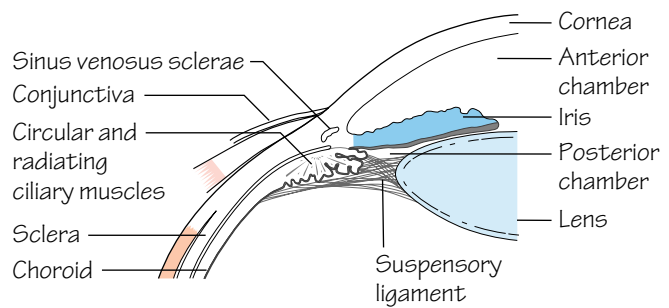
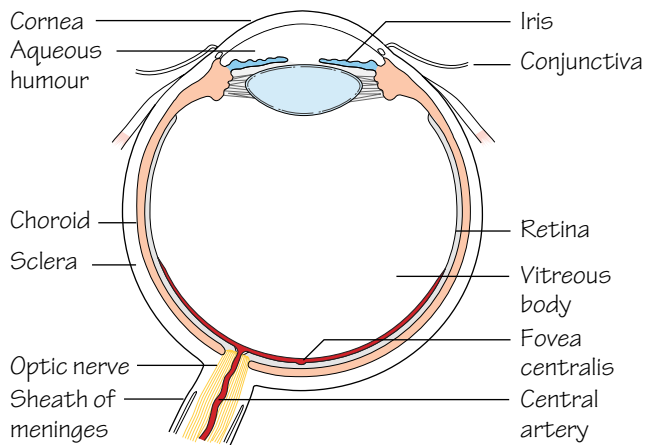
**Fig.69.2**

The muscles that move the eyeball seen from above



**Fig.69.3**

The arteries and nerves of the orbit



**Fig.69.4**

The eyeball in section and detail of the iridocorneal angle

The bony walls of the orbit have already been described (Chapter 55).

The orbit contains the eyeball and optic nerve, along with the 3rd, 4th and 6th cranial nerves and the three branches of the ophthalmic division of the trigeminal nerve.

The parasympathetic *ciliary ganglion* is attached to a branch of the oculomotor nerve.

The *ophthalmic artery* supplies the contents of the orbit, and the *superior* and *inferior ophthalmic veins* drain it, passing through the superior orbital fissure.

• **The superior orbital fissure:** this slit-like opening is divided into two parts by the fibrous ring that forms the origin of the main muscles that move the eyeball. The ring also includes the *optic canal* (Fig. 69.1). It is the portal of entry for a number of important structures:

- *Above the ring*—frontal, lacrimal and trochlear nerves.
- *Within the ring*—two divisions of the oculomotor, the nasociliary and the abducent nerves.

• **The optic canal:** transmits the optic nerve and the ophthalmic artery.

• **The inferior orbital fissure:** transmits the maxillary nerve and some small veins.

• **The muscles of the eyeball** (Fig. 69.2), except for the inferior oblique, take origin from the fibrous ring and spread out to form a fibromuscular cone that encloses the eyeball. The ring also gives origin to the *levator palpebrae superioris* which is inserted into the upper eyelid and opens the eye.

- The *lateral rectus*—turns the eyeball laterally.
- The *medial rectus*—turns the eyeball medially.
- The *superior rectus*—because of the different long axes of the orbit and of the eyeball, turns the eye upwards and medially.
- The *inferior rectus*—for the same reason, turns the eye downwards and medially.
- The *superior oblique*—passes along the medial wall of the orbit, turns sharply through a fibrous pulley and is inserted into the upper part of the eyeball, below the superior rectus. It turns the eye downwards and laterally. When this muscle and the inferior rectus contract together, the eye turns directly downwards.
- The *inferior oblique*—arises from the floor of the orbit, passes under the eyeball like a hammock and is inserted into its lateral side. It turns the eye upwards and laterally. Together with the superior rectus it turns the eye directly upwards.

• **The nerve supply of the orbital muscles:** the lateral rectus ('abductor') of the eye is supplied by the *abducent nerve*, the superior rectus (the 'muscle with the pulley') is supplied by the *trochlear nerve*. All the others, including *levator palpebrae superioris*, are supplied by the *oculomotor nerve*.

• **The other nerves and the vessels of the orbit** are shown in Fig. 69.3. The most important branch of the ophthalmic artery is the *central artery of the retina* which enters the optic nerve and is the only blood supply to the retina.

### The eyeball (Fig. 69.4)

The eyeball is composed of three layers. The outermost is a tough fibrous layer, the *sclera*. Within this is the very vascular *choroid* and inside this again is the sensory part of the eye, the *retina*. Anteriorly, the sclera is replaced by the transparent *cornea*, which is devoid of vessels or lymphatics and can therefore be transplanted. At the corneoscleral junction there is an important venous structure, the *sinus venosus sclerae* (*canal of Schlemm*). Behind the cornea, the choroid is replaced by the *ciliary body*, with its radially arranged *ciliary processes*, and the *iris*. The ciliary body contains the circular and radial smooth muscle fibres of the *ciliary muscle*, supplied by parasympathetic fibres from the ciliary ganglion via the oculomotor nerve. These, when they contract, relax the lens capsule and allow the lens to expand; thus they are used in near vision. The iris contains smooth muscle fibres of the *dilator pupillae* and *sphincter pupillae*, supplied, respectively, by the *sympathetic system* (from the *superior cervical ganglion*) and the *parasympathetic system* (from the *oculomotor nerve* via the *ciliary ganglion*). The *lens* lies behind the pupil and is enclosed in a delicate *capsule*. It is suspended from the ciliary processes by the *suspensory ligament*.

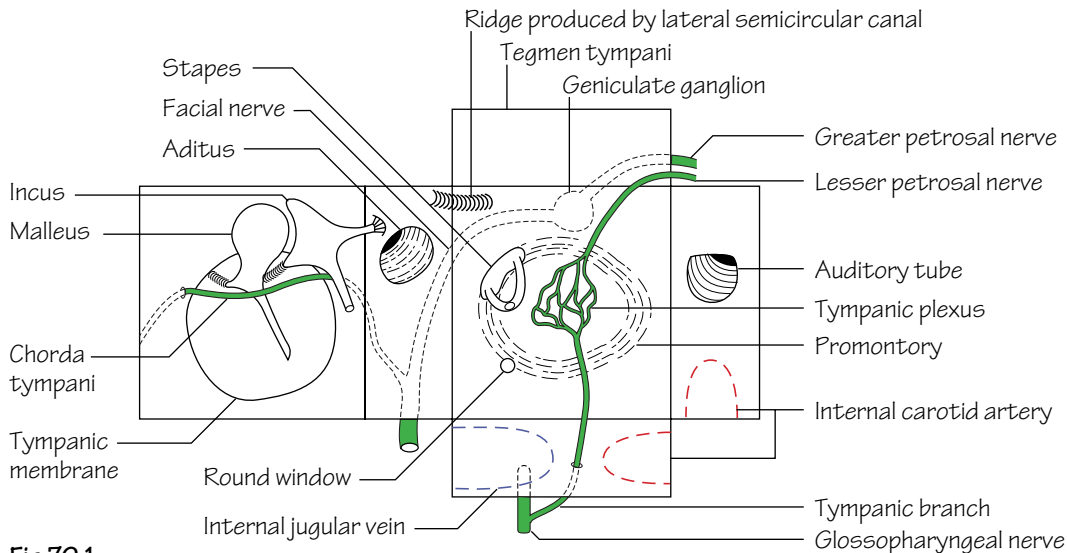
The ciliary body secretes the *aqueous humour* into the *posterior chamber* of the eye (lying behind the pupil). The aqueous then passes through the pupil into the *anterior chamber* and is reabsorbed into the sinus venosus sclerae. *Any interference with this process can give rise to a dangerous increase in intra-ocular pressure, a condition known as glaucoma.*

Behind the lens the eyeball is occupied by the gelatinous *vitreous humour*.

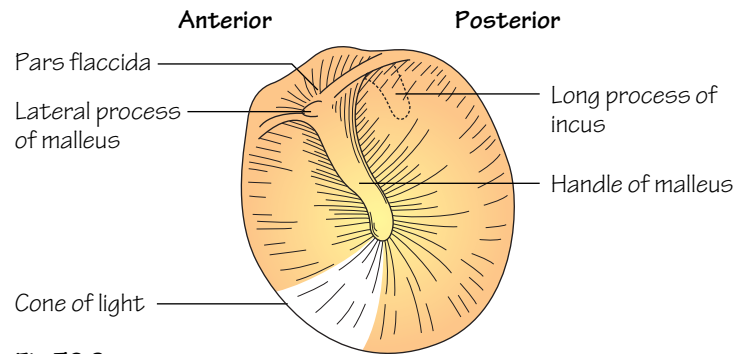
The *retina* consists of an inner nervous layer and an outer pigmented layer. The nervous layer has an innermost layer of ganglion cells whose axons pass back to form the optic nerve. Outside this is a layer of bipolar neurones and then the receptor layer of rods and cones. Near the posterior pole of the eye is the yellowish *macula lutea*, the receptor area for central vision. The *optic disc* is a circular pale area marking the end of the optic nerve and the site of entry of the central artery of the retina. This divides into upper and lower branches, each of which gives temporal and nasal branches. *Since the subarachnoid space and its contained cerebrospinal fluid reach to the back of the eyeball, any increase in intracranial pressure can give rise to changes in the optic disc which are visible through an ophthalmoscope.*



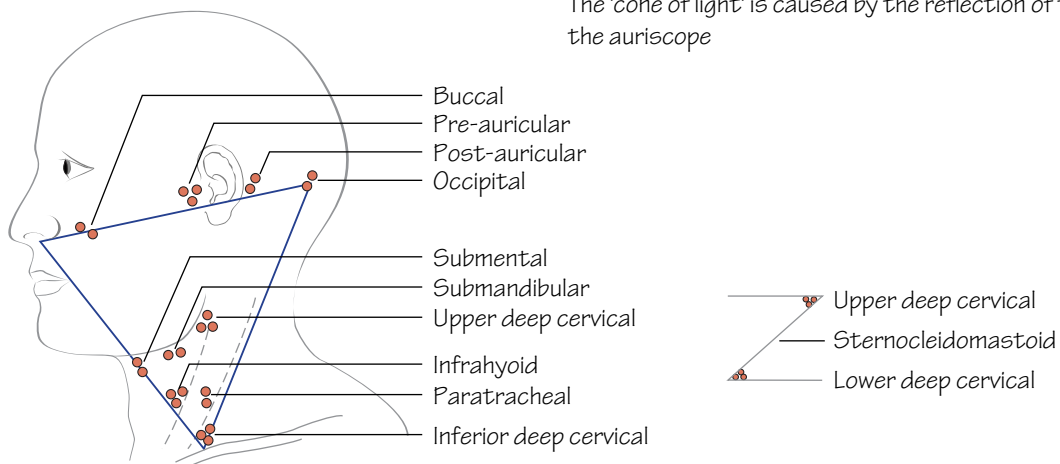
# 70 The ear, and lymphatics and surface anatomy of the head and neck



**Fig.70.1**  
A diagram representing the middle ear as an opened-out box



**Fig.70.2**  
The left tympanic membrane, as seen through an auriscope. The 'cone of light' is caused by the reflection of the light of the auriscope



**Fig.70.3**  
The principal groups of lymph nodes of the head and neck arranged as a triangle. The inset (right) shows the two major groups into which the others eventually drain

## The ear

The ear is subdivided into the outer ear, the middle ear and the inner ear.

### The outer ear

The outer third of this is cartilaginous and the inner two-thirds is bony. Lined by skin with ceruminous (wax) glands.

### The middle ear

This has four walls, a roof and a floor. It can therefore be represented diagrammatically by an opened-out box (Fig. 70.1).

#### • The lateral wall:

- The *tympanic membrane* (Fig. 70.2)—the handle of the malleus embedded in its middle layer. This is crossed by the *chorda tympani*, above which is the *pars flaccida*. The ‘*cone of light*’ is the reflection of the light from the auriscope.
- The *epitympanic recess (attic)*—the part of the middle ear cavity above the tympanic membrane.
- The *ossicles: the malleus, incus and stapes*—the stapes engages with the oval window. The ossicles transmit vibrations of the membrane to the inner ear.

#### • The medial wall:

- The *promontory*—a bulge produced by the first turn of the cochlea.
- The *oval window*—leads into the inner ear.
- The *facial nerve*—runs backwards and then downwards in a bony canal in the medial wall. It bears the geniculate ganglion and gives off the *chorda tympani*.

• **The anterior wall:** the *pharyngotympanic (Eustachian) tube* opens onto the anterior wall and leads down to the nasopharynx. Its function is to equalize the pressure between the middle ear and the pharynx.

• **The posterior wall:** the *aditus* leads backwards into the *mastoid antrum*, a cavity in the mastoid bone which, in turn, leads into the *mastoid air cells*.

• **The roof:** the *tegmen tympani*, a thin plate of bone that separates the middle ear from the middle cranial fossa.

• **The floor:** separates the middle ear from the internal carotid artery and the internal jugular vein.

### The inner ear

The inner ear is involved in both hearing and balance. It consists of two components:

• **The osseous labyrinth:** comprises the *vestibule*, the *semicircular canals* and the *cochlea*. The labyrinth itself consists of spaces in the petrous temporal bone and it contains the *membranous labyrinth*.

• **The membranous labyrinth:** comprises the *utricle* and *sacculle* (in the vestibule), the *semicircular ducts* (in the semicircular canals) and the *duct of the cochlea* (in the cochlea). The utricle and sacculle are concerned with the sense of position and the semicircular ducts are concerned with the sensation of motion. The cochlear duct is the organ of hearing. All are supplied by the *vestibulocochlear (auditory) nerve*.

## The lymphatics of the head and neck (Fig. 70.3)

• **Upper deep cervical nodes (*jugulodigastric nodes*):** these are situated between the upper end of sternomastoid and the angle of the

mandible and also deep to sternomastoid. They drain the head and the upper part of the neck, directly or indirectly (but there are no lymphatics in the cranial cavity).

• **The lower deep cervical nodes (*jugulo-omohyoid nodes*):** in the posterior triangle between the lower end of sternomastoid and the clavicle. They drain the lower part of the neck and also receive lymph from the upper deep cervical nodes, from the breast and some of the lymph from the thorax and abdomen. The efferents from this group drain into the thoracic or left lymph duct via the *jugular trunk*.

• **Smaller groups of nodes** are shown in Fig. 70.3.

• **The lymph drainage of the tongue:** the tip of the tongue drains into the *submental nodes*. The rest of the anterior two-thirds drains into the *submandibular nodes*, some crossing the midline and some passing directly to the *upper deep cervical nodes*. The posterior two-thirds drains directly into the *upper deep cervical nodes*.

• **The lymph drainage of the larynx:** above the vocal cords the larynx drains into the *infrahyoid nodes* and thence to the *upper deep cervical group*. Below the cords, drainage is to the *paratracheal and inferior deep cervical nodes*.

## Surface anatomy of the head and neck

• **The middle meningeal artery:** the *anterior branch* may be exposed at a point 4 cm above the midpoint of the zygomatic arch. The *posterior branch* may be represented on the surface by a pencil placed behind the ear.

### The face

• **The supraorbital, infraorbital and mental nerves:** all lie on a vertical line passing between the two premolar teeth.

• **The facial artery** can be felt on the mandible at the anterior border of the masseter.

• **The superficial temporal artery** is just in front of the tragus of the ear.

• **The parotid duct** follows the middle part of a line from the tragus of the ear to the middle of the upper lip. It hooks over the anterior border of the masseter where it can be easily felt.

### The neck

• **The sternomastoid muscle** (with the *external jugular vein* on its surface) may be made to contract by asking the patient to turn his head to the *opposite* side against resistance.

• **The trunks of the brachial plexus** can be palpated in the angle between the sternomastoid and the clavicle.

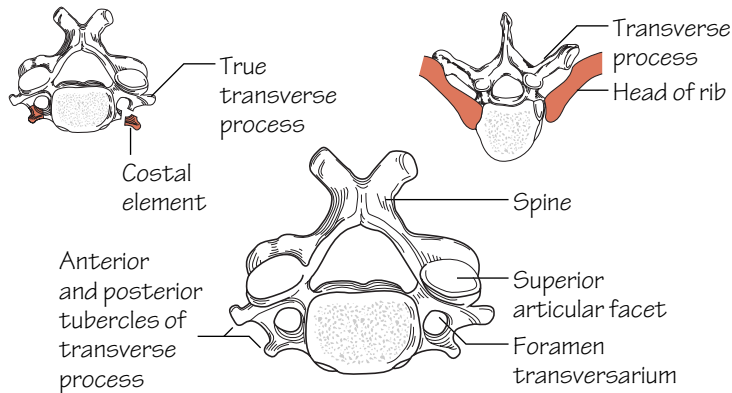
• **The subclavian artery** is palpable by deep pressure behind the middle of the clavicle. A cervical rib may also be palpable.

• **The hyoid bone, and the thyroid and cricoid cartilages** are easily felt. The larynx, and any swellings associated with it, move upwards on swallowing, as does the thyroid gland. Thyroglossal cysts move upwards when the tongue is protruded.

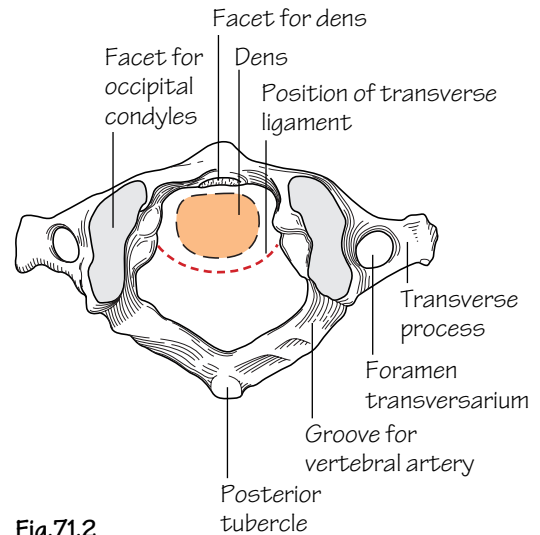
• **The trachea** is palpable in the suprasternal notch.

• **The common carotid artery** can be felt in front of sternomastoid and can be compressed against the transverse process of the 6th cervical vertebra (carotid tubercle).

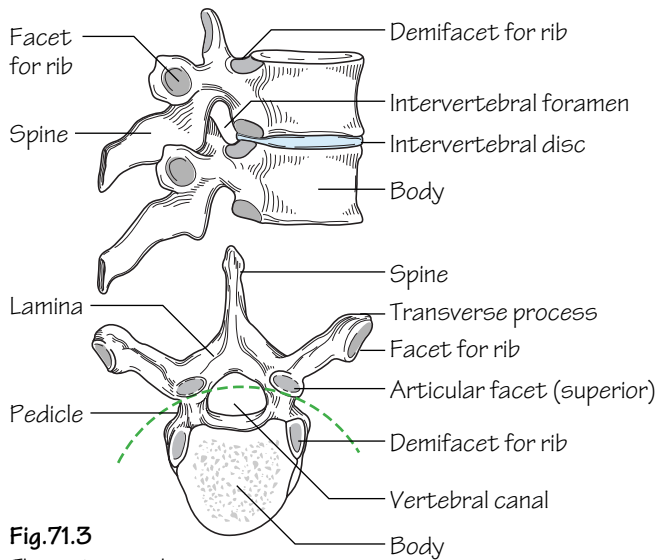
# 71 The spine



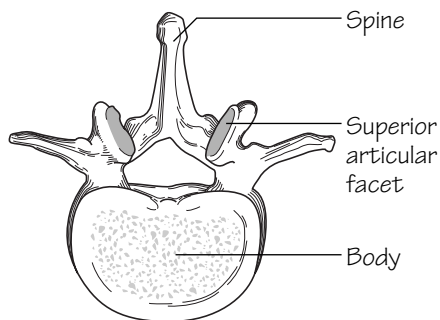
**Fig. 71.1**  
A cervical vertebra.  
The anterior tubercles of the transverse processes represent the costal elements



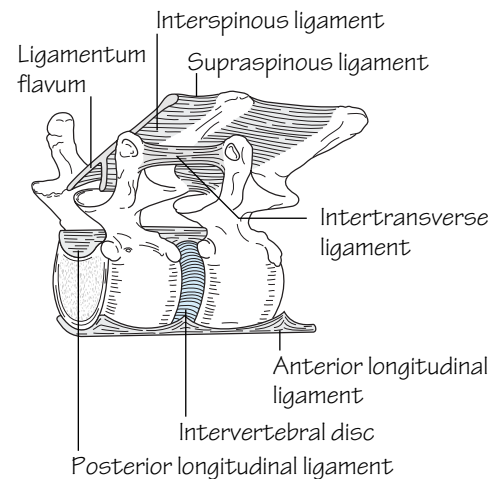
**Fig. 71.2**  
The upper surface of the atlas.  
The dotted area shows the position of the dens and the dotted line indicates the transverse ligament



**Fig. 71.3**  
Thoracic vertebra.  
The articular facets lie on the arc of a circle, thus permitting rotation



**Fig. 71.4**  
A lumbar vertebra.  
The direction of the articular facets does not permit rotation



**Fig. 71.5**  
The ligaments joining two adjacent vertebrae

There are 12 thoracic, five lumbar, five sacral and 3–5 coccygeal vertebrae. They are held together by ligaments, intervertebral discs and synovial joints between the articular processes. The weight-bearing portion of the vertebra is the body so that the size of the vertebral bodies increases from above downwards and when one of the bodies is diseased it will eventually collapse. The bodies contain red bone marrow so that the veins that drain them (*basivertebral veins*) produce large foramina on the backs of the bodies.

- **Cervical vertebrae** (Fig. 71.1): small *bodies*, *bifid spines*, *transverse processes* with *anterior* and *posterior tubercles* and a *foramen transversarium* for the passage of the vertebral artery. The body of the first vertebra (atlas) fuses with that of the second (axis) during development to produce its *dens (odontoid process)* which is held in place by a transverse ligament (Fig. 71.2).

- **Thoracic vertebrae** (Fig. 71.3): heart-shaped *bodies*, upper and lower *demifacets* for the heads of the ribs, long downturned *spine*, long *transverse processes* with a *facet* for the tubercles of the rib.

- **Lumbar vertebrae** (Fig. 71.4): a massive *body*, large *transverse processes*, a triangular *vertebral canal* and large, backwardly projecting *spines* so that a needle may be inserted between them in the operation of *lumbar puncture*. The *articular facets* face mediolaterally so that they prevent rotation.

- **Sacral vertebrae** (Fig. 23.3): fused together to form the *sacrum*.

### The intervertebral joints

The upper and lower surfaces of the bodies are covered with hyaline cartilage and are separated by the fibrocartilaginous *intervertebral discs*. Each disc has a peripheral fibrous ring (*annulus fibrosus*) and a central more spongy *nucleus pulposus* which lies nearer to the back than to the front of the disc. The nucleus pulposus is rich in glycosaminoglycans so that it has a high water content, but this diminishes with increasing age. The nucleus may then herniate through the annulus fibrosus, passing *backwards* (compressing the spinal cord), *posterolaterally* (compressing a spinal nerve) or *upwards* (into a vertebral body—a *Schmorl's node*). The discs are thickest in the lumbar and cervical regions, so that these are the regions of most movement.

The vertebrae are also held together by ligaments that join each of the components of the vertebrae (Fig. 71.5) except for the pedicles (the spinal nerves have to pass between these in the intervertebral foramina). Thus there are:

- **Anterior and posterior longitudinal ligaments** joining the front and back of the bodies (the posterior ligaments thus lie within the vertebral canal).
- **Supraspinous and interspinous ligaments.**
- **Intertransverse ligaments.**
- **Ligamenta flava** (which contain much elastic tissue and join the laminae).
- **Capsular ligaments** of the synovial joints between the articular processes.

### Curves of the spine

In the fetus, the whole developing spine is curved so that it is concave forwards (*primary curvature*). A few months after birth the baby begins to hold its head up and the cervical spine develops a forward convexity (*secondary curvature*). Later in the first year the baby begins to stand up and another forward convexity develops in the lumbar region (*secondary curvature*). The primary curves are mainly due to the shape of the vertebral bodies but the secondary curves are due to the shape of the intervertebral discs.

### Movements of the spine

- **Cervical spine:** movement is free in the cervical region of the spine: flexion and extension, side flexion (associated with rotation to the opposite side) and rotation. In rotation of the head the atlas rotates around the dens of the axis, and in flexion of the head the occipital condyles move on the articular facets of the atlas.

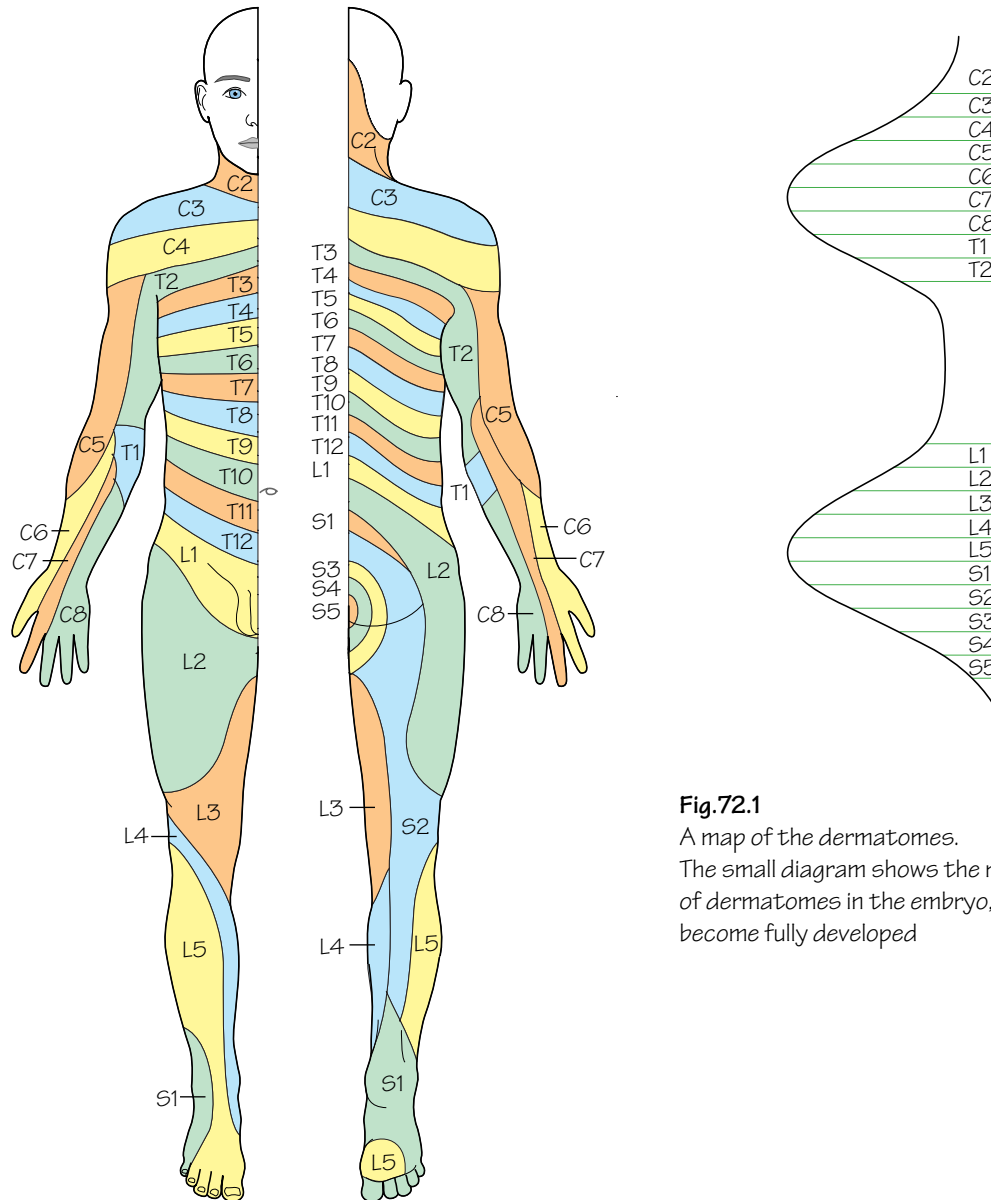
- **Thoracic spine:** movement is somewhat restricted by the thinner intervertebral discs and the presence of the ribs. Rotation, however, is free.

- **Lumbar spine:** flexion and extension are free but rotation is almost absent because of the direction of the articular facets. Side flexion also occurs.

### Spina bifida

*Each vertebra develops in three parts—the body and the two halves of the neural arch. These ossify in cartilage and, at birth, the three parts are still separate but they soon fuse. Failure of such fusion gives rise to the condition of spina bifida. This may be symptomless (spina bifida occulta) although the site of the lesion may be marked by a tuft of hair. If the defect is large, the meninges or even the spinal cord may herniate onto the surface (meningocoele) and this may produce neurological symptoms.*

## 72 The spinal cord



**Fig.72.1**

A map of the dermatomes.

The small diagram shows the regular arrangement of dermatomes in the embryo, before the limbs become fully developed

In the fetus, the spine and the spinal cord are the same length but, since the spine grows more quickly than the spinal cord, the lower end of the cord gradually retreats upwards, reaching the level of L3 at birth and the lower border of L1 in the adult. For this reason, too, the anterior and posterior nerve roots become more and more oblique from above downwards so the lumbar and sacral nerve roots form a bundle, the *cauda equina*, which occupies the lower part of the spinal canal. The posterior root ganglia occupy the intervertebral foramina so that the roots do not unite until after this point. The spinal cord itself ends as the *filum terminale*, a thin fibrous band which is included in the cauda equina.

The spinal cord shows two enlargements in the cervical and lumbar regions, corresponding to the origins of the nerves that make up the limb plexuses. It is for this reason that the vertebral canal is larger in these regions, and they are also the regions of the greatest mobility.

- **The meninges:** the meninges—the *dura*, *pia* and *arachnoid*—are continuous with those of the cranial cavity so that the *subarachnoid space* is also continuous and cerebrospinal fluid may be drained from the system or its pressure measured, by *lumbar puncture*. The subarachnoid space ends at the level of S2.

- **The blood supply of the spinal cord:** the spinal cord is supplied with blood by *spinal arteries* that are derived from the *vertebral, intercostal, lumbar* and *lateral sacral arteries*. Each artery divides into *dorsal* and *ventral* branches that follow the corresponding nerve roots to the spinal cord where they form longitudinally arranged *anterior* and paired *posterior spinal arteries*. These longitudinal anastomoses, however, are incomplete and the spinal arteries themselves vary in size. The largest are in the lower thoracic and upper lumbar regions, and the blood supply of the cord may be jeopardized if some of these larger spinal arteries are damaged, for example in resection of the thoracic aorta.

### The spinal nerves

As has been described in Chapter 2, the spinal nerves from T2 to L1 supply segmental areas of skin and muscles but elsewhere they form plexuses so that the areas supplied by each nerve become more complicated. Each named *peripheral nerve* may contain components of more than one *spinal nerve* and each *spinal nerve* may contribute fibres to

more than one *peripheral nerve*. However, the area of skin supplied by any one spinal nerve (a *dermatome*) can be mapped out and these are shown in Fig. 72.1. Knowledge of the dermatome map is of great value in diagnosing lesions of the spinal nerves but it must be remembered that these areas are subject to some variation from one person to another and there is also a good deal of overlap. Thus a lesion of, say, T4 may cause little or no loss of sensation because of overlap with T3 and T5.

Similarly, certain groups of muscles (*myotomes*) can be recognized as being supplied by particular spinal nerves. For example, C5 supplies the abductors of the shoulder, the flexors of the elbow and the supinators so that a lesion of this nerve or of the upper trunk of the brachial plexus will cause the arm to be held in a position of adduction of the shoulder, extension of the elbow and pronation (*Erb–Duchenne paralysis*). Similarly, T1 supplies the small muscles of the hand so that a lesion of this nerve, due perhaps to the presence of a cervical rib, will cause global wasting of the hand muscles.



# Muscle index

## The abdomen

All the muscles of the *anterior abdominal wall* serve to protect the viscera by their contraction, to produce movement and to increase the intra-abdominal pressure, as in defecation, coughing, parturition, etc. All these muscles are supplied by the **lower six thoracic** and the **first lumbar nerves**.

### • External oblique

*Origin:* From the outer surfaces of the lower eight ribs to the iliac crest as far forward as the anterior superior spine.

*Insertion:* The free lower border forms the *inguinal ligament* between the anterior superior iliac spine and the pubic tubercle. The muscle becomes aponeurotic and reaches the midline where it interdigitates with the opposite side to form the *linea alba*. The *superficial inguinal ring* is a gap in the aponeurosis above and medial to the pubic tubercle. The aponeurosis contributes to the *anterior rectus sheath*.

*Actions:* Flexion of the spine, side flexion and rotation of the trunk—the *right* external oblique produces rotation to the *left*.

### • Internal oblique

*Origin:* From the thoracolumbar fascia, the iliac crest and the lateral half of the inguinal ligament.

*Insertion:* Into an aponeurosis which is attached to the costal margin and to the linea aspera, after splitting to enclose the rectus abdominis, thus contributing to the rectus sheath. The lower fibres from the inguinal ligament contribute to the *conjunct tendon* which is attached to the pubic crest and the pectineal line.

*Actions:* Flexion of the spine, side flexion and rotation of the trunk—the *right* internal oblique produces rotation to the *right*.

### • Transversus abdominis

*Origin:* From the thoracolumbar fascia, the iliac crest and the lateral one third of the inguinal ligament. Also from the *inner* surfaces of the lower six ribs, interdigitating with the diaphragm.

*Insertion:* The aponeurosis passes to the linea aspera, contributing to the rectus sheath. The lower fibres help to form the conjunct tendon.

*Actions:* Most of the fibres are transverse and thus pull in and flatten the abdominal wall.

### • Rectus abdominis

*Origin:* From the anterior surfaces of the 5th, 6th and 7th costal cartilages.

*Insertion:* The pubic crest and tubercle and the front of the symphysis. There are three tendinous intersections in the upper part of the muscle which are adherent to the anterior rectus sheath.

*Actions:* The muscle is enclosed in the rectus sheath. A strong flexor of the trunk, it can also tilt the pelvis backwards. In a person lying prone, rectus contracts when the head is lifted from the pillow or when the leg is raised from the bed.

For further important details of the muscles of the anterior abdominal wall, see the *inguinal canal* and the *rectus sheath* (p. 30).

### • The diaphragm

*Origin:* From the inner surfaces of the lower six ribs, from the back of the xiphisternum, from the right and left crura which are attached, respectively, to the upper three and the upper two lumbar vertebrae, and from the medial and lateral arcuate ligaments which bridge over the psoas major and quadratus lumborum.

*Insertion:* The fibres (striated muscle) are inserted into the central tendon.

*Actions:* The diaphragm is involved in respiration. When the muscle fibres contract, the diaphragm is lowered, thus increasing the vertical dimension of the thorax. In the later stages of contraction, using the liver as a fulcrum it raises the lower ribs, thus increasing the width of the lower thorax. At the same time, it increases the intra-abdominal pressure and is thus used in expulsive efforts—defecation, micturition, parturition, etc.

*Nerve supply:* Phrenic nerve (C3, 4 and 5).

### • Quadratus lumborum

*Origin:* From the posterior part of the iliac crest.

*Insertion:* To the 12th rib.

*Action:* Side flexion of the trunk.

*Nerve supply:* Adjacent lumbar nerves.

• **Psoas major:** see lower limb (p. 165).

## The upper limb

### • Latissimus dorsi

*Origin:* From the spines of the lower six thoracic vertebrae, the lumbar spines via the thoracolumbar fascia and the medial part of the iliac crest.

*Insertion:* To the floor of the intertubercular sulcus, curving round *teres major*.

*Actions:* Adduction and medial rotation of the arm. Can hold up the lower limb girdle as in crutch walking.

*Nerve supply:* Thoracodorsal nerve.

### • Serratus anterior

*Origin:* From the lateral surfaces of the upper eight ribs.

*Insertion:* Into the medial border of the scapula.

*Actions:* Protraction of the scapula and rotation so that the glenoid points upwards, thus helping in abduction of the upper limb. Helps to keep the scapula in contact with the chest wall.

*Nerve supply:* Long thoracic nerve.

### • Levator scapulae

*Origin:* From the transverse processes of the upper cervical vertebrae.

*Insertion:* To the medial border of the scapula above the spine.

*Action:* Elevates the scapula.

*Nerve supply:* C3 and 4.

### • The rhomboids

*Origin:* From spines of thoracic vertebrae.

*Insertion:* To the medial border of the scapula.

*Action:* Bracing back the scapula.

*Nerve supply:* Dorsal scapular nerve.

• **Trapezius:** See p. 167.

### • Pectoralis major

*Origin:* From the sternum and the upper six costal cartilages and from the medial half of the clavicle.

*Insertion:* To the lateral lip of the intertubercular sulcus.

*Actions:* Adduction, flexion and medial rotation of the arm.

*Nerve supply:* Medial and lateral pectoral nerves.

### • Pectoralis minor

*Origin:* From the 3rd, 4th and 5th ribs.

*Insertion:* To the coracoid process.

*Action:* Depresses the tip of the shoulder.

*Nerve supply:* Medial and lateral pectoral nerves.

- **Deltoid**

*Origin:* From the lateral third of the clavicle, the acromion and the spine of the scapula.

*Insertion:* To the deltoid tubercle on the lateral surface of the humerus.

*Actions:* Abduction of the upper limb (assisted by supraspinatus and serratus anterior), flexion (anterior fibres) and extension (posterior fibres) of the arm.

*Nerve supply:* Axillary nerve.

- **Teres major**

*Origin:* From the lower angle of the scapula.

*Insertion:* To the medial lip of the intertubercular sulcus.

*Actions:* Adduction and medial rotation of the arm.

*Nerve supply:* Lower subscapular nerve.

- **The rotator cuff**

Consists of **subscapularis**, **supraspinatus**, **infraspinatus** and **teres minor**. Acting together, these muscles maintain the stability of the shoulder joint as well as having their own individual actions, as follows:

- **Subscapularis**

*Origin:* From the subscapular fossa.

*Insertion:* Passes in front of the shoulder joint to the lesser tuberosity of the humerus.

*Action:* Medial rotation of the arm.

*Nerve supply:* Subscapular nerves.

- **Supraspinatus**

*Origin:* From the supraspinous fossa.

*Insertion:* To the top of the greater tuberosity of the humerus.

*Action:* Initiates abduction of the arm.

*Nerve supply:* Suprascapular nerve.

- **Infraspinatus**

*Origin:* From the infraspinous fossa.

*Insertion:* To the back of the greater tuberosity.

*Action:* Lateral rotation of the arm.

*Nerve supply:* Suprascapular nerve.

- **Teres minor**

*Origin:* From the lateral border of the scapula.

*Insertion:* To the humerus below infraspinatus.

*Action:* Lateral rotation of the arm.

*Nerve supply:* Axillary nerve.

- **Coracobrachialis**

*Origin:* From the coracoid process along with the short head of biceps.

*Insertion:* To the medial side of the humerus.

*Action:* Moves the arm upwards and medially.

*Nerve supply:* Musculocutaneous nerve.

- **Biceps brachii**

*Origin:* Long head from the supraglenoid tubercle and short head from the coracoid process (with coracobrachialis).

*Insertion:* To the radial tuberosity and, via the bicipital aponeurosis, into the deep fascia of the forearm.

*Actions:* Flexion and supination of the forearm.

*Nerve supply:* Musculocutaneous nerve.

- **Brachialis**

*Origin:* From the front of the lower part of the humerus.

*Insertion:* To the tubercle on the ulna just below the coronoid process.

*Action:* Flexion of the elbow.

*Nerve supply:* Musculocutaneous nerve and radial nerve.

- **Triceps**

*Origin:* Three heads: long from the infraglenoid tubercle, lateral from the humerus above the spiral line, and medial from the back of the lower part of the humerus.

*Insertion:* Into the olecranon.

*Action:* Extensor of the elbow.

*Nerve supply:* Radial nerve.

- **Pronator teres**

*Origin:* From the common flexor origin on the medial epicondyle of the humerus.

*Insertion:* To the lateral surface of the shaft of the radius.

*Action:* Pronation of the forearm.

*Nerve supply:* Median nerve.

- **Flexor carpi radialis**

*Origin:* From the common flexor origin.

*Insertion:* To the base of metacarpals 2 and 3.

*Actions:* Flexion and abduction of wrist.

*Nerve supply:* Median nerve.

- **Palmaris longus**

*Origin:* From the common flexor origin.

*Insertion:* To the flexor retinaculum and the palmar aponeurosis.

*Action:* Flexor of the wrist. (Often absent.)

*Nerve supply:* Median nerve.

- **Flexor carpi ulnaris**

*Origin:* From the common flexor origin and the posterior border of the ulna.

*Insertion:* To the pisiform and thence by the pisometacarpal ligament to the 5th metacarpal.

*Actions:* Flexion and adduction of the wrist.

*Nerve supply:* Ulnar nerve.

- **Flexor digitorum superficialis**

*Origin:* From the common flexor origin and the shaft of the radius.

*Insertion:* To the sides of the middle phalanges of the four fingers. The tendons are perforated by the tendons of flexor digitorum profundus.

*Actions:* Flexion of the proximal two phalanges and of the wrist.

*Nerve supply:* Median nerve.

- **Flexor pollicis longus**

*Origin:* From the front of the shaft of the radius.

*Insertion:* To the distal phalanx of the thumb.

*Actions:* Flexion of all the joints of the thumb.

*Nerve supply:* Median nerve.

- **Flexor digitorum profundus**

*Origin:* From the front of the shaft of the ulna and its posterior border.

*Insertion:* To the distal phalanges of the four fingers, the tendons passing through those of flexor digitorum superficialis.

*Actions:* Flexion of the fingers and the wrist.

*Nerve supply:* Half by the median nerve and half by the ulnar nerve.

- **Pronator quadratus**

*Origin:* From the lower end of the front of the radius.

*Insertion:* To the lower end of the ulna.

*Action:* Pronator of the forearm.

*Nerve supply:* Median nerve.

- **Brachioradialis**

*Origin:* From the lateral supracondylar ridge of the humerus.

*Insertion:* To the lower end of the radius.

*Action:* Flexion of the elbow.

*Nerve supply:* Radial nerve.

- **Extensor carpi radialis longus and brevis**

*Origin:* From the lateral supracondylar ridge of the humerus.

*Insertion:* To the bases of the 2nd and 3rd metacarpals.

*Actions:* Extension and abduction of the wrist.

*Nerve supply:* Radial nerve.

- **Extensor digitorum**

*Origin:* From the common extensor origin on the lateral epicondyle of the humerus.

*Insertion:* To the bases of the middle and distal phalanges of the four fingers via the extensor expansion.

*Actions:* Extension of the fingers and of the wrist (but see also the lumbricals and interossei).

*Nerve supply:* Radial (posterior interosseous) nerve.

- **Extensor digiti minimi**

*Origin:* From the common extensor origin.

*Insertion:* To the extensor expansion of the little finger.

*Action:* Extension of the little finger.

*Nerve supply:* Radial (posterior interosseous) nerve.

- **Extensor carpi ulnaris**

*Origin:* From the common extensor origin and from the posterior border of the ulna.

*Insertion:* To the base of the 5th metacarpal.

*Actions:* Extension and adduction of the wrist.

*Nerve supply:* Radial (posterior interosseous) nerve.

- **Supinator**

*Origin:* From the lateral side of the humerus and the ulna.

*Insertion:* It wraps around the radius from behind to be inserted into the upper part of its shaft.

*Action:* Supination.

*Nerve supply:* Radial (posterior interosseous) nerve.

- **Abductor pollicis longus**

*Origin:* From the posterior surfaces of the radius and ulna.

*Insertion:* To the base of the 1st metacarpal.

*Actions:* Abduction and extension of the thumb.

*Nerve supply:* Radial (posterior interosseous) nerve.

- **Extensor pollicis brevis**

*Origin:* From the back of the radius.

*Insertion:* To the base of the proximal phalanx of the thumb.

*Action:* Extension of the proximal phalanx of the thumb.

*Nerve supply:* Radial (posterior interosseous) nerve.

- **Extensor pollicis longus**

*Origin:* From the back of the ulna.

*Insertion:* Into the base of the distal phalanx of the thumb.

*Actions:* Extension of all the joints of the thumb.

*Nerve supply:* Radial (posterior interosseous) nerve.

- **Extensor indicis**

*Origin:* From the back of the ulna.

*Insertion:* To the side of the extensor digitorum tendon to the index finger.

*Action:* Helps to extend the index finger.

*Nerve supply:* Radial (posterior interosseous) nerve.

- **Abductor pollicis brevis**

*Origin:* From the flexor retinaculum and adjacent carpal bones.

*Insertion:* To the base of the proximal phalanx of the thumb.

*Action:* Abduction of the thumb.

*Nerve supply:* Median nerve.

- **Flexor pollicis brevis**

*Origin:* From the flexor retinaculum and adjacent carpal bones.

*Insertion:* To the base of the proximal phalanx of the thumb. Its tendon contains a sesamoid bone.

*Action:* Flexion of the proximal phalanx of the thumb.

*Nerve supply:* Median nerve.

- **Opponens pollicis**

*Origin:* From the flexor retinaculum and adjacent carpal bones.

*Insertion:* To the shaft of the 1st metacarpal.

*Action:* Produces opposition of the thumb.

*Nerve supply:* Median nerve.

- **Adductor pollicis**

*Origin:* *Oblique head* from the bases of metacarpals; *transverse head* from the shaft of the 3rd metacarpal.

*Insertion:* To the base of the medial side of the proximal phalanx of the thumb. The tendon contains a sesamoid bone.

*Action:* Adduction of the thumb.

*Nerve supply:* Deep branch of the ulnar nerve.

- **Abductor digiti minimi**

*Origin:* From the pisiform bone.

*Insertion:* To the base of the proximal phalanx of the little finger.

*Action:* Abduction of the little finger.

*Nerve supply:* Ulnar nerve.

- **Flexor digiti minimi**

*Origin:* From the flexor retinaculum and adjacent carpal bone.

*Insertion:* To the base of the proximal phalanx of the little finger.

*Action:* Flexes the proximal phalanx of the little finger.

*Nerve supply:* Ulnar nerve.

- **Opponens digiti minimi**

*Origin:* From the flexor retinaculum and adjacent carpal bones.

*Insertion:* To the shaft of the fifth metacarpal.

*Action:* Opposition of the little finger.

*Nerve supply:* Ulnar nerve.

- **The lumbrical muscles**

*Origins:* The four muscles arise from the sides of the tendons of the flexor digitorum profundus.

*Insertions:* To the lateral sides of the dorsal extensor expansions of the extensor digitorum tendon.

*Actions:* Flexion of the metacarpophalangeal joints and extension of the interphalangeal joints.

*Nerve supply:* Medial two muscles by the ulnar nerve and lateral two by the median nerve.

- **The interossei**

*Origins:* *Dorsal* from adjacent sides of four metacarpals and *palmar* from one side of each metacarpal.

*Insertions:* Both dorsal and palmar are inserted into the sides of the proximal phalanges and the dorsal extensor expansions in such a way that the dorsal interossei abduct the fingers and the palmar adduct them (Fig. 39.2).

*Actions:* Adduction and abduction as above. Both sets of muscles produce flexion of the metacarpophalangeal joints and extension of the interphalangeal joints, as in the 'precision grip'.

*Nerve supply:* All by the deep branch of the ulnar nerve.

## The lower limb

- **Gluteus maximus**

*Origin:* From the posterior part of the gluteal surface of the ilium, the back of the sacrum and its associated ligaments.

*Insertion:* To the gluteal tuberosity of the femur (25%) and the ilio-tibial tract (75%).

*Actions:* Extension and lateral rotation of the thigh.

*Nerve supply:* Inferior gluteal nerve.

- **Gluteus medius**

*Origin:* From the gluteal surface of the ilium.

*Insertion:* To the greater trochanter.

*Actions:* Abduction and medial rotation of the thigh.

*Nerve supply:* Superior gluteal nerve.

- **Gluteus minimus**

*Origin:* From the gluteal surface of the ilium below gluteus medius.

*Insertion:* To the greater trochanter.

*Actions:* Abduction and medial rotation of the thigh. The most important action of medius and minimus is to prevent the pelvis tilting to the unsupported side when taking the weight on one leg, as in walking.

*Nerve supply:* Superior gluteal nerve.

- **Tensor fasciae latae**

*Origin:* From the anterior part of the crest of the ilium.

*Insertion:* To the lateral condyle of the tibia via the iliotibial tract.

*Actions:* Extension of the knee joint. Helps the gluteal muscles to prevent tilting of the pelvis.

*Nerve supply:* Superior gluteal nerve.

- **Piriformis**

*Origin:* From the front of the sacrum.

*Insertion:* Into the greater trochanter via the greater sciatic notch.

*Action:* Lateral rotation of the thigh.

*Nerve supply:* From the sacral plexus.

- **Obturator internus**

*Origin:* From the inner surface of the hip bone and the obturator membrane.

*Insertion:* To the greater trochanter via the lesser sciatic notch.

*Action:* Lateral rotation of the thigh.

*Nerve supply:* From the sacral plexus.

- **Quadratus femoris**

*Origin:* From the outer surface of the ischial tuberosity.

*Insertion:* To the quadrate tubercle on the intertrochanteric crest of the femur.

*Action:* Lateral rotation of the thigh.

*Nerve supply:* From the sacral plexus.

- **Obturator externus**

*Origin:* From the obturator membrane and the surrounding bone.

*Insertion:* To the trochanteric fossa of the femur.

*Action:* Lateral rotation of the thigh.

*Nerve supply:* Obturator nerve.

- **Iliacus**

*Origin:* From the concave inner surface of the ilium.

*Insertion:* Passes under the inguinal ligament to the lesser trochanter, in company with psoas major.

*Action:* Flexion of the thigh.

*Nerve supply:* Femoral nerve.

- **Psoas major**

*Origin:* From the transverse processes and the sides of the bodies and intervertebral discs of the lumbar vertebrae.

*Insertion:* Passes under the inguinal ligament to the lesser trochanter in company with iliacus. (Joint muscle often called *iliopsoas*.)

*Action:* Flexion of the thigh.

*Nerve supply:* Femoral nerve.

- **Sartorius**

*Origin:* From the anterior superior iliac spine.

*Insertion:* To the medial side of the upper end of the tibia just in front of gracilis and semitendinosus.

*Actions:* Flexion and abduction of the thigh and flexion of the knee (the 'tailor's position').

*Nerve supply:* Femoral nerve.

- **Quadriceps femoris:**

- **Rectus femoris**

*Origin:* From the anterior inferior iliac spine (*straight head*) and the upper lip of the acetabulum (*reflected head*).

- **Vastus medialis**

*Origin:* From the medial lip of the linea aspera.

- **Vastus lateralis**

*Origin:* From the lateral lip of the linea aspera.

- **Vastus intermedius**

*Origin:* From the lateral and anterior surfaces of the femur.

*Insertion of quadriceps:* The four parts of quadriceps are inserted into the patella and, from here, to the tubercle of the tibia. The patella is thus a *sesamoid bone* in the tendon of quadriceps.

*Actions:* Extension and stabilization of the knee. Rectus is also a weak flexor of the thigh.

*Nerve supply:* Femoral nerve.

- **Pectineus**

*Origin:* From the superior ramus of the pubis.

*Insertion:* To the back of the femur between the lesser trochanter and the linea aspera.

*Actions:* Adduction and flexion of the thigh.

*Nerve supply:* Femoral and obturator nerves.

- **Adductor longus**

*Origin:* From the front of the pubis just below the pubic tubercle.

*Insertion:* To the middle third of the linea aspera.

*Action:* Adduction of the thigh.

*Nerve supply:* Obturator nerve.

- **Adductor brevis**

*Origin:* From the inferior ramus of the pubis.

*Insertion:* To the upper part of the linea aspera.

*Action:* Adduction of the thigh.

*Nerve supply:* Obturator nerve.

- **Adductor magnus**

*Origin:* From the inferior ramus of the pubis and the ramus of the ischium, back as far as the ischial tuberosity.

*Insertion:* To the whole length of the linea aspera and to the adductor tubercle of the femur.

*Actions:* Adduction and extension of the thigh (the latter action is carried out by the 'hamstring' part of the muscle which arises from the ischial tuberosity).

*Nerve supply:* Adductor part by the femoral nerve and hamstring part by the sciatic nerve.

- **Gracilis**

*Origin:* From the inferior ramus of the pubis and the ramus of the ischium.

*Insertion:* To the medial side of the tibia between sartorius and semitendinosus.

*Action:* Adduction of the thigh.

*Nerve supply:* Obturator nerve.

- **Biceps femoris**

*Origin:* Long head from the ischial tuberosity and short head from the linea aspera.

*Insertion:* By a thick tendon into the head of the fibula.

*Actions:* Extension of the hip and flexion of the knee.

*Nerve supply:* Sciatic nerve (both components).

- **Semitendinosus**

*Origin:* From the ischial tuberosity.

*Insertion:* To the medial side of the front of the tibia, behind sartorius and gracilis.

*Actions:* Extension of the hip and flexion of the knee joint.



*Nerve supply:* Sciatic nerve (tibial component).

- **Semimembranosus**

*Origin:* From the ischial tuberosity.

*Insertion:* To a groove on the tibial medial condyle.

*Actions:* Extension of the hip and flexion of the knee.

*Nerve supply:* Sciatic nerve (tibial component).

- **Tibialis anterior**

*Origin:* From the lateral surface of the tibia.

*Insertion:* To the base of the 1st metatarsal and the medial cuneiform.

*Actions:* Dorsiflexion and inversion of the foot.

*Nerve supply:* Deep peroneal nerve.

- **Extensor hallucis longus**

*Origin:* From the middle third of the shaft of the fibula.

*Insertion:* To the base of the distal phalanx of the big toe.

*Actions:* Extension of the big toe and dorsiflexion of the foot.

*Nerve supply:* Deep peroneal nerve.

- **Extensor digitorum longus**

*Origin:* From the shaft of the fibula.

*Insertion:* To the bases of the middle and distal phalanges of the four lateral toes via the dorsal extensor expansions.

*Actions:* Extension of the toes and dorsiflexion of the foot.

*Nerve supply:* Deep peroneal nerve.

- **Peroneus tertius**

*Origin:* Formed by the lower part of extensor digitorum longus.

*Insertion:* Into the base of the 5th metatarsal.

*Action:* Dorsiflexion of the foot.

*Nerve supply:* Deep peroneal nerve.

- **Extensor digitorum brevis**

*Origin:* From the upper surface of the calcaneus.

*Insertion:* To the proximal phalanx of the big toe and to the extensor digitorum longus tendons of the next three toes.

*Actions:* Dorsiflexion of the foot and extension of the toes.

*Nerve supply:* Deep peroneal nerve.

- **Peroneus longus**

*Origin:* From the upper two-thirds of the lateral surface of the shaft of the fibula.

*Insertion:* To the base of the 1st metatarsal and the medial cuneiform, via the groove on the cuboid.

*Action:* Eversion of the foot.

*Nerve supply:* Superficial peroneal nerve.

- **Peroneus brevis**

*Origin:* From the lower two-thirds of the shaft of the fibula.

*Insertion:* To the base of the 5th metatarsal.

*Action:* Eversion of the foot.

*Nerve supply:* Superficial peroneal nerve.

- **Gastrocnemius**

*Origin:* From the femur just above both femoral condyles.

*Insertion:* To the middle third of the back of the calcaneus via the tendo calcaneus.

*Actions:* Plantar flexion of the foot; weak flexion of the knee.

*Nerve supply:* Tibial nerve.

- **Soleus**

*Origin:* From the soleal line of the tibia and the upper part of the back of the fibula.

*Insertion:* To the middle third of the back of the calcaneus via the tendo calcaneus in common with the gastrocnemius.

*Actions:* Plantar flexion of the foot. Is the main factor in the 'muscle pump'.

*Nerve supply:* Tibial nerve.

- **Plantaris**

A detached piece of the lateral head of gastrocnemius with similar properties.

- **Popliteus**

*Origin:* From the back of the tibia above the soleal line.

*Insertion:* To the lateral condyle of the femur.

*Actions:* Flexion and medial rotation of the leg (thus 'unlocking' the extended knee joint).

*Nerve supply:* Tibial nerve.

- **Tibialis posterior**

*Origin:* From the back of the tibia and fibula.

*Insertion:* To the tuberosity of the navicular and other tarsal bones.

*Actions:* Plantar flexion and inversion of the foot.

*Nerve supply:* Tibial nerve.

- **Flexor hallucis longus**

*Origin:* From the back of the fibula.

*Insertion:* To the base of the distal phalanx of the big toe.

*Action:* Flexion of the big toe.

*Nerve supply:* Tibial nerve.

- **Flexor digitorum longus**

*Origin:* From the back of the tibia.

*Insertion:* To the bases of the distal phalanges of the four lateral toes via the openings in the tendons of flexor digitorum brevis.

*Action:* Flexion of the toes.

*Nerve supply:* Tibial nerve.

- **Abductor hallucis**

*Origin:* From the calcaneal tuberosity.

*Insertion:* To the medial side of the proximal phalanx of the big toe.

*Action:* Abduction of the big toe.

*Nerve supply:* Medial plantar nerve.

- **Flexor digitorum brevis**

*Origin:* From the calcaneal tuberosity.

*Insertion:* To the sides of the middle phalanges of the lateral four toes, its tendons being perforated by those of flexor digitorum longus.

*Action:* Flexion of the toes.

*Nerve supply:* Medial plantar nerve.

- **Abductor digiti minimi**

*Origin:* From the calcaneal tuberosity.

*Insertion:* To the proximal phalanx of the little toe.

*Actions:* Flexion and abduction of the little toe.

*Nerve supply:* Lateral plantar nerve.

- **Lumbricals**

*Origin:* From the tendons of flexor digitorum longus.

*Insertion:* To the dorsal extensor expansions.

*Actions:* Assist the actions of the interossei.

*Nerve supply:* First lumbrical by the medial and the others by the lateral plantar nerves.

- **Flexor digitorum accessorius**

*Origin:* From the undersurface of the calcaneus.

*Insertion:* Into the side of the tendon of flexor digitorum longus.

*Action:* Tenses the tendon of this muscle.

*Nerve supply:* Lateral plantar nerve.

- **Flexor hallucis brevis**

*Origin:* From the underside of the cuboid.

*Insertion:* To the sides of the proximal phalanx of the big toe with a sesamoid bone in each tendon.

*Action:* Flexion of the proximal phalanx of the big toe.

*Nerve supply:* Medial plantar nerve.

- **Adductor hallucis**

*Origin:* From the heads and from the bases of the metatarsals.

*Insertion:* Into the lateral side of the proximal phalanx of the big toe.

*Action:* Adduction of the big toe.

*Nerve supply:* Lateral plantar nerve.

- **Flexor digiti minimi brevis**

*Origin:* From the base of the 5th metatarsal.

*Insertion:* Into the proximal phalanx of the little toe.

*Action:* Flexion of the little toe.

*Nerve supply:* Lateral plantar nerve.

- **Interossei:**

- **Dorsal**

*Origin:* From adjacent sides of the metatarsals.

*Insertion:* Into the dorsal extensor expansions and the sides of the proximal phalanges.

*Actions:* Abduction of the toes; flexion of the metatarsophalangeal joints and extension of the interphalangeal joints.

*Nerve supply:* Lateral plantar nerve.

- **Plantar**

*Origin:* From the bases of three of the metatarsals.

*Insertion:* Into the dorsal extensor expansions and the sides of the proximal phalanges.

*Actions:* Adduction of the toes and assisting the other actions of the dorsal interossei.

*Nerve supply:* Lateral plantar nerve.

## The head and neck

### The muscles of mastication

- **Temporalis**

*Origin:* From the lateral side of the skull below the temporal line.

*Insertion:* To the coronoid process of the mandible, extending down the anterior border as far as the third molar tooth. It passes deep to the zygomatic arch.

*Actions:* Closes the mouth and clenches the teeth. The posterior fibres are horizontal and help to retract the mandible when closing the mouth.

- **Masseter**

*Origin:* From the lower border of the zygomatic arch.

*Insertion:* To the lateral side of the mandible in the region of the angle.

*Actions:* Closes the mouth and clenches the teeth.

- **Lateral pterygoid**

*Origin:* From the lateral pterygoid plate.

*Insertion:* To the neck of the mandible and the intra-articular disc of the temporomandibular joint.

*Actions:* It protrudes the mandible and moves the head of the mandible onto the articular eminence when the mouth is opened.

- **Medial pterygoid**

*Origin:* From the lateral pterygoid plate.

*Insertion:* To the medial surface of the mandible near the angle.

*Action:* Helps to close the mouth.

*Nerve supply of the muscles of mastication:* The muscles of mastication are all supplied by the mandibular division of the **trigeminal nerve**.

### The muscles of facial expression

The principal muscles of facial expression are shown in Fig. 67.1, from which their actions can be deduced. Only a few of them will be described here.

- **Occipitofrontalis**

*Origin:* The *frontal belly* extends backwards from the forehead region and the *occipital belly* extends forwards from the occipital bone.

*Insertion:* Both parts are inserted into the galea aponeurotica (epicranial aponeurosis).

*Actions:* The frontal belly lifts the eyebrows when looking upwards and both bellies can move the whole scalp on the underlying loose fascia.

- **Orbicularis oculi**

In two parts. The orbital part surrounds the whole eye, blending with the frontal belly of occipitofrontalis. It closes the eye tightly. The palpebral part is in the eyelid and closes the eye gently as in sleep.

- **Orbicularis oris**

Surrounds the whole mouth and blends in with the surrounding muscles that are shown in Fig. 67.1. Closes the mouth and protrudes the lips.

- **Buccinator**

*Origin:* From the pterygomandibular ligament, where it is continuous with the superior constrictor of the pharynx.

*Insertion:* Blends in with the orbicularis oris. Tightens the cheeks and keeps them in contact with the gums, thus preventing food collecting in the vestibule of the mouth.

- **Platysma**

*Origin:* From the skin over the upper part of the chest, crossing the mandible to blend in with the orbicularis oris. Pulls down the corners of the mouth and has an antisphincteric action on the neck as in loosening a tight collar.

*Nerve supply of the muscles of facial expression:* All the muscles of facial expression are supplied by the **facial nerve**.

- **Trapezius**

*Origin:* From the superior nuchal line, the ligamentum nuchae and the spines of all the thoracic vertebrae.

*Insertion:* Into the spine of the scapula, the lateral edge of the acromion and the lateral third of the clavicle.

*Actions:* Extends the head on looking upwards, raises the tips of the shoulders, braces the shoulders back, and helps serratus anterior to rotate the scapula during abduction of the arm.

*Nerve supply:* Spinal accessory nerve.

- **Sternocleidomastoid**

*Origin:* From the front of the manubrium (by a narrow rounded tendon) and the medial third of the clavicle.

*Insertion:* To the mastoid process and the lateral part of the superior nuchal line.

*Actions:* Rotates the head to the opposite side and flexes the cervical spine to the same side, thus bringing the ear nearer to the shoulder of the same side. Both muscles acting together can flex the cervical spine against resistance. An accessory muscle of respiration.

*Nerve supply:* Spinal accessory nerve.

- **Scalenus anterior**

*Origin:* From anterior tubercles of the transverse processes of several cervical vertebrae.

*Insertion:* To the scalene tubercle on the medial border of the 1st rib, by means of a narrow pointed tendon.

*Actions:* Flexes the cervical spine, produces lateral flexion to the same side and rotation to the opposite side. An accessory muscle of respiration.

*Nerve supply:* Cervical spinal nerves.

- **Scalenus medius**

*Origin:* From the posterior tubercles of the transverse processes of most of the cervical vertebrae.

*Insertion:* Into a large area on the 1st rib behind scalenus anterior.

*Actions:* Similar to those of scalenus anterior.

*Nerve supply:* Cervical spinal nerves.

- **Other muscles**

Other muscles of the neck, such as the strap muscles, are described fully in the text.



# Index

The index is arranged in word-by-word sequence; page numbers in italics refer to figures.

- abdomen
  - arteries, 31–3
  - lymphatics, 34–5
  - muscles, 162
  - nerves, 50–1
  - surface anatomy, 52–3
  - veins, 34–5
- abdominal
  - aorta, 31, 32
  - oesophagus, 39
  - viscera, surface markings, 53
- abdominal wall, 28–30
  - lymphatic drainage, 30, 35
  - surface markings, 53
- abducent nerve, 126, 131, 155
- abductor
  - digiti minimi, 89, 117, 166
  - hallucis, 117, 166
  - pollicis, 89
  - pollicis brevis, 89, 164
  - pollicis longus, 164
- accessory
  - duct (of Santorini), 47
  - hemiazzygos vein, 13
  - muscles of respiration, 17
  - nerve, 130, 131
    - cranial root, 121
    - spinal root, 137, 145
- acetabular notch, 102
- acetabulum, 93, 102
- Achilles tendon, 113, 115, 119
- acromioclavicular joint, 62, 75
- acromion process, 91
- action potential, heart, 22
- acute cholecystitis, 45
- acute pancreatitis, 47
- adductor
  - brevis, 108, 165
  - canal, 95, 107, 108
  - digiti minimi, 164
  - hallucis, 166–7
  - longus, 108, 165
  - magnus, 108, 165
  - muscles, 105, 106
  - pollicis, 164
  - tubercle, 93, 119
- adenocarcinomas, oesophagus, 11
- adenoid, 139, 147
- aditus (middle ear), 157
- adrenal glands, 49
- airways, 14–15
- Alcock's canal, 59
- ampulla
  - of rectum, 43
  - of Vater, 47
- anal
  - canal, 43, 59
  - sphincter, 42, 59
- anastomoses, porto-systemic, 34, 35
- anatomical snuffbox, 65, 67, 86, 87, 90, 91
- anatomical spaces, 75
- anconeus, 83
- angina, 23
- angiograms
  - carotid, 132
  - vertebral, 134
- angioplasty, 23
- angle of Louis, 27
- angular incisure, 39
- anhidrosis, 121
- ankle, 92, 114–17, 118
  - joint, 114, 115
  - surface anatomy, 119
- annular ligament, 83
- annulus fibrosus, 159
- anorectal ring, 59
- ansa cervicalis, 131
- anterior
  - abdominal wall, 30, 37, 162
  - cerebral artery, 133
  - chest wall, 9
  - clinoid processes, 123
  - cranial fossae, 123
  - cruciate ligament, 111
  - cutaneous nerve, 127
  - gluteal line, 55
  - inferior cerebellar artery, 135
  - inferior iliac spine, 102
  - intercostal artery, 9
  - intercostal spaces, 9
  - intercostal veins, 9
  - interosseous artery, 67
  - interosseous branch, 71, 85
  - jugular vein, 135
  - longitudinal ligaments, 159
  - mediastinum, 11
  - notch (spleen), 53
  - pillars of the fauces, 146
  - rectus sheath, 162
  - sacral foramina, 55
  - sacro-iliac ligament, 55
  - shoulder dislocation, 79
  - spinal artery, 135, 161
  - superior dental nerve, 129
  - superior iliac spine, 55, 119
  - thorax, 27
  - tibial artery, 95
    - venae comitantes, 97, 113
  - triangle of neck, 136–7
  - trunk, branches, 57
  - tubercle, 159
  - wrist, 91
- aorta, 9, 53
- aortic
  - arch, 13, 135, 141
  - valve, 20, 21
- apical lymph nodes, 69
- aponeurosis, 90, 151
- appendicectomy, 43
- appendices epiploicae, 43
- appendicitis, 43
- appendix, 42, 43
  - blood supply, 32
  - epididymis, 59
  - testis, 59
- aqueous humour, 155
- arachnoid
  - mater, 152, 160
  - villi, 152, 153
- arcuate
  - branch, 49
  - ligaments, 9
- areola, 69
- areolar tissue, 151
- arm, 80–1
  - see also* forearm
- arteria pancreatica magna, 47
- arterial reconstruction, 95
- arteries, 132–5
  - abdomen, 31–3
  - abdominal wall, 29, 30
  - epigastric, 30
  - foot, 117
  - forearm, 85
  - leg, 113
  - lower limb, 94–5
  - neck, 141
  - orbit, 154
  - pelvis, 57
  - thigh, 107, 108
  - upper limb, 66–7
- articular
  - eminence, 125
  - facets, 158, 159
- aryepiglottic muscle, 139
- arytenoid cartilages, 139
- ascending aorta, 13
- atheroma, 95
- atlas, 158, 159
- atrioventricular
  - bundle, 23
  - node, 23
- attic, 157
- atypical synovial joint, 75
- auditory nerve, 131, 157
- auricular surface of the ilium, 55
- auriculotemporal nerve, 129
- auriscope, 156, 157
- auscultation, valvular, 27
- autodigestion, 47
- autonomic nervous system, 120–1
- avascular necrosis, 65, 105
- axilla, 68, 69, 75, 76–7, 90, 91
- axillary
  - artery, 67, 76, 77, 135
  - clearance, 77
  - lymph nodes, 69, 77
  - nerve, 71, 79, 91
  - tail, 69
  - vein, 67, 69, 77
- axons, 127
- azygos vein, 13, 17
- back, muscles, 74
- Bartholin's glands, 59
- base (skull), 123, 124–5
- basilar artery, 135
- basilic vein, 69, 81
- basivertebral veins, 159
- biceps, 73, 81, 83
  - brachii, 163
  - femoris, 108, 165
  - tendon, 64, 90
- bifid spines, 159
- bifurcate ligament, 117
- Bigelow's ligament, 102
- bile
  - canaliculi, 44
  - ducts, 44
- biliary
  - colic, 45
  - system, 46
  - tree, 44–5
- bladder, 53, 60–1
- blindness, 133
- blood vessels, arm, 80
- bloodless fold of Treves, 43
- body of the sphenoid, 123
- brachial
  - artery, 67, 69, 81, 90, 91
  - plexus, 6, 7, 70, 71
  - branches, 71, 73, 137
  - injuries, 71, 73
  - trunks, 141, 157
- brachialis, 71, 73, 81, 83, 163
- brachiocephalic
  - artery, 13, 135, 141
  - vein, 13, 135, 141
- brachioradialis, 71, 85, 163

- breast, 91  
 cancer, 77  
 carcinomas, 69  
 lymphatic drainage, 68–9  
 surface markings, 27  
 venous drainage, 68–9
- broad ligament, 56, 57, 61
- bronchi, 14, 15, 142
- bronchial  
 arteries, 13, 17  
 carcinomas, 15  
 veins, 17
- bronchopulmonary segments, 15, 16
- buccal nerve, 129, 131
- buccinator, 148, 167
- bulbospongiosus, 59
- bundle of His, 23
- caecum, 43
- calcaneocuboid joint, 115
- calcaneus, 114, 115, 119
- calf, 97  
 muscles, 112, 113
- Camper's fascia, 30
- canal of Schlemm, 155
- canine teeth, 147
- canthus, 150
- capsular ligaments, 82, 109, 159
- capsule (eyeball), 155
- carcinomas  
 breast, 69  
 bronchial, 15  
 larynx, 139  
 oesophagus, 11
- cardiac  
 orifice, 39  
 plexus, 25  
 tamponade, 19  
 veins, 24, 25
- cardinal ligaments, 57
- cardiomegaly, 17
- carotid  
 body, 133  
 canal, 124  
 sheath, 137, 142  
 sinus, 133  
 triangle, 137
- carpal tunnel, 65, 86–7  
 syndrome, 71, 87
- carpometacarpal joints, 87
- carrying angle, 63
- cauda equina, 160
- cave of Retzius, 61
- cavernous sinus, 127, 135, 152, 153
- cavum trigeminale, 153
- central  
 mass (sacrum), 55  
 retinal artery, 133, 155  
 tendon, 9
- centrilobular veins, 44
- cephalic vein, 69, 75
- cerebrospinal fluid, 152, 155
- cervical  
 cardiac branches, 121  
 nerve, 127, 131, 149  
 rib, 6, 7  
 spine, 159  
 sympathetic chain, 73  
 vertebrae, 137, 158, 159
- cervix, 61
- chemoreceptors, 133
- chest wall, 9, 69  
 muscles, 75
- chest X-ray (CXR), 16, 17
- cholangitis, 45
- cholelithiasis, 45
- cholesterol stones, 45
- chorda tympani, 128, 129, 131, 145, 147, 157
- choroid, 155
- ciliary  
 body, 155  
 ganglion, 127, 155  
 muscle, 121, 155  
 processes, 155
- Circle of Willis, 133
- circumflex scapular artery, 67
- cisterna chyli, 11, 35
- clavicle, 62, 91, 137
- clavipectoral fascia, 75
- clitoris, 59
- coccygeus, 55
- coccyx, 55
- cochlea, 157
- cochlear nerve, 131
- coeliac  
 ganglion, 51, 121  
 trunk, 32, 33
- colic arteries, 33
- collateral ligaments, 83, 115
- Colles' fascia, 30
- Colles' fracture, 64
- colon, 43
- common  
 carotid artery, 133, 157  
 extensor origin, 85  
 flexor origin, 85  
 iliac arteries, 57  
 interosseous artery, 67  
 palmar digital arteries, 67  
 peroneal nerve, 92, 100, 101, 111, 119
- compartment syndrome, 113
- condyloid synovial joints, 87
- cone of light, 156, 157
- conjoint tendon, 162
- conjunctiva, 150
- conjunctival  
 fornix, 150  
 haemorrhage, 150
- conoid  
 ligament, 62  
 tubercle, 62
- constrictor pupillae, 121
- coracoacromial ligament, 79
- coracobrachialis, 79, 81, 163
- coracoclavicular ligaments, 62, 75
- coracohumeral ligament, 79
- coracoid process, 91
- cornea, 155
- coronary  
 arteries, 22, 23  
 bypass grafting, 23  
 surgery, 97  
 ligament, 36, 37
- corpus  
 cavernosum, 59  
 spongiosum, 59
- cortical radial branch, 49
- costal  
 cartilages, 7  
 margin, 27, 45, 53
- costocervical trunk, 13, 135, 141
- costochondral joint, 7
- costoclavicular ligaments, 62, 75
- costophrenic angle, 17
- costotransverse joint, 7
- costovertebral joint, 7
- Cowper's glands, 59
- coxa  
 valga, 93  
 vara, 93
- cranial  
 cavity, 152–3  
 nerves, 126–7, 130–1, 144, 145  
 outflow, 121  
 root, 131
- cranium, 123
- cribriform  
 fascia, 106, 107  
 plate of ethmoid, 123
- cricoid cartilage, 139, 157
- cricothyroid  
 joint, 139  
 ligament, 139  
 muscle, 138, 139
- cricovocal membrane, 138, 139
- cruciate  
 anastomosis, 95  
 ligaments, 110, 111
- cubital fossa, 82–3
- cuboid bone, 115
- cuneiform bone, 115
- cutaneous nerves, 68, 127, 137
- CXR (chest X-ray), 16, 17
- dartos, 59
- deciduous teeth, 147
- deep  
 circumflex iliac artery, 30  
 external pudendal artery, 107  
 fascia of neck, 137  
 flexor muscles, 113  
 inguinal ring, 53, 118  
 palmar arch, 67, 91  
 palmar branch, 67  
 perineal pouch, 59  
 peroneal nerve, 101, 113  
 plantar arch, 95, 117  
 temporal arteries, 133  
 temporal nerves, 129  
 terminal branch, 73  
 transverse metacarpal ligaments, 117  
 transverse metatarsal ligaments, 117  
 veins, 69, 97  
 venous thrombosis, 97, 113
- deltoid, 71, 75, 79, 115, 163  
 injuries, 73
- deltopectoral triangle, 75, 91
- demifacets, 159
- Denonvilliers' fascia, 43, 61
- dens, 158, 159
- dentate line, 43
- dermatomes, 160, 161
- descendens  
 cervicalis, 127, 131  
 hypoglossi, 127, 131, 145
- descending thoracic aorta, 12, 13
- detrusor, 61
- diaphragm, 8, 9, 162  
 chest X-rays, 17  
 surface markings, 27
- diaphragma selli, 153
- digastric  
 muscle, 145  
 triangle, 137
- dilator pupillae, 155
- diploë, 123
- diploic veins, 123
- direct inguinal hernia, 53
- distal transverse crease, 91
- dorsal  
 carpal arch, 67  
 carpal branch, 67  
 cutaneous branch, 73  
 interosseous muscle, 88, 89, 95, 117, 167  
 lingual arteries, 133  
 metatarsal branch, 95  
 scapular artery, 13, 135, 141  
 tubercle (of Lister), 64, 91  
 venous arch, 119  
 venous network, 69, 91
- dorsalis  
 pedis artery, 95, 113  
 pedis pulse, 119
- dorsiflexor muscles, 112
- ductus deferens *see* vas deferens
- duodenal ulcer, perforated, 25
- duodenum, 39  
 blood supply, 39
- dura mater, 160  
 fibrous layer, 152  
 serous layer, 152
- dural venous sinuses, 135, 152
- DVT (deep venous thrombosis), 97, 113
- ear, 156–7
- ED (extensor digitorum), 89, 119, 164
- efferent ducts, 59
- ejaculatory ducts, 61
- elbow, 91  
 joint, 82–3
- electrocardiograms, 22
- embryonic pharynx, 142

- emissary  
  foramina, 123  
  veins, 123, 135, 151
- empyema, 15
- endometrium, 61
- endopelvic fascia, 57
- epidymis, 58, 59
- epigastric arteries, 30
- epiglottis, 139
- epitympanic recess, 157
- Erb–Duchenne paralysis, 73, 161
- ethmoid, 125
- ethmoidal  
  nerves, 129  
  sinuses, 147
- Eustachian tube, 139, 157
- expiration, mechanisms, 17
- extensor  
  carpi radialis brevis, 87, 163–4  
  carpi radialis longus, 85, 87, 163–4  
  carpi ulnaris, 164  
  digiti minimi, 164  
  digitorum, 89, 119, 164  
  digitorum brevis, 113, 166  
  digitorum longus, 113, 115, 166  
  hallucis longus, 113, 115, 119, 166  
  indicus, 164  
  muscles, 81, 112  
  pollicis brevis, 83, 164  
  pollicis longus, 83, 164
- external  
  anal sphincter, 59  
  auditory meatus, 124  
  carotid artery, 132, 133, 145, 149  
  iliac artery, 57, 95  
  intercostal muscles, 9  
  jugular vein, 135, 137, 157  
  laryngeal nerve, 131, 139  
  oblique muscles, 28, 30, 162  
  urethral meatus, 59
- extrinsic muscle (tongue), 144
- eye, 129, 148, 150  
  anterior chamber, 155  
  posterior chamber, 155
- eyeball, 154–5
- face, 123, 148–50  
  bones, 125  
  nerves, 126, 149
- facial  
  artery, 133, 145, 150, 157  
  muscles, 148  
  nerve, 121, 130, 131, 149, 157  
  vein, 135, 150
- facial expression, muscles, 148, 167
- falciform  
  ligament, 36, 37, 45  
  margin, 106
- fallopian tubes, 61
- false  
  cords, 139  
  pelvis, 55  
  ribs, 7
- falx  
  cerebelli, 153  
  cerebri, 152, 153
- fascia  
  of Denonvilliers, 43, 61  
  lata, 106
- fasciotomy, 113
- FDP (flexor digitorum profundus), 85, 87, 89, 163
- FDS (flexor digitorum superficialis), 85, 87, 89, 163
- femoral  
  artery, 94, 95, 107  
  canal, 107, 119  
  condyles, 93, 119  
  head, 93, 103  
  hernia, 118  
  neck, 93, 103  
  fractures, 105  
  nerve, 51, 98, 99, 107  
  pulse, 119  
  shaft, 93  
  sheath, 107
- triangle, 95, 106, 107  
  vein, 97, 106, 107
- femur, 92, 93, 110
- fibrocartilage, 75
- fibrous flexor sheaths, 89
- fibula, 92, 93, 114
- fibular  
  head, 93, 119  
  neck, 93  
  notch, 93
- fight or flight reaction, 121
- Filaria bancrofti*, 97
- filiform papillae, 147
- filum terminale, 160
- fingers, movements, 89
- flexor  
  carpi radialis, 87, 163  
  carpi ulnaris, 85, 87, 163  
  digiti minimi, 89, 164  
  digiti minimi brevis, 117, 167  
  digitorum accessorius, 117, 166  
  digitorum brevis, 117, 166  
  digitorum longus, 113, 115, 117, 119, 166  
  digitorum profundus, 85, 87, 89, 163  
  digitorum superficialis, 85, 87, 89, 163  
  hallucis brevis, 117, 166  
  hallucis longus, 113, 115, 117, 119, 166  
  muscles, 81, 83, 113  
  pollicis brevis, 89, 164  
  pollicis longus, 87, 89, 163  
  retinaculum, 65, 87  
  tendons, synovial sheaths, 86, 87
- foot, 112, 114–17  
  dorsum, 116, 117  
  joints, 115  
  movements, 113  
  muscles, 116, 117  
  sole, 116, 117  
  surface anatomy, 119  
  tendons, 118
- foramen  
  caecum (tongue), 143  
  epiloic, 36, 37  
  lacerum, 123, 124  
  magnum, 123, 124, 135  
  ovale, 123, 124  
  rotundum, 123  
  spinosum, 123, 124, 125, 145  
  transversarium, 159  
  of Winslow, 37
- forearm, 84–5  
  lateral cutaneous nerve, 71
- fourchette, 59
- fovea, 93, 102
- FPL (flexor pollicis longus), 87, 89, 163
- frenulum of glans penis, 59
- frontal  
  air sinuses, 123  
  bone, 123, 125  
  nerve, 129, 149  
  sinuses, 147
- fundus of uterus, 61
- fungiform papillae, 147
- gall-bladder, 44–5, 53  
  fossa, 45
- gallstones, 45, 47
- ganglia, 121
- ganglion impar, 121
- gastric arteries, 31, 33
- gastrocnemius, 113, 115, 166
- gastrosplenic ligament, 36, 37, 47
- gemellus  
  inferior, 105  
  superior, 105
- genicular  
  artery, 95  
  branches, 101
- geniculate ganglion, 131
- genioglossus muscle, 147
- geniohyoid muscle, 145
- genitofemoral nerve, 51, 107
- genu of the corpus callosum, 133
- glans penis, 59
- glaucoma, 155
- glenohumeral  
  joint, 78–9  
  ligaments, 79
- glenoid  
  cavity, 78  
  fossa, 63  
  labrum, 79
- glossopharyngeal nerve, 121, 131, 145, 146, 147
- glottis, 139
- gluteal  
  fold, 105  
  surface (ilium), 55
- gluteal region, 105  
  deep structures, 104  
  superficial muscles, 103  
  surface anatomy, 119
- gluteus  
  maximus, 105, 164  
  medius, 105, 164–5  
  minimus, 165
- gonadal arteries, 33
- gracilis, 108, 165
- great  
  saphenous vein, 97, 106, 107, 119  
  vessels, 18  
  surface markings, 27
- greater  
  auricular nerve, 127, 137  
  occipital nerve, 127  
  palatine foramen, 125  
  palatine nerves, 129  
  petrosal branch, 131  
  sciatic foramina, 55  
  sciatic notch, 55  
  trochanter, 93, 119  
  tubercle (humerus), 63  
  wings of sphenoid, 123
- groin, lymph nodes, 97
- haematuria, 49
- haemopericardium, 19
- haemorrhage, 11
- hamstrings, 105, 108
- hand, 65, 88–9, 91  
  ‘clawed’, 73  
  nerves, 72–3, 88
- hard palate, 146
- haustra, 43
- head  
  injuries, 133  
  lymphatics, 156–7  
  muscles, 167  
  surface anatomy, 156–7
- heart, 18–23  
  borders, 17  
  surface markings, 26  
  surfaces, 19
- heel, 119
- hemiazzygos vein, 13, 17
- hepatic  
  arteries, 31, 33, 45  
  veins, 45
- hernia, 52
- hip  
  bone, 54, 55  
  joint, 93, 102–5  
  surface anatomy, 119
- hook of the hamate, 91
- Horner’s syndrome, 73, 121
- humeral  
  capitulum, 63, 83  
  head, 63, 79  
  shaft, fracture, 71
- humerus, 63, 91  
  anatomical neck, 63  
  surgical neck, 63
- Hunter’s canal, 95, 107, 108
- hyaline cartilage, 79
- hydatid of Morgagni, 59
- hydronephrosis, 49
- hyoglossus muscle, 145, 147
- hyoid bone, 139, 157

- hypercalcaemia, 49
- hyperhidrosis, 25
- hypogastric plexuses, 121
- hypoglossal
  - canal, 123, 124
  - nerve, 131, 133, 145
- hypothenar muscles, 89
- ileal branches, 33
- ileoocaecal fold, 43
- ileocolic artery, 31, 33
- ileum, 40, 41
- iliac
  - crest, 55
  - fossa, 55
- iliacus, 106, 107, 165
- iliococcygeus, 55
- iliofemoral ligament, 102
- iliohypogastric nerve, 51
- ilioinguinal nerve, 51
- iliolumbar artery, 57
- iliopectineal line, 55
- iliotibial tract, 106, 108
- ilium, 55
- incisive fossa, foramina, 125
- incisors, 147
- incisura angularis, 39
- incus, 157
- indirect inguinal hernia, 53
- inferior
  - alveolar artery, 133
  - alveolar nerve, 129
  - cardiac branch, 131
  - cervical ganglion, 121, 141
  - colliculus, 127
  - concha, 125
  - constrictor, 139
  - deep cervical lymph nodes, 69, 157
  - epigastric artery, 53, 118
  - extensor retinaculum, 113
  - gluteal artery, 57, 95, 105
  - gluteal line, 55
  - gluteal nerve, 101, 105
  - hypogastric plexus, 51
  - labial branch, 133
  - mediastinum, 11
  - mesenteric artery, 32, 33
  - oblique muscle, 155
  - ophthalmic vein, 155
  - orbital fissure, 155
  - parathyroid gland, 143
  - peroneal retinaculum, 113
  - petrosal sinus, 135
  - pubic ramus, 55
  - rectal branches, 59
  - rectus muscle, 155
  - sagittal sinus, 135, 153
  - thyroid artery, 132, 141, 142
  - thyroid vein, 135, 142
  - tibiofibular joint, 93, 113
  - ulnar collateral branch, 67
  - vena cava, 9, 34, 35, 44, 45, 49
  - vesical artery, 57, 61
- infraclavicular lymph nodes, 69, 75
- infrahyoid
  - lymph nodes, 157
  - muscles, 131, 142
- infraorbital
  - foramen, 125
  - nerve, 129, 157
- infraspinal, 75, 79, 163
- infratemporal region, 145
- infratrochlear nerve, 129
- inguinal
  - canal, 29, 30, 52, 162
  - hernia, 53, 118
  - ligament, 53, 98, 107, 162
- inner ear, 157
- innermost intercostals, 9
- insect bites, 69
- inspiration, mechanisms, 17
- interarytenoid muscles, 139
- intercavernous sinuses, 135
- interchondral joint, 7
- intercondylar
  - area, 93
  - eminence, 93
  - notch, 93
- intercostal
  - artery, 161
  - nerves, 9
  - space, 8, 9
- intercostales intimi, 9
- interlobar branch, 49
- intermediate cutaneous nerve, 99
- intermittent claudication, 95
- internal
  - anal sphincter, 59
  - auditory artery, 135
  - auditory meatus, 123
  - capsule, 133
  - carotid artery, 132, 133, 145
  - carotid nerve, 121
  - carotid stenosis, 132
  - iliac artery, 57
  - intercostal muscle, 9
  - jugular vein, 13, 135, 137, 141, 145
  - laryngeal branch, 147
  - laryngeal nerve, 131, 139
  - oblique muscles, 28, 30, 162
  - puddendal artery, 57
  - thoracic artery, 13, 135, 141
  - urethral meatus, 61
- interosseous
  - borders, 64
  - membrane, 85, 92, 113
  - muscles, 88, 89, 164, 167
  - sacro-iliac ligament, 55
  - talocalcaneal ligament, 117
- interphalangeal joints, 73, 87
- interspinous ligaments, 159
- intertransverse ligaments, 159
- intertubercular sulcus, 63
- interureteric ridge, 61
- intervertebral
  - discs, 159
  - joints, 159
- intestinal tumours, 45
- intra-abdominal branches, 99
- intracranial venous sinuses, 134
- intramuscular injections, 119
- intrinsic muscles of tongue, 147
- ipsilateral anhidrosis, 73
- iridocorneal angle, 155
- iris, 155
- ischaemia, 95
- ischaemic necrosis, 67
- ischial
  - ramus, 55
  - tuberosity, 55, 119
- ischioacaverosus, 59
- ischiofemoral ligament, 102
- ischiorectal fossae, 42, 59
- ischium, 55
- IVC (inferior vena cava), 9, 34, 35, 44, 45, 49
- jejunal branches, 33
- jejunum, 40
- jugular
  - foramen, 123, 124
  - trunk, 157
- jugulo-omohyoid lymph nodes, 157
- jugulodigastric lymph nodes, 157
- kidney, 48, 49, 53
- Klumpke's paralysis, 73
- knee, 92
  - injuries, 111
  - joint, 109–11
  - nerves, 101
- labia
  - majora, 59
  - minora, 59
- labrum acetabulare, 102
- lacrimal
  - bone, 125
  - gland, 121, 129, 150
  - nerve, 129
- puncta, 150
- sac, 125, 150
- lactiferous
  - ducts, 68
  - sinus, 69
- lacunae laterales, 153
- laryngopharynx, 139
- laryngoscopy, 138, 139
- larynx, 137, 138–9
  - carcinomas, 139
  - lymph drainage, 157
- lateral
  - calcaneal branch, 95
  - circumflex femoral artery, 95, 99
  - collateral ligament, 83, 93, 110, 115, 119
  - cricoarytenoid, 139
  - cutaneous nerve, 71, 99
    - calf, 101
    - thigh, 51
  - epicondyle of humerus, 85, 91
  - femoral cutaneous nerve, 107
  - head of triceps, 63
  - intercondylar tubercles, 93
  - ligament of foot, 117
  - longitudinal arch of foot, 117
  - malleolus, 93
  - mass (sacrum), 55
  - meniscus, 111
  - pectoral nerve, 73, 75
  - plantar artery, 94, 95, 117
  - plantar nerve, 100, 101, 117
  - pterygoid muscle, 145, 167
  - pterygoid plate, 124
  - rectus muscle, 155
  - sacral artery, 57, 161
  - sulcus, 133
  - supraspinous ligaments, 85
  - thoracic artery, 67
- latissimus dorsi, 75, 79, 162
  - paralysis, 77
- left
  - atrium, 20, 21
  - common carotid artery, 13
  - coronary artery, 13
  - crus, 9
  - phrenic nerve, 25
  - recurrent laryngeal nerve, 25, 142
  - subclavian artery, 13
  - vagus nerve, 24, 25
  - ventricle, 20, 21
- leg, 112–13
- lens, 155
- lesser
  - occipital nerve, 127, 137
  - palatine foramen, 125
  - palatine nerves, 129
  - sciatic foramina, 55
  - sciatic notch, 55
  - trochanter, 93
  - tubercle (humerus), 63
  - tuberosity, 91
  - wing of sphenoid, 123
- levator
  - ani, 54, 55
  - palati, 146
  - palpebrae superioris, 155
  - prostateae, 55
  - scapulae, 75, 162
- lienorenal ligament, 36, 37, 47
- ligamenta flava, 159
- ligamentum
  - nuchae, 91
  - patellae, 93, 110, 119
  - teres, 36, 37, 45, 93, 102, 103
  - venosum, 45
- linea
  - alba, 28, 30, 53, 162
  - aspera, 93
  - semilunaris, 28, 30, 53
- lingual
  - artery, 133, 145
  - nerve, 129, 145, 147
  - tonsil, 147
  - vein, 135

- lingular segment, 17
- liver, 44–5, 53
  - cirrhosis, 11
  - hilum, 45
  - lobules, 44, 45
- lobular branch, 49
- long
  - ciliary nerves, 129
  - extensor tendons, 89
  - flexor tendons, 89
  - plantar ligament, 117
  - thoracic nerve (of Bell), 73, 77
- longitudinal arches of foot, 117
- lower
  - deep cervical lymph nodes, 157
  - gastrointestinal tract, 42–3
  - subscapular nerve, 73
  - ureter, 49
- lower limb
  - arteries, 94–5
  - leg, 112–13
  - lymphatics, 96–7
  - lymphoedema, 96, 97
  - muscles, 164–7
  - nerves, 98–101
  - osteology, 92–3
  - surface anatomy, 118–19
  - veins, 96–7
- lumbar
  - artery, 161
  - plexus, 50, 51, 99
  - puncture, 159, 160
  - spine, 159
  - sympathectomy, 51
  - sympathetic chain, 51
  - vertebrae, 158, 159
- lumbosacral angle, 55
- lumbrical muscles, 71, 89, 117, 164, 166
- lunate bone, 64
- lung, 16–17, 142
  - collapse, 15
  - hilum, 14, 15
  - surface markings, 26, 27
- lymph, 69
  - lower limb, 96
- lymph nodes, 35, 68, 69
  - head and neck, 156
  - lower limb, 97
- lymphadenopathy, 69
- lymphatics, 75
  - abdomen, 34–5
  - breast, 68
  - chest, 9, 10, 11, 68, 69
  - head, 156–7
  - lower limb, 96–7
  - neck, 156–7
  - thigh, 107
  - upper limb, 69
- lymphoedema
  - lower limb, 96, 97
  - upper limb, 69
- McBurney's point, 52, 53
- Mackenrodt's ligaments, 57
- macula lutea, 155
- malleus, 157
- mandible, 124, 125, 145
- mandibular
  - division, 129
  - foramen, 125
  - fossa, 125
  - nerve, 149
- manubriosternal joint, 7
- manubrium, 7
- marginal artery (of Drummond), 32, 33
- marginal mandibular nerve, 131
- masseter, 145, 148, 167
- mastication, muscles, 148, 167
- mastoid
  - air cells, 124, 157
  - antrum, 157
  - process, 124
- maxilla, 125
- maxillary
  - air sinus, 125
  - artery, 133, 145, 149
  - division, 129
  - nerve, 133
  - sinus, 147
- meatuses of nose, 147
- median cubital vein, 91
- medial
  - circumflex femoral branch, 95
  - collateral ligament, 83, 110, 115, 119
  - crest, 93
  - cutaneous branch, 99
  - cutaneous nerve, 73
  - epicondyle of humerus, 63, 91
  - fracture, 73
  - head of gastrocnemius, 110
  - head of triceps, 63
  - intercondylar tubercles, 93
  - ligament, 117
  - longitudinal arch of foot, 117
  - malleolus, 93, 119
  - meniscus, 111
  - pectoral nerve, 73
  - plantar artery, 94, 95, 117
  - plantar nerve, 100, 101, 117
  - pterygoid muscle, 145, 167
  - pterygoid plate, 124
  - rectus muscle, 155
- median
  - cubital vein, 69, 82
  - nerve, 70, 71, 81, 85, 88, 90, 91
  - raphe (scrotum), 59
  - umbilical ligament, 37, 60
- mediastinal
  - artery, 13
  - structures, chest X-rays, 17
- mediastinum, 10–13, 24
  - middle, 19
- Meibomian glands, 150
- membranous
  - labyrinth, 157
  - urethra, 61
- meninges, 152, 159, 160
- meningococcus, 47
- meningocoele, 159
- menisci, 111, 119
- meniscomfemoral ligaments, 111
- mental
  - foramen, 125
  - nerve, 129, 157
- meralgia paraesthetica, 99
- mesenteric artery, 32
- mesenteries, 36, 37
- mesocolons, 37
- metacarpals, 89
- metacarpophalangeal joints, 73, 87
- metatarsals, 115, 119
- metopic suture, 123
- midcarpal joint, 87
- middle
  - cerebral artery, 133
  - cervical ganglion, 121, 141
  - constrictor, 139, 145
  - cranial fossae, 123
  - ear, 130, 156, 157
  - mediastinum, 11
  - meningeal artery, 123, 133, 145, 157
  - rectal artery, 57
  - superior dental nerve, 129
  - thyroid vein, 135, 142
- midtarsal joint, 115
- milk teeth, 147
- mitral (bicuspid) valve, 20, 21
- molars, 147
- mons pubis, 59
- Montgomery's glands, 69
- mouth, 145, 146–7
- mucous membranes, 15, 139
- muscles
  - abdomen, 162
  - abdominal wall, 30
  - calf, 112, 113
  - chest wall, 75
  - eyeball, 155
  - foot, 116, 117
  - forearm, 84, 85
  - head, 167
  - leg, 113
  - lower limb, 164–7
  - neck, 167
  - nerves, 101
  - pectoral region, 74
  - scapular region, 74
  - thigh, 106
  - upper limb, 74, 75, 162–4
  - triangle, 137
- musculocutaneous nerve, 71, 81
- mylohyoid
  - muscle, 145
  - nerve, 129
- myocardial infarction, 23
- myometrium, 61
- myosis, 121
- myotomes, 161
- nasal
  - bone, 125
  - branch of facial artery, 133
  - cavity, 125, 146, 147
  - septum, 125, 147
- nasociliary nerve, 129
- nasolacrimal duct, 147, 150
- nasopalatine nerves, 125
- nasopharynx, 139
- navicular bone of foot, 115, 119
- neck, 136, 137
  - arteries, 141
  - lymphatics, 156–7
  - muscles, 167
  - nerves, 126, 141
  - root, 140–1
  - surface anatomy, 156–7
  - upper, 144–5
  - veins, 141
- nerves
  - abdomen, 50–1
  - arm, 80
  - face, 126, 149
  - foot, 117
  - forearm, 85
  - leg, 113
  - lower limb, 98–101
  - muscles, 101
  - neck, 126, 141
  - orbit, 154
  - palsies, 72
  - thigh, 107, 108
  - thorax, 24–5
  - upper limb, 70–3, 91
- nose, 146–7
- nucleus pulposus, 159
- nutrient artery, 67, 95
- oblique popliteal ligament, 110
- obturator
  - artery, 57, 103
  - externus, 108, 165
  - fascia, 54
  - foramen, 53, 99
  - internus, 105, 165
  - nerve, 101
  - membrane, 55
  - nerve, 51, 98, 99, 107
- occipital
  - artery, 133
  - bone, 123
  - condyles, 124
- occipitofrontalis muscle, 151, 167
- oculomotor nerve, 121, 126, 127, 155
- odontoid process, 159
- oedema, 113
- oesophageal
  - artery, 13
  - varices, 11
- oesophagus, 9, 10, 11, 137, 142
- carcinomas, 11

- olecranon process, 91
- olfactory nerve, 123, 127
- omenta, 36, 37, 39
- omohyoid muscle, 142
- ophthalmic
  - artery, 123, 133, 155
  - division, 129
  - veins, 135
- opponens
  - digiti minimi, 89, 164
  - pollicis, 89, 164
- optic
  - canal, 123, 154, 155
  - chiasma, 126, 127
  - disc, 155
  - nerve, 123, 127, 129
  - tract, 127
- orbicularis
  - oculi, 148, 167
  - oris, 167
- orbit, 125, 135, 154–5
- orbital muscle, 148
- oropharynx, 139
- os
  - innominatum, 54, 55
  - trigonum, 115
- osseous labyrinth, 157
- ossicles, 157
- osteoarthritis, 65
- otic ganglion, 121, 145
- outer ear, 157
- oval window, 157
- ovarian ligament, 61
- ovary, 61
- palate, 146–7
- palatine
  - bone, 125
    - horizontal plate, 125, 146
    - perpendicular plate, 125
    - process of maxilla, 125, 146
- palatoglossal arch, 146
- palatoglossus muscle, 146
- palatopharyngeal arch, 146
- palatopharyngeus muscle, 146
- palm (of hand), 89
- palmar
  - aponeurosis, 89
  - carpal arch, 67
  - carpal branch, 67
  - cutaneous branch of median nerve, 71
  - cutaneous branch of ulnar nerve, 73
  - interosseous muscle, 88
  - metacarpal arteries, 67
  - skin, cutaneous supply, 71
- palmaris longus, 90, 163
- palpebral muscle, 148
- pancreas, 46–7, 53
- pancreatic duct (of Santorini), 39
- pancreatic duct (of Wirsung), 39, 45, 47
- pancreaticoduodenal artery, 31, 33
- pancreatitis, 45, 47
- paranasal sinuses, 147
- parasympathetic
  - fibres, 126, 128
  - nervous system, 51, 120, 121, 155
  - outflow, 121
- parathyroid glands, 143
- paratonsillar vein, 147
- paratracheal lymph nodes, 157
- parietal bone, 123
- parotid
  - duct, 149, 157
  - gland, 121, 130, 149
  - tumours, 149
- pars flaccida, 157
- patella, 93, 110, 119
  - injuries, 93
- patellar retinacula, 110
- pectineus, 107, 165
- pectoral
  - muscles, 90
  - region, 74–5
- pectoralis
  - major, 75, 79, 91, 162
  - minor, 67, 75, 162–3
- pubdental canal, 59
- pelvic
  - arteries, 56
  - brim, 55
  - cavity, 55
    - contents, 60
  - fascia, 57
  - floor, 54, 55
  - outlet, 55
  - splanchnic nerves, 51, 121
  - tumours, 97
  - viscera, 60–1
- pelvis, 50, 54–7, 60, 105
  - lymphatic drainage, 35
  - sex differences, 55
- penile urethra, 61
- penis, 59
- peptic ulcer disease, 39
- percutaneous transluminal angioplasty (PTA), 95
- perforating
  - arteries, 95
  - cutaneous nerve, 101
  - veins, 97
- pericardium, 18, 19
- pericranium, 151
- perineal
  - body, 55
  - membrane, 59
- perinephric fat, 49
- perineum, 58–9
- peripheral nerve, 161
- peripheral vascular disease, 51, 95
- peritoneal cavity, 37
- peritoneum, 36–7
- permanent teeth, 147
- peroneal
  - artery, 95, 113
  - compartment, 113
  - retinacula, 113
  - tubercle, 115, 119
- peroneus
  - brevis, 113, 119, 166
  - longus, 113, 119, 166
  - tertius, 113, 166
- petrous temporal, 123
- phalanges, 115
- pharyngeal
  - branch of vagus, 131, 146
  - plexus, 146
  - tonsil, 139, 147
  - vein, 135
- pharyngotympanic tube, 139, 157
- pharynx, 137, 138–9, 143, 145, 146
- phrenic nerve, 25, 141
- pia mater, 152, 160
- piriformis muscle, 105, 165
- pisiform bone, 91
- pivot joints, 83
- plantar
  - aponeurosis, 117
  - calcaneonavicular, 117
  - interosseous, 167
  - metatarsal branch, 95
- plantaris, 113, 166
- platysma, 148, 167
- pleura, 9, 14–15
  - surface markings, 27
- pleural aspiration, 9
- pleural cavity, 15
  - surface markings, 26
- pleurisy, 15
- pneumococcus, 47
- pneumonia, 15
- pneumothorax, 15
- popliteal
  - artery, 95, 111
  - fossa, 111, 111
  - lymph nodes, 111
  - pulse, 119
  - trifurcation, 95
  - vein, 95, 97, 107, 111
- popliteus, 93, 110, 166
- porta hepatis, 45
- portal
  - system, 44
  - vein, 34, 35, 45
- posterior
  - abdominal wall, 48–9
  - cerebral artery, 133, 135
  - chest wall, 9
  - communicating artery, 133, 135
  - cranial fossa, 123
  - crico-arytenoid, 138, 139
  - cruciate ligament, 111
  - cutaneous nerve of thigh, 101, 105
  - gluteal line, 55
  - inferior cerebellar artery, 135
  - intercostal artery, 9, 13
  - intercostal spaces, 9
  - interosseous artery, 67
  - interosseous branch, 85, 91
  - interosseous nerve, 71
  - longitudinal ligaments, 159
  - mediastinum, 11
  - pillar of fauces, 146
  - rami, 127
  - sacro-iliac ligament, 55
  - spinal artery, 135, 161
  - superior dental nerve, 129
  - superior iliac spine, 55
  - tibial artery, 95, 113
    - venae comitantes, 97, 119
  - tibial pulse, 119
  - triangle, 136–7
  - trunk, branches, 57
  - tubercle, 115, 159
- postganglionic fibres, 120, 121
- pouch of Douglas, 43
- preganglionic fibres, 120, 121
- premolars, 147
- prepuce, 59
- presacral nerves, 51
- pretracheal fascia, 137, 142
- prevertebral fascia, 137
- princeps pollicis, 67
- processus vaginalis, 53
- profunda
  - brachii artery, 67, 71, 81
  - femoris artery, 95, 108
- promontory of tympanic cavity, 157
- pronation, mechanisms, 64
- pronator
  - quadratus, 83, 163
  - teres, 83, 163
- prostate, 60, 61
- prostatic
  - sinus, 61
  - urethra, 61
  - utricle, 61
- proximal
  - phalanges, 89
  - transverse crease, 91
- psoas, 106, 107
  - bursa, 103
  - major, 162, 165
- PTA (percutaneous transluminal angioplasty), 95
- pterygoid plates of the sphenoid, 125
- pterygomandibular ligament, 139
- pterygomaxillary fissure, 125
- pterygopalatine fossa, 125, 129, 133, 145
- ptosis, 73, 121
- pubic
  - arch, 55
  - crest, 55
  - tubercle, 53, 55, 118
- pubis, 55
- pubocervical ligaments, 57
- pubofemoral ligament, 102
- puboprostatic ligaments, 61
- puborectalis, 55
- pubovesical ligaments, 57, 61
- pubdental
  - canal, 59
  - nerve, 101, 105



- pulmonary  
 ligament, 15  
 plexus, 17  
 valve, 20, 21  
 pupil, 155  
 pupillary constriction, 73  
 pyloric sphincter, 38, 39  
 pyramidalis, 30  
 pyriform fossa, 139
- quadrangular space, 74, 75  
 quadratus  
 femoris, 105, 165  
 nerve, 101, 105  
 lumborum, 162  
 quadriceps femoris, 93, 107, 110, 165
- radial  
 artery, 67, 85, 91  
 collateral ligament, 87  
 head, 63, 64, 91  
 nerve, 63, 70, 71, 81, 84, 85, 91  
 tuberosity, 64  
 radialis indicis, 67  
 radiocarpal joint, 87  
 radius, 64, 91  
 Raynaud's syndrome, 25  
 recto-uterine pouch (of Douglas), 43, 61  
 rectovesical fascia, 43, 61  
 rectum, 42, 43  
 rectus  
 abdominis, 28, 30, 162  
 femoris, 105, 165  
 sheath, 28, 30, 162  
 recurrent branch  
 laryngeal nerve, 131, 139  
 median nerve, 71, 88  
 red pulp, 47  
 renal  
 arteries, 32, 33, 49  
 columns, 48  
 cortex, 49  
 fascia, 49  
 medulla, 49  
 pelvis, 49  
 veins, 49  
 respiration, mechanisms, 17  
 rete testis, 59  
 retina, 126, 127, 155  
 retinacula of hip joint, 102, 105  
 retrocalcaneal bursa, 113, 115  
 retromandibular vein, 135, 149  
 rhomboids, 162  
 major, 75  
 minor, 75  
 ribs, 6, 7, 140  
 ridge of Passavant, 146  
 right  
 atrium, 20, 21  
 common carotid, 13  
 coronary artery, 13  
 crus of diaphragm, 9, 10  
 internal jugular vein, 135  
 lymph duct, 10, 11, 135  
 lymphatic trunks, 69  
 phrenic nerve, 24, 25  
 subclavian, 13  
 transverse sinus, 135  
 vagus nerve, 24, 25  
 ventricle, 21  
 rotator cuff muscles, 63, 78, 79, 163  
 round ligament, 57  
 rugae of stomach, 39
- sacculae of labyrinth, 157  
 sacral  
 canal, 55  
 cornua, 55  
 hiatus, 55  
 outflow, 121  
 plexus, 57, 100, 101  
 promontory, 55  
 vertebrae, 159
- sacro-iliac joint, 55  
 sacrospinous ligament, 54, 55, 105  
 sacrotuberous ligament, 54, 55, 105  
 sacrum, 54, 55, 159  
 salivary glands, 145  
 saphenous  
 nerve, 99  
 opening, 106  
 sartorius, 107, 165  
 SBO (small bowel obstruction), 40, 41  
 scalene  
 muscles, 140  
 tubercle, 7  
 scalenus  
 anterior, 140, 167  
 medius, 140, 167  
 scalp, 151  
 scaphoid bone, 64, 65, 91  
 scapula, 27, 63, 91  
 scapular  
 anastomosis, 77  
 inferior angle, 91  
 region, 74–5  
 Scarpa's fascia, 30  
 Schmorl's node, 159  
 sciatic  
 foramina, 105  
 nerve, 100, 101, 105, 107, 118  
 damage, 119  
 sclera, 155  
 scrotum, 53, 59  
 segmental  
 arteries, 49  
 bronchus, 16  
 sella turcica, 123  
 semicircular  
 canals, 157  
 ducts, 157  
 semilunar cartilages, 111  
 semimembranosus, 108, 166  
 bursa, 110  
 seminal vesicles, 61  
 seminiferous tubules, 59  
 semitendinosus, 108, 165–6  
 sensory  
 fibres, 145  
 nerves, 126  
 serous dura, 152  
 serratus anterior, 75, 79, 162  
 paralysis, 77  
 sex hormones, 61  
 short plantar ligament, 117  
 shoulder, 78–9  
 dislocations, 71, 78, 79  
 sigmoid  
 branches, 32, 33  
 sinus, 135  
 sinu-atrial (SA) node, 22, 23  
 sinus  
 of larynx, 139  
 venous sclerae, 155  
 skin  
 abdominal wall, 30  
 hand, 89  
 skull, 122–5  
 small  
 bowel obstruction, 40, 41  
 intestine, 41  
 mesentery of, 36, 37  
 saphenous vein, 97, 119  
 soft palate, 146  
 soleal  
 line, 93  
 plexus, 97  
 soleus, 113, 115, 166  
 spermatic cord, 29, 30, 53  
 spermatogenesis, 59  
 sphenoid-ethmoidal recess, 147  
 sphenoid, 124  
 sphenoidal  
 air sinus, 123, 135, 147  
 sphenopalatine  
 ganglion, 121, 129  
 nerve, 129
- sphincter  
 of Oddi, 39  
 pupillae, 155  
 urethrae, 61  
 vaginae, 55  
 vesicae, 61  
 spina bifida, 159  
 spinal  
 arteries, 161  
 cord, 159, 160–1  
 nerves, 121, 126–7, 161  
 root, 131  
 spine, 158–9  
 of scapula, 91  
 splanchnic nerves, 24, 25  
 spleen, 46–7, 53  
 splenectomy, 47  
 splenic  
 artery, 31, 33  
 lymphoid follicles, 47  
 pedicles, 47  
 spring ligament, 117  
 squamous carcinomas, oesophagus, 11  
 squamous temporal, 123  
 stapes, 157  
 stellate ganglion, 121, 141  
 stent insertion, 95  
 sternal angle, 27  
 sternbrae, 7  
 sternoclavicular  
 joint, 62, 74, 75  
 ligaments, 62  
 sternocleidomastoid, 167  
 sternocostal joint, 7  
 sternohyoid muscle, 142  
 sternomastoid, 137, 157  
 sternothyroid, 142  
 sternum, 7  
 steroid hormones, 49  
 stomach, 38, 39  
 lymphatic drainage, 35  
 straight sinus, 135  
 strap muscles, 131, 142  
 striate arteries, 133  
 styloglossus muscle, 147  
 stylohyoid ligament, 139  
 styloid process, 91, 93  
 stylomastoid foramen, 124  
 subacromial bursa, 79  
 subarachnoid space, 152, 155, 160  
 subclavian  
 artery, 7, 13, 91, 134, 135, 140, 141, 157  
 vein, 13, 135, 141  
 subcostal  
 artery, 13  
 muscle, 9  
 nerve, 51  
 plane, 53  
 subdural haemorrhage, 133  
 sublingual  
 gland, 121, 145  
 papilla, 145  
 submandibular  
 duct, 145  
 ganglion, 121, 145  
 gland, 121, 145  
 lymph nodes, 157  
 region, 144–5  
 submental lymph nodes, 157  
 subsartorial canal, 95, 107, 108  
 subsartorial plexus, 108  
 subscapular  
 artery, 67  
 bursa, 79  
 subscapularis, 75, 79, 163  
 subtalar joint, 115  
 sulcus terminalis, 147  
 superficial  
 cervical artery, 135  
 cervical ganglion, 155  
 circumflex iliac artery, 107  
 epigastric artery, 107  
 external pudendal artery, 107  
 inguinal lymph nodes, 119

- inguinal ring, 53, 162
- palmar arch, 67, 91
- palmar branch (radial artery), 67
- perineal pouch, 59
- peroneal nerve, 101, 113
- radial nerve, 71, 85
- temporal artery, 133, 149, 157
- transverse perineal muscles, 59
- superior
  - angle of scapula, 91
  - cardiac branch, 131
  - cerebellar artery, 135
  - cervical ganglion, 121
  - constrictor muscle, 139, 145, 146
  - extensor retinaculum, 113
  - flexor muscles, 113
  - gluteal artery, 57, 95, 105
  - gluteal nerve, 101, 105
  - hypogastric plexus, 51
  - labial branch, 133
  - laryngeal nerve, 131
  - mediastinum, 11
  - mesenteric artery, 31, 33
  - oblique muscle, 155
  - ophthalmic vein, 155
  - orbital fissure, 123, 127, 129, 154, 155
  - parathyroid gland, 143
  - peroneal retinaculum, 113
  - petrosal sinus, 135
  - radio-ulnar joint, 82, 83
  - rectal artery, 32, 33
  - rectus muscle, 155
  - sagittal sinus, 135, 152, 153
  - thoracic artery, 135
  - thyroid artery, 133, 142
  - thyroid vein, 135, 142
  - tibiofibular joint, 93, 113
  - ulnar collateral branch, 67
  - vena cava, 13
  - vesical artery, 57
- supination, mechanism, 64
- supinator, 83, 164
- supraclavicular nerves, 127, 137
- supracondylar lines, 93
- suprahyoid muscles, 145
- supraorbital
  - foramen, 125
  - nerve, 129, 157
- suprapatellar bursa, 110
- suprarenal
  - glands, 49
  - medulla, 121
- suprascapular
  - artery, 135
  - nerve, 73
  - vein, 135
- supraspinatus, 75, 79, 163
- supraspinous ligaments, 159
- suprasternal notch, 27
- supratrochlear
  - lymph nodes, 69
  - nerve, 129
- supravaginal cervix, 61
- sural
  - artery, 95
  - communicating branch, 101
  - nerve, 101
- suspensory ligaments
  - of axilla, 69, 75
  - of eye, 155
  - of Treitz, 39
- sustentaculum tali, 115, 119
- sutures, 123
- sympathectomy, upper limb, 25
- sympathetic
  - nervous system, 50, 51, 120, 121, 155
  - outflow, 121
  - trunk, 121, 141
- symphysis pubis, 53, 55
- synapses, 121
- synovial
  - ball and socket joints, 79, 102
  - flexor sheaths, 89
  - hinge joints, 83, 115, 145
    - modified, 110
  - membrane, 79, 110
- synovium, 103
- synthetic grafts, 95
- talocalcaneal
  - joint, 115
  - ligament, 117
- talocalcaneonavicular joint, 115
- talus, 114, 115, 119
- tarsal
  - bones, 115
  - glands, 150
  - joints, 115
  - plates, 150
- taste fibres, 145
- teeth, 147
- tegmen tympani, 157
- temporal
  - bone, 123, 124
  - tympanic plate, 124
  - nerve, 131
- temporalis, 145, 148, 167
- temporomandibular joint, 144, 145
- tendo calcaneus, 113, 115, 119
- tendons, wrist, 90
- teniae coli, 42, 43
- tensor
  - fasciae latae, 105, 165
  - palati muscle, 146
- tentorium cerebelli, 152, 153
- teres
  - major, 75, 79, 163
    - inferior border, 67
  - minor, 71, 75, 79, 163
- testicular artery, 59
- testis, 58, 59
  - lymphatic drainage, 35
- thenar muscles, 88, 89
- thigh, 106–8
- thoracic
  - aorta, 12, 13
  - cage, 6, 7
  - duct, 10, 11, 69, 135, 140, 141, 142
  - inlet, 6, 7
  - outlet, 6, 140
    - syndrome, 140
  - spine, 159
  - sympathetic trunk, 25
  - vertebrae, 158, 159
  - wall, 6–9
- thoracoacromial artery, 67, 75
- thoracodorsal nerve, 73
- injuries, 77
- thorax
  - lines of orientation, 27
  - nerves, 24–5
  - surface anatomy, 26–7
  - vessels, 12–13
- thumb, movements, 89
- thymus gland, 11
  - development, 143
- thyroarytenoid muscle, 139
- thyrocervical trunk, 13, 135, 141
- thyroglossal
  - cysts, 143, 157
  - duct, 143, 147
- thyrohyoid
  - ligament, 139
  - muscle, 142
- thyroid
  - cartilage, 139, 157
  - gland, 142–3, 157
- thyroidea ima artery, 13
- tibia, 92, 93, 110, 114, 119
- tibial
  - condyles, 93, 119
  - nerve, 95, 100, 101, 111, 113, 119
  - plateau, 93
  - tuberosity, 93, 119
- tibialis
  - anterior, 113, 115, 119, 166
  - posterior, 113, 115, 119, 166
- toes, 95
- tongue, 143, 144, 146
  - lymph drainage, 157
- tonsil, 147
- tonsillar
  - branch of facial artery, 133, 147
  - fossa, 146
- tonsillectomy, 147
- trachea, 14, 15, 137, 142, 157
  - surface markings, 27
- tracheo-oesophageal fistula, 142
- transpyloric plane (of Addison), 53
- transtuberular plane, 53
- transverse
  - acetabular ligament, 102
  - arch, 117
  - cervical nerve, 137
  - cervical vein, 135
  - ligament, 158
  - process, 159
    - anterior tubercles, 158
  - sinuses, 153
- transversus
  - abdominis, 28, 30, 162
  - thoracis, 9
- trapezius, 75, 137, 162, 167
- trapezoid
  - ligament, 62
  - line, 62
- triangular
  - ligaments, 36, 37
  - space, 74, 75
- triceps, 71, 81, 83, 163
- tricuspid valves, 20, 21
- trigeminal
  - ganglion, 129
  - nerve, 128–9, 149
    - mandibular division, 145
- trigone, 61
- trochanteric
  - anastomosis, 95
  - crest, 93, 102
  - line, 93, 102
- trochlea, 63
- trochlear
  - nerve, 126, 127, 155
  - notch of ulna, 63
- true
  - pelvis, 55
  - ribs, 7
- trunks, 35
- tumours
  - intestinal, 45
  - oesophagus, 11
  - parotid gland, 149
  - vocal cords, 139
- tunica
  - albuginea, 59, 61
  - vaginalis, 59
- tympanic membrane, 156, 157
- ulna, 64, 91
  - olecranon process, 91
- ulnar
  - artery, 67, 85, 91
  - collateral ligament, 87
  - head, 64
  - nerve, 63, 72, 73, 81, 88, 91
- umbilical artery, 57
- uncinate process, 47
- upper
  - deep cervical lymph nodes, 157
  - gastrointestinal tract, 38–41
  - subscapular nerve, 73
  - ureter, 49
- upper limb
  - arm, 80–1
  - arteries, 66–7
  - bones, 91
  - joints, 91
  - lymphatic drainage, 68–9
  - lymphoedema, 69
  - muscles, 74, 75, 162–4
  - nerves, 70–3, 91

- upper limb (*cont.*)
  - osteology, 62–5
  - soft tissues, 91
  - surface anatomy, 90–1
  - venous drainage, 68–9
  - vessels, 91
- urachus, 60
- ureter, 49, 60
- ureteric
  - colic, 49
  - stones, 49
- urethra, 59, 61
- urethral
  - crest, 61
  - sphincter, 59
- urogenital region, 59
- uterine artery, 57, 60
- utero-sacral ligaments, 57
- uterus, 56, 60, 61
- utricle, 157
  
- vagina, 59, 60, 61
- vaginal
  - artery, 57, 59
  - branch of uterine artery, 59
  - cervix, 61
  - fornices, 59
  
- vagus nerve, 121, 130, 131, 141, 145
- vallate papilla, 147
- valves of Houston, 43
- varicose veins, 97
  - high saphenous ligation, 96
- vas (ductus) deferens, 57, 61
- vastus medialis, 108, 165
- vault (skull), 123
- veins, 134–5
  - abdomen, 34–5
  - abdominal wall, 29, 30
  - neck, 141
  - pelvis, 57
- venous
  - plexus, 113
  - sinuses, 134, 135, 152
- vertebrae, 91, 158
- vertebral
  - arteries, 13, 132, 135, 141, 161
  - bodies, 159
  - canal, 159
  - vein, 135
- verumontanum, 61
- vestibular
  - folds, 139
  - nerve, 131
- vestibule, 59, 157
  
- vestibulocochlear nerve, 131, 157
- vitreous humour, 155
- vocal
  - cords, 138, 139
  - tumours, 139
  - ligaments, 138, 139
- Volkman's ischaemic contracture, 67
- vomer, 125
- vulva, 59
  
- weakened arm abduction, 77
- Wharton's duct, 145
- white pulp, 47
- white rami communicantes, 121
- wrist, 91
  - injuries, 64
  - joints, 86–7
  - nerves, 71
  - tendons, 90
  
- xiphisternal joint, 7, 27
- xiphoid, 7
  - process, 53
  
- zona orbicularis, 102
- zygomatic
  - bone, 125
  - nerve, 131, 149